

Late complication of intramural coronary transfer at arterial switch operation

Stoll, Victoria; Hudsmith, LE; Drury, Nigel; Barron, David

DOI:

[10.1093/icvts/ivy289](https://doi.org/10.1093/icvts/ivy289)

License:

None: All rights reserved

Document Version

Peer reviewed version

Citation for published version (Harvard):

Stoll, V, Hudsmith, LE, Drury, N & Barron, D 2018, 'Late complication of intramural coronary transfer at arterial switch operation', *Interactive CardioVascular and Thoracic Surgery*. <https://doi.org/10.1093/icvts/ivy289>

[Link to publication on Research at Birmingham portal](#)

Publisher Rights Statement:

Checked for eligibility 09/10/2018

This is a pre-copyedited, author-produced version of an article accepted for publication in *Interactive Cardiovascular and Thoracic Surgery* following peer review. The version of record Stoll VM, Hudsmith LE, Drury NE, Barron DJ. Late complication of intramural coronary transfer during the arterial switch operation. *Interact CardioVasc Thorac Surg* 2018 is available online at: <https://academic.oup.com/icvts/advance-article/doi/10.1093/icvts/ivy289/5149801>

General rights

Unless a licence is specified above, all rights (including copyright and moral rights) in this document are retained by the authors and/or the copyright holders. The express permission of the copyright holder must be obtained for any use of this material other than for purposes permitted by law.

- Users may freely distribute the URL that is used to identify this publication.
- Users may download and/or print one copy of the publication from the University of Birmingham research portal for the purpose of private study or non-commercial research.
- User may use extracts from the document in line with the concept of 'fair dealing' under the Copyright, Designs and Patents Act 1988 (?)
- Users may not further distribute the material nor use it for the purposes of commercial gain.

Where a licence is displayed above, please note the terms and conditions of the licence govern your use of this document.

When citing, please reference the published version.

Take down policy

While the University of Birmingham exercises care and attention in making items available there are rare occasions when an item has been uploaded in error or has been deemed to be commercially or otherwise sensitive.

If you believe that this is the case for this document, please contact UBIRA@lists.bham.ac.uk providing details and we will remove access to the work immediately and investigate.

Late complication of intramural coronary transfer at arterial switch operation

Victoria M. Stoll ^{1,2}

Lucy E. Hudsmith ²

Nigel E. Drury ^{1,3}

David J. Barron ³

¹ Institute of Cardiovascular Sciences, University of Birmingham

² Department of Adult Congenital Cardiology, Queen Elizabeth Hospital Birmingham

³ Department of Paediatric Cardiac Surgery, Birmingham Children's Hospital, Birmingham, UK

Correspondence: Mr. David Barron, Department of Paediatric Cardiac Surgery, Birmingham Children's Hospital, Steelhouse Lane, Birmingham, B4 6NH, UK

tel: +44 121 333 9435, fax: +44 121 333 9441, email: david.barron1@nhs.net

Word Count: 1031

Abstract

Intra-mural coronary arteries remain a major risk factor and technical challenge of the arterial switch operation for transposition of the great arteries. We report a 27-year old woman presenting with an acute coronary syndrome late after arterial switch with a complex coronary pattern (intramural left and right coronary from sinus two). CT demonstrated that the pericardial 'saddle bag' used to reconstruct the intramural coronary was compressed between the neo-aortic root and neo-pulmonary trunk. At surgery, the coronary system was laid open into the neo-aorta with patch enlargement and the patient made an uneventful recovery.

Keywords

Transposition of the great arteries, arterial switch, acute coronary syndrome

Introduction

The arterial switch operation has been the procedure of choice for transposition of the great arteries for the past 30 years. Transfer of unusual coronary anatomy remains the key technical challenge and is associated with worse early and late outcomes [1,2]. We report the case of a young woman presenting with an acute coronary syndrome following previous arterial switch with a complex coronary pattern.

Case report

A 27-year old woman presented with chest pain whilst taking her driving test. Ambulance electrocardiograms showed ST elevation in aVR with widespread ST depression and she was admitted to hospital as an acute coronary syndrome. She had originally presented at two weeks of age with cyanosis and was diagnosed with transposition with intact ventricular septum. After initial palliation with atrial septostomy and pulmonary artery banding to retrain the left ventricle, she underwent arterial switch at 8 months old. During repair, she was found to have an unusual coronary pattern with both coronary arteries arising from the right posterior sinus (sinus two), the right in the mid-portion and the left from adjacent to the commissure, with an intramural course anteriorly (figure 1a/b). The coronary arteries were therefore transferred as a single button and implanted using a 'saddle bag' technique with bovine pericardium for both the coronary repair and pulmonary artery defect.

She had remained well, with two successful pregnancies at one and four years prior to her acute presentation. An urgent CT (figure 1c) demonstrated that the pericardial saddle bag connected to the coronaries was compressed between a dilated neo-aortic root and the neo-pulmonary trunk. In view of ongoing chest pain and external compression of her coronary system, emergency surgery was performed. The bovine pericardial patches were found to be calcified and fused, compressing the saddle bag and compromising flow to the left main stem. All bovine material was removed (figure 2a) allowing the left main stem to be laid

open. A matching incision was made into the adjacent aortic wall and the left main stem was directly anastomosed (figure 2b), with defect re-roofing using pericardium (figure 2c). She made an uneventful recovery.

Discussion

Coronary artery transfer remains the major technical challenge during the arterial switch operation. Unusual coronary patterns occur in 30-35% of cases and have been associated with increased risk of early mortality [1]. Intramural coronary arteries, a single coronary ostium and a coronary sinus with more than one ostium have been identified as risk factors for perioperative death and early reintervention for myocardial ischaemia [1].

Late coronary obstructive lesions may occur due to ostial fibrosis at the button suture line, fibrocellular intimal thickening or mechanical kinking/stretching during somatic growth [2]. Late coronary complications requiring re-intervention have been reported to occur in <3% of patients [2], although a recent European multicentre study with a median follow-up of 16 years, found a reoperation rate of only 0.3% for late coronary complications [3]. However asymptomatic coronary lesions may be found in up to 8% of patients [2] and previously silent ischaemia may present as a late cardiac event or sudden death [4].

In approximately 1% of patients with transposition, the left and right coronary arteries arise from separate ostia in sinus 2 with the left coronary artery passing anteriorly, often intramurally, between the great vessels [1]. At arterial switch, whilst separate implantation of the coronaries is preferable, the coronary ostia may be deemed inseparable and transferred as a single button, such that the left main stem remains between the neo-aorta and neo-pulmonary trunk. This predisposes to late ischaemia by mechanical compression, which may be exacerbated by dilatation of the neo-aortic root, a common late sequela of arterial switch [4]; we therefore would now routinely lay open the intramural course at the time of arterial switch to reduce the risk of late obstruction.

It is therefore recommended that following arterial switch, patients with unusual coronary patterns, especially intramural or passing between the great vessels, remain under lifelong surveillance with functional and morphological assessments to pre-empt life-threatening myocardial ischaemia [5].

Acknowledgements: We thank Evelyn Lindsay in Clinical Photography & Design Services at Birmingham Children's Hospital for the illustrations.

Conflict of interest: None

References

1. Pasquali SK, Hasselblad V, Li JS, Kong DF, Sanders SP. Coronary artery pattern and outcome of arterial switch operation for transposition of the great arteries: a meta-analysis. *Circulation* 2002;106:2575-80.
2. Vargo P, Mavroudis C, Stewart RD, Backer CL. Late complications following the arterial switch operation. *World J Pediatr Congenit Heart Surg* 2011;2:37-42.
3. Vida VL, Zanotto L, Zanotto L, Stellin G. Left-Sided reoperations after arterial switch operation: a European multicenter study. *Ann Thorac Surg* 2017;104:899-906.
4. Khairy P, Clair M, Fernandes SM, Blume ED, Powell AJ, Newburger JW et al. Cardiovascular outcomes after the arterial switch operation for D-transposition of the great arteries. *Circulation* 2013;127:331-9.
5. Sarris GE, Balmer C, Bonou P, Comas JV, da Cruz E, Di Chiara L et al. Clinical guidelines for the management of patients with transposition of the great arteries with intact ventricular septum. *Cardiol Young* 2017;27:530-69.

Figures

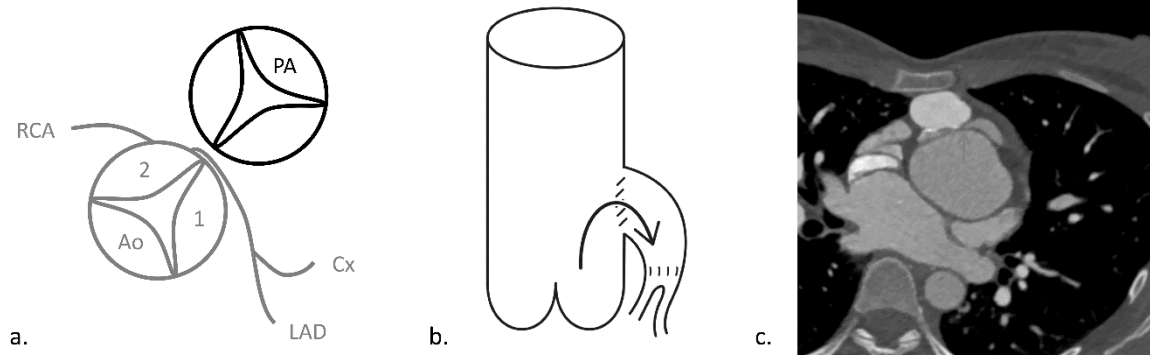


Figure 1. Coronary artery arrangement a) before and b) after arterial switch, using a pericardial 'saddle bag' to attach the single coronary button to the neo-aorta, c) CT showing left main stem compression (arrowed) between neo-aorta and neo-pulmonary trunk.

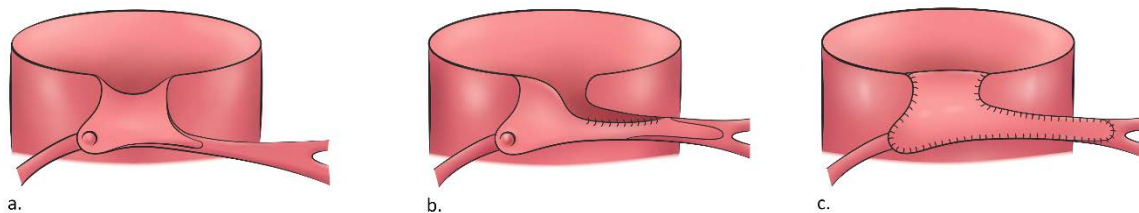


Figure 2. Operative illustrations showing a) previous saddle bag repair with bovine pericardial material removed, b) left main stem anastomosed directly into the aorta, and c) the defect re-roofed.