

## Adjunctive treatment in juvenile nasopharyngeal angiofibroma

Scholfield, Daniel W; Brundler, Marie-Anne; McDermott, Ann-Louise; Mussai, Francis; Kearns, Pamela

DOI:

[10.1097/MPH.0000000000000524](https://doi.org/10.1097/MPH.0000000000000524)

License:

None: All rights reserved

*Document Version*

Peer reviewed version

*Citation for published version (Harvard):*

Scholfield, DW, Brundler, M-A, McDermott, A-L, Mussai, F & Kearns, P 2016, 'Adjunctive treatment in juvenile nasopharyngeal angiofibroma: How should we approach recurrence?', *Journal of pediatric hematology/oncology*, vol. 38, no. 3, pp. 235-239. <https://doi.org/10.1097/MPH.0000000000000524>

[Link to publication on Research at Birmingham portal](#)

**Publisher Rights Statement:**

Final Version of Record published as detailed above.

Checked June 2016

**General rights**

Unless a licence is specified above, all rights (including copyright and moral rights) in this document are retained by the authors and/or the copyright holders. The express permission of the copyright holder must be obtained for any use of this material other than for purposes permitted by law.

- Users may freely distribute the URL that is used to identify this publication.
- Users may download and/or print one copy of the publication from the University of Birmingham research portal for the purpose of private study or non-commercial research.
- User may use extracts from the document in line with the concept of 'fair dealing' under the Copyright, Designs and Patents Act 1988 (?)
- Users may not further distribute the material nor use it for the purposes of commercial gain.

Where a licence is displayed above, please note the terms and conditions of the licence govern your use of this document.

When citing, please reference the published version.

**Take down policy**

While the University of Birmingham exercises care and attention in making items available there are rare occasions when an item has been uploaded in error or has been deemed to be commercially or otherwise sensitive.

If you believe that this is the case for this document, please contact [UBIRA@lists.bham.ac.uk](mailto:UBIRA@lists.bham.ac.uk) providing details and we will remove access to the work immediately and investigate.

## Adjunctive Treatment In Juvenile Nasopharyngeal Angiofibroma: How Should We Approach Recurrence?

Daniel W Scholfield BSc (Hons) MBChB<sup>1</sup>, Marie-Anne Brundler MD FRCPATH<sup>2</sup>, Ann-Louise McDermott  
FDS RCS FRCS<sup>3</sup>, Francis Mussai MA (Oxon) BM BCh DPhil MRCPCH<sup>1,4</sup>, Pamela Kearns MBChB BSc  
(Hons) PhD FRCPCH<sup>1,4</sup>

<sup>1</sup>Paediatric Oncology Department, Birmingham Children's Hospital

<sup>2</sup>Department of Pathology, Birmingham Children's Hospital, Birmingham UK

<sup>3</sup>ENT Department, Birmingham Children's Hospital, Birmingham UK

<sup>4</sup>School of Cancer Sciences, University of Birmingham, UK

### Disclosures:

The authors have no conflicts of interest or funding to disclose.

### Correspondence:

Daniel Scholfield

Whipps Cross Hospital

London, UK

E11 1NR

Email: danwscholfield@doctors.org.uk

Telephone: +44(0) 7817 262259

### Key words:

Juvenile Nasopharyngeal Angiofibroma

Radiotherapy

Flutamide

Dexamethasone

## Abstract

1  
2 A recent case of advanced, recurrent Juvenile Nasopharyngeal Angiofibroma (JNA) at our institution  
3  
4 has highlighted the limited evidence regarding adjunctive treatment. We present the case of a ten  
5  
6 year old boy who is the first to undergo multiple staged surgical resections alongside vincristine  
7  
8 treatment. We performed a review of the literature analyzing the roles of radiation therapy,  
9  
10 cytotoxic drugs and novel targeted agents in JNA relapse. Small cohort studies suggest radiotherapy  
11  
12 and flutamide are the most rational treatment options for residual and recurrent JNA. Our review  
13  
14 highlights the need for further research into the management of primary and recurrent JNA.  
15  
16  
17  
18  
19  
20  
21  
22

## Introduction

23  
24  
25  
26 Juvenile nasopharyngeal angiofibroma (JNA) is a benign, highly vascular and locally invasive lesion  
27  
28 that develops almost exclusively in the nasopharynx of peripubertal boys. JNA represents 0.5% of all  
29  
30 head and neck tumors, with an incidence of approximately 1:150,000. Large cohort studies report  
31  
32 median ages of 15 years (range 10-24 years) and 18.5 years (range 18-35 years) (1).  
33  
34  
35  
36  
37  
38  
39

40 Histologically JNA is pseudocapsulated, characterized by an irregular vascular component embedded  
41  
42 in a fibrous stroma, densely populated by collagen and fibroblasts. Mitotic figures are rare and the  
43  
44 vessels are organized in clusters, without elastic fibers in their walls or a muscular lining in smaller  
45  
46 vessels (2). Electron microscopy and immunohistological studies demonstrating morphological  
47  
48 irregularities such as focal lack of pericytes, discontinuous vascular basal laminae and irregularity of  
49  
50 smooth muscle layers, suggest that JNA is not a tumor, but a vascular malformation (3). JNA  
51  
52 originates from the first branchial arch artery and usually regresses between embryological day 22  
53  
54 and 24 to form a venous plexus in the sphenopalatine foramen, the typical site of JNA origin.  
55  
56  
57  
58  
59 Incomplete regression of the vascular plexus leaves it vulnerable to growth stimulation at the time of  
60  
61  
62  
63  
64  
65

1 adolescence to form JNA (3). Predominance in adolescent males suggests a hormonal influence on  
2 growth, supported by the presence of androgen receptors on JNA cell membranes (4). The male to  
3  
4 female ratio of patients in our review is 94:0.  
5  
6  
7  
8  
9

10 JNA is locally destructive, often extending intracranially into the paranasal sinuses and along the  
11 skull base (5). Patients present with nasal obstruction, facial numbness, headaches and visual  
12  
13 changes (6). Nasal endoscopy typically reveals a large hypervascularized, lobulated mass extending  
14  
15 into the nasopharynx and diagnosis is confirmed with computed tomography (CT), which usually  
16  
17 reveals widening of the sphenopalatine foramen and extension into surrounding areas (5). Contrast  
18  
19 enhanced magnetic resonance imaging (MRI) shows further characteristic features - "flow voids"  
20  
21 caused by the highly vascular nature of JNA. MRI is superior to CT for diagnosis and surgical planning  
22  
23 due to greater sensitivity in distinguishing JNA from retained mucous or inflammation, eliminating  
24  
25 other benign or malignant tumors and assessing intracranial extent (1).  
26  
27  
28  
29  
30  
31  
32  
33  
34  
35

36 Surgery remains the mainstay of treatment, preceded by intravascular embolization to reduce intra-  
37  
38 operative bleeding (5). Adjunctive radiotherapy and chemotherapy are uncommon, but may be the  
39  
40 only option in inoperable recurrence. A recent case at our institution has highlighted the  
41  
42 exceptionally limited evidence regarding adjunctive treatment and questions how best to approach  
43  
44 recurrence.  
45  
46  
47  
48  
49  
50  
51

## 52 **Case**

53  
54  
55 A ten year old boy presented to our institution with a two month history of deteriorating vision and  
56  
57 proptosis of his right eye. He complained of nasal obstruction and sleep disordered breathing for  
58  
59  
60  
61  
62  
63  
64  
65

1 more than a year and examination revealed a large right-sided nasal mass, paraesthesia of his right  
2 cheek, nose and teeth, a right middle ear effusion and displacement of the right tonsil. CT and MRI  
3 exhibited features consistent with Stage 4 JNA (Fisch classification, see Table I) (Figure 1). The  
4 patient underwent pre-operative embolization of the right internal maxillary artery and other  
5 significant bilateral tumor feeding vessels with Onyx (Ethylene vinyl alcohol copolymer), followed by  
6 the first stage of endoscopic transnasal resection. An extended endoscopic approach utilizing a  
7 Denker's maxilotomy was performed, although extensive blood loss limited the procedure.  
8  
9  
10  
11  
12  
13  
14  
15  
16  
17  
18  
19  
20

21 Histology of the resected specimen showed a spindle cell lesion containing numerous angulated and  
22 circular vascular spaces (Figure 2a). Cells showed relatively plump nuclei with small indistinct  
23 nucleoli and the background stroma was mainly composed of dense fibrous tissue.  
24  
25  
26

27 Immunohistochemistry revealed the cells to be strongly positive for  $\beta$ -catenin (Figure 2b) and  
28 vimentin (Figure 2c). CD31 and CD34 highlighted angulated and larger ectatic vessels.  
29  
30  
31  
32  
33  
34  
35

36 Post-operative MRI scan confirmed a substantial residual tumor encasing the right internal carotid  
37 artery (ICA), with extension between the pterygoid muscles down to the angle of the mandible. The  
38 case was discussed by pediatric oncology, radiation oncology and otolaryngology teams at a multi-  
39 disciplinary meeting, with particular focus on the problem of excessive blood loss despite  
40 embolization.  
41  
42  
43  
44  
45  
46  
47  
48  
49  
50  
51

52 No standard therapeutic approach exists for recurrent and unresectable JNA. Based on a small case  
53 series the patient was treated with 1.5mg/m<sup>2</sup> of vincristine weekly for four weeks, with the aim of  
54 assessing chemosensitivity prior to surgery.  
55  
56  
57  
58  
59  
60  
61  
62  
63  
64  
65

1  
2  
3 Restaging MRI six weeks post-operatively showed the tumor had failed to respond and had  
4  
5 increased in size to 75 x 75 x 45 mm (anteroposterior x craniocaudal x transverse long axis),  
6  
7 categorized by Response Evaluation Criteria in Solid Tumors (RECIST) as progressive disease. Further  
8  
9 endoscopic resection with embolization took place, again limited by blood loss and the risk of  
10  
11 deranged clotting from repeated transfusions. Extensive resection via an expanded endonasal  
12  
13 approach (EEA) was subsequently achieved. Four months post-surgery, MRI scans revealed a  
14  
15 residuum adjacent to the internal carotid artery. The child has since made an excellent recovery and  
16  
17 is currently under surveillance. MRI scans show no disease progression 28 months post-surgery via  
18  
19  
20  
21  
22 EEA.  
23  
24  
25  
26  
27

28  
29 This case raises the question of management options in the event of further growth. A review of  
30  
31 possible therapeutic options is outlined below and summary provided in Table II.  
32  
33  
34  
35  
36

### 37 **Discussion and Review of Adjunctive Treatment**

38  
39  
40 Biopsy is contra-indicated in JNA due to its highly vascularized nature. Accurate diagnosis and  
41  
42 differentiation from parameningeal tumors relies on MRI imaging, whilst CT provides bony land  
43  
44 marks for surgery. Characteristic signs on MRI include signal voids that represent major intra-  
45  
46 lesional vessels, “finger-like” projections of JNA extension into soft tissue and submucosal invasion  
47  
48 of the basisphenoid (1). Combining these characteristics leads to the diagnosis of JNA. There have  
49  
50 been no reports in the literature of these characteristic signs being present in other lesions.  
51  
52  
53  
54  
55  
56  
57  
58  
59  
60  
61  
62  
63  
64  
65

1 JNA is principally a surgical lesion that should initially be discussed with the otolaryngology team  
2 after recurrence. Transnasal endoscopic resections are most effective in combination with pre-  
3  
4 operative embolization. The surgical approach involves extensive exposure of the tumor, utilizing  
5  
6 resection of the posterior third of the nasal septum and the posterior wall of the maxillary sinus.  
7  
8 Accurate subperiosteal dissection and extensive drilling of any bone adhered to by JNA completes  
9  
10 the procedure (2). Endoscopic excision of smaller tumors is the gold standard for surgical resection  
11  
12 due to significantly reduced blood loss. The EEA approach utilizes the same principles in tackling  
13  
14 larger lesions that extend intracranially and into the skull base, the key advantage being that it  
15  
16 provides access to more deeply seated lesions (1).  
17  
18  
19  
20  
21  
22  
23  
24

25 Control of bleeding is the most significant intraoperative challenge, whilst skull base infiltration or  
26  
27 encasement of the ICA provide further surgical hazards that may result in inoperability. In contrast to  
28  
29 malignancies of the nasopharynx, such as rhabdomyosarcoma, a “piecemeal” resection is acceptable  
30  
31 and often preferable when approaching difficult anatomical locations (1). Endoscopic surgery is  
32  
33 contraindicated in residual tumors involving critical areas and it is in these cases where adjuvant  
34  
35 therapy needs to be discussed.  
36  
37  
38  
39  
40  
41  
42  
43

44 Radiation therapy (RT) for JNA is a contentious topic due to the potential for malignant  
45  
46 transformation to fibrosarcoma, although only two cases are reported in the literature, occurring 18  
47  
48 and 20 years after radiation (7, 8). Other long term sequelae include growth impairment,  
49  
50 encephalopathy and secondary malignancies (1, 9). Nevertheless, adjuvant radiotherapy is  
51  
52 recommended by some authors after incomplete resection (5). McAfee et al used RT to treat 22  
53  
54 adolescent males with high stage JNA, with a total dose range of 30 to 36 Gy (9). Ten were for  
55  
56 primary treatment and 12 for recurrence, resulting in local control in 90% of patients, with a median  
57  
58  
59  
60  
61  
62  
63  
64  
65

1 follow up of 12.7 years. However, late complications occurred in 32% of patients, including transient  
2 ischemic vascular stroke and basal cell carcinoma. Long term complications also occurred in a study  
3  
4 of 27 patients, where RT was used as primary treatment (30-55 Gy) for advanced JNA (10). The  
5  
6 recurrence rate was 15% at 2 to 5 years and 15% suffered complications. Nevertheless, the authors  
7  
8 concluded that the risk of surgical intervention in advanced JNA is greater than the risk of fatal RT  
9  
10 complications. The concern for damage to surrounding structures by conventional RT may be  
11  
12 overcome by intensity-modulated radiation therapy (IMRT), offering superior target coverage and  
13  
14 lower risk to surrounding tissue (6). Chakraborty et al treated 8 patients with conformal RT, including  
15  
16 7 with IMRT, with a median age of 14 years (11). At last follow up 87.5% were free of disease  
17  
18 (median: 17 months), whilst one patient died a month after radiotherapy due to massive epistaxis.  
19  
20  
21  
22  
23  
24  
25  
26

27 There are few reports on the use of cytotoxic drugs for treatment of JNA. Goepfert et al described  
28  
29 tumor remission in five patients with recurrent disease using combinations of doxorubicin,  
30  
31 vincristine, dactinomycin and cyclophosphamide, none of which had further recurrence (12). Schick  
32  
33 et al reported a patient with advanced and unresectable disease who underwent palliative  
34  
35 treatment with adriamycin and decarbazine, which led to a partial response (RECIST) (13). Limited  
36  
37 evidence and lack of randomized control trials result in chemotherapy approaches that are not  
38  
39 uniform and remain experimental in nature.  
40  
41  
42  
43  
44  
45  
46  
47

48 The growth of JNA is highly influenced by hormonal levels, due to the presence of testosterone and  
49  
50 dihydrotestosterone receptors. Hwang et al provided immunocytochemical evidence for the  
51  
52 presence of androgen receptors (AR) on 75% of JNAs using antibodies to AR (4). The non-steroidal  
53  
54 androgen antagonist, flutamide, blocks androgen receptors without the side effects of estrogen  
55  
56 analogues. Gates et al conducted a pilot study of five male patients with Fisch stage I – III lesions  
57  
58  
59  
60  
61  
62  
63  
64  
65



1 (Table I), treated pre-operatively with 500mg/day of flutamide for six weeks (14). CT showed tumor  
2 volume reduction in four patients and increase in one, resulting in a mean volume reduction of 29%.  
3  
4 Flutamide was well tolerated and serum testosterone levels were normal 2 years post operatively,  
5  
6 although it is not clear whether the patients remained in remission. Labra et al investigated the  
7  
8 effect of flutamide on seven patients with advanced intracranial disease and a mean age of 15.6  
9  
10 years (Fisch stage IV; Table I) (15). 600mg/day of flutamide was administered for three weeks pre-  
11  
12 operatively resulting in a non-statistically significant mean volume reduction of 7.2%. The larger  
13  
14 tumor size (mean 202.45 cm<sup>3</sup>), stage or shorter course may have contributed to the ineffectiveness  
15  
16 of flutamide in this study. Thakar et al performed a phase II evaluation of activity and safety of  
17  
18 flutamide (16). Their study included 20 male patients with Fisch stage II – IV JNA (Table I) with a  
19  
20 mean age of 15.7 years. A six week course of 10mg/kg/day was chosen based on Gates et al's regime  
21  
22 and tumor volume was assessed by MRI (14). Pre-pubertal patients had a mean reduction of -2.3%  
23  
24 including two patients that had significant tumor progression. Conversely, post-pubertal patients  
25  
26 had a mean volume reduction of 16.5% (p=0.04). However, volume reduction was only partially  
27  
28 attributed to serum testosterone levels ( $R^2 = 0.28$ ) and the study does not report data on event free  
29  
30 and overall survival. Three patients with tumor recurrence showed a reduction in JNA volume of 7%,  
31  
32 12% and 18%, suggesting flutamide may be a treatment option in post-excision residual or recurrent  
33  
34 intracranial and extracranial JNA. These pilot studies suggest that a six week course of flutamide  
35  
36 may have some activity in treating recurrent JNA, particularly in post-pubertal boys. Further  
37  
38 investigation into adjuvant or salvage flutamide treatment is warranted, as the current evidence on  
39  
40 flutamide efficacy is not entirely convincing.  
41  
42  
43  
44  
45  
46  
47  
48  
49  
50  
51  
52  
53

54 The vascular endothelial growth factor (VEGF) pathway plays a key role in solid tumor angiogenesis.  
55  
56 Saylam et al found that 24 of 27 JNA samples were VEGF positive, including all cases of recurrence  
57  
58 tested (17). Bevacizumab is a humanized monoclonal antibody that inhibits VEGF-A and could be a  
59  
60  
61  
62  
63  
64  
65

1 potential therapeutic option, although there are no reports of VEGF inhibitors being investigated as  
2 treatment for JNA to date.  
3

4  
5  
6  
7  
8 Schick et al found that estrogen receptor alpha mRNA is more significant in JNA cell lines than in the  
9 stroma of nasal mucosa (18). The estrogen receptor antagonist tamoxifen was also demonstrated to  
10 inhibit proliferation of cultured JNA mesenchymal cells. However, side-effects of tamoxifen limit its  
11 clinical use for this indication. Selective estrogen antagonists are being developed, but other specific  
12 molecular targets currently remain a more realistic option for experimental treatment of JNA.  
13  
14  
15  
16  
17  
18  
19  
20  
21  
22  
23

24 Wendler et al demonstrated the greater anti-proliferative effects of glucocorticoids on 30 JNA tissue  
25 samples compared to 20 nasal mucosa tissues in vitro (19). They also showed up-regulation of  
26 glucocorticoid receptors in JNA tissue compared to nasal mucosa. Glucocorticoids are reported to  
27 downregulate VEGF, reducing microvessel density and tumor volume (19). This is of particular  
28 interest in JNA because of previously described overexpression of VEGF (17), making glucocorticoids  
29 an intriguing but untested option for management of unresectable or recurrent JNA.  
30  
31  
32  
33  
34  
35  
36  
37  
38  
39  
40  
41  
42

43 The mTOR (mammalian target of rapamycin) inhibitor sirolimus (rapamycin) and its analogues may  
44 offer effective targeted treatment for JNA, due to its highly vascular nature. They are potent  
45 inhibitors of serine/threonine kinase, which control cellular growth processes. Notably they appear  
46 to have antiangiogenic activity and have led to partial response in a case series of six patients with  
47 kaposiform hemangioendotheliomas (20).  
48  
49  
50  
51  
52  
53  
54  
55  
56  
57  
58  
59  
60  
61  
62  
63  
64  
65

1 Beta blockers are used in infantile hemangiomas to reduce the expression of VEGF and it has been  
2 theorized that propranolol induces apoptosis due to involvement of  $\beta$ 1-adrenoreceptors in  
3  
4 angiogenesis (20). Both mTOR inhibitors and beta blockers are options for further research into JNA  
5  
6  
7 treatment.  
8  
9  
10

## 11 **Conclusion**

12  
13  
14  
15  
16 Managing recurrent and unresectable JNA remains a challenge. The absence of randomized control  
17  
18 trials for anti-neoplastic drugs and RT means the role of adjuvant therapy is not well established. The  
19  
20 greatest body of evidence surrounds radiation therapy or a six week course of flutamide, but both  
21  
22 are based on small cohorts. Dexamethasone is a possible therapeutic option due to its potential  
23  
24 impact on multiple pathways, but this is yet to be proven in a clinical setting. There is a biological  
25  
26 rationale for anti-angiogenic agents and trials on anti-endoglin monoclonal antibodies are on-going,  
27  
28 but VEGF-inhibitors such as bevacizumab have yet to be investigated. Should recurrence occur in the  
29  
30 patient described in this case, the evidence-base for effective treatment is limited, particularly as  
31  
32 being pre-pubertal reduces the potential benefit of flutamide. Radiotherapy is likely to remain the  
33  
34 next most rational course of therapy. It has been demonstrated to effectively reduce tumor volume  
35  
36 and is the best option for long term survival despite the potential side effects, until more targeted  
37  
38 therapeutic options are fully evaluated. JNA is a biologically rich tumor and there is a clear need for  
39  
40 clinical research to evaluate adjuvant treatments to improve the outcome for recurrent and  
41  
42 inoperable JNA.  
43  
44  
45  
46  
47  
48  
49  
50  
51  
52  
53  
54  
55  
56  
57  
58  
59  
60  
61  
62  
63  
64  
65

## Acknowledgements

The authors would like to thank Carl H. Snyderman C, Elizabeth C. Tyler-Kabara and Paul A. Gardner at the University Of Pittsburgh Medical Centre (UPMC) for their invaluable advice and surgical expertise in managing the case described.

## References

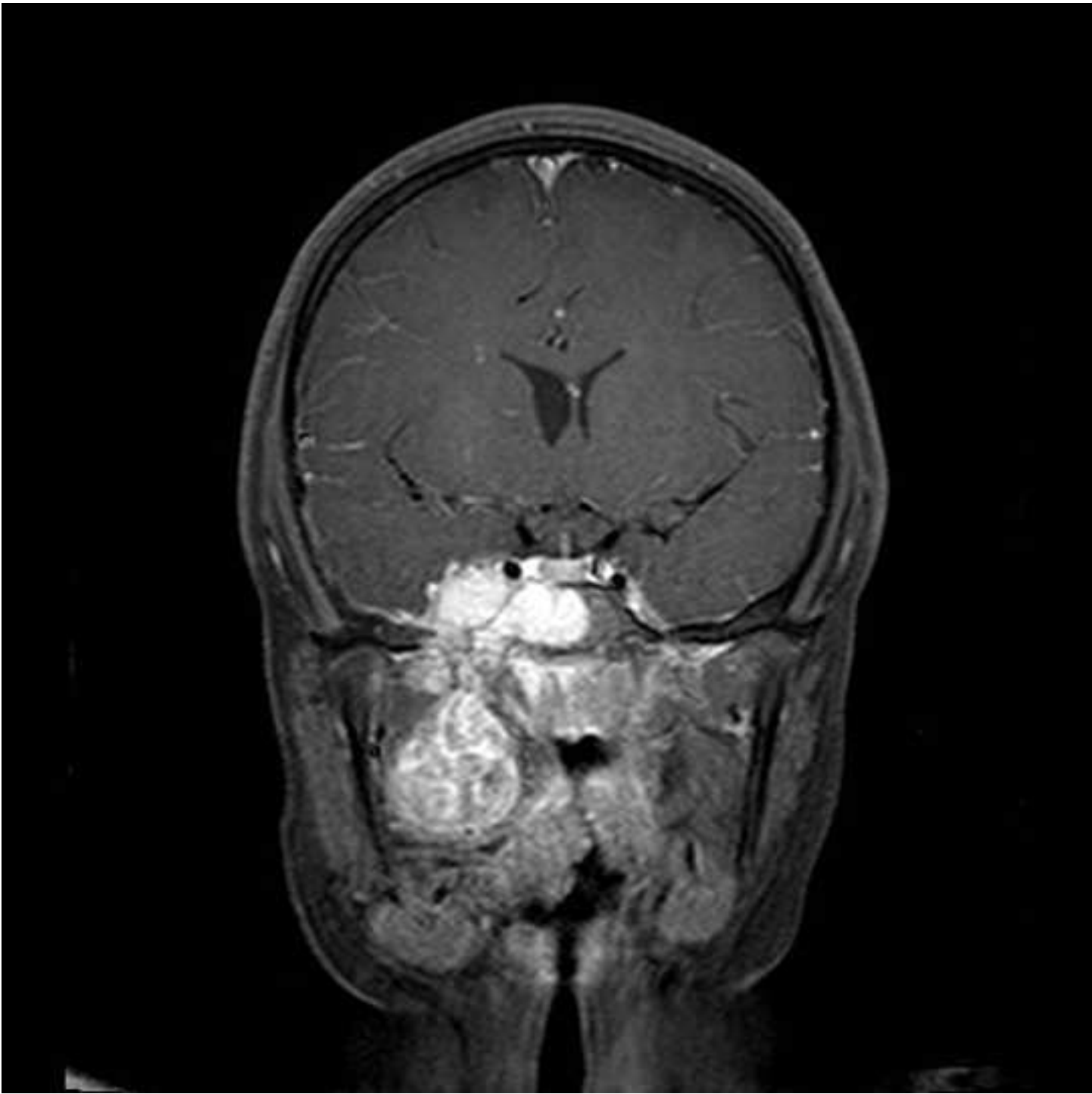
1. Lund VJ, Stammberger H, Nicolai P et al European Rhinologic Society Advisory Board on Endoscopic Techniques in the Management of Nose, Paranasal Sinus and Skull Base Tumours. European position paper on endoscopic management of tumours of the nose, paranasal sinuses and skull base. *Rhinol Suppl.* 2010 Jun 1;(22):1-143.
2. Nicolai P, Schreiber A, Bolzoni Villaret A. Juvenile angiofibroma: evolution of management. *Int J Pediatr.* 2012; 2012: 412545.
3. Schick B, Plinkert PK, Prescher A. [Aetiology of Angiofibromas: Reflection on their Specific Vascular Component]. *Laryngorhinootologie.* 2002 Apr;81(4):280-4.
4. Hwang HC, Mills SE, Patterson K, et al. Expression of androgen receptors in nasopharyngeal angiofibroma: an immunohistochemical study of 24 cases. *Mod Pathol.* 1998; 11: 1122–1126.
5. Wang JJ, Sun XC, Hu L, et al. Endoglin (CD105) expression on microvessel endothelial cells in juvenile nasopharyngeal angiofibroma: tissue microarray analysis and association with prognostic significance. *Head Neck.* 2013; 35(12): 1719-25.
6. Hodges JM, McDevitt AS, El-Sayed Ali AI, et al. Juvenile nasopharyngeal angiofibroma: current treatment modalities and future considerations. *Indian J Otolaryngol Head Neck Surg.* 2005; 62(3): 236-47.
7. Chen KT, Bauer FW. Sarcomatous transformation of nasopharyngeal angiofibroma. *Cancer.* 1982 Jan 15;49(2):369-71.
8. Makek MS, Andrews JC, Fisch U. Malignant transformation of a nasopharyngeal angiofibroma. *Laryngoscope.* 1989 Oct;99(10 Pt 1):1088-92.
9. McAfee WJ, Morris CG, Amdur RJ, et al. Definitive radiotherapy for juvenile nasopharyngeal angiofibroma. *Am J Clin Oncol.* 2006; 29(2): 168-70.
10. Lee JT, Chen P, Safa A, et al. The role of radiation in the treatment of advanced juvenile angiofibroma. *Laryngoscope.* 2002; 112: 1213-20.

- 1  
2  
3  
4  
5  
6  
7  
8  
9  
10  
11  
12  
13  
14  
15  
16  
17  
18  
19  
20  
21  
22  
23  
24  
25  
26  
27  
28  
29  
30  
31  
32  
33  
34  
35  
36  
37  
38  
39  
40  
41  
42  
43  
44  
45  
46  
47  
48  
49  
50  
51  
52  
53  
54  
55  
56  
57  
58  
59  
60  
61  
62  
63  
64  
65
11. Chakraborty S, Ghoshal S, Patil VM, et al. Conformal radiotherapy in the treatment of advanced juvenile nasopharyngeal angiofibroma with intracranial extension: an institutional experience. *Int J Radiat Oncol Biol Phys.* 2011; 80(5): 1398-404.
12. Goepfert H, Cangir A, Lee YY. Chemotherapy for aggressive juvenile nasopharyngeal angiofibroma. *Arch Otolaryngol.* 1985; 111(5): 285-9.
13. Schick B, Kahle G, Hässler R, et al. Chemotherapy of juvenile angiofibroma--an alternative? *HNO.* 1996; 44(3): 148-52.
14. Gates GA, Rice DH, Koopmann CF Jr, et al. Flutamide-induced regression of angiofibroma. *Laryngoscope.* 1992; 102(6):641-4.
15. Labra A, Chavolla-Magaña R, Lopez-Ugalde A, et al. Flutamide as a preoperative treatment in juvenile angiofibroma (JA) with intracranial invasion: report of 7 cases. *Otolaryngol Head Neck Surg.* 2004; 130(4): 466-9.
16. Thakar A, Gupta G, Bhalla AS, et al. Adjuvant therapy with flutamide for presurgical volume reduction in juvenile nasopharyngeal angiofibroma. *Head Neck.* 2011; 33(12): 1747-53.
17. Saylam G, Yücel OT, Sungur A, et al. Proliferation, angiogenesis and hormonal markers in juvenile nasopharyngeal angiofibroma. *Int J Pediatr Otorhinolaryngol.* 2006; 70(2): 227-34.
18. Schick B, Długaiczek J, Wendler O. Expression of sex hormone receptors in juvenile angiofibromas and antiproliferative effects of receptor modulators. *Head Neck.* 2014; 36(11): 1596-603
19. Wendler O, Długaiczek J, Birk S, et al. Anti-proliferative effect of glucocorticoids on mesenchymal cells in juvenile angiofibromas. *Head Neck.* 2012; 34(11): 1615-21.
20. Margolin JF, Soni HM, Pimpalwar S. Medical therapy for pediatric vascular anomalies. *Semin Plast Surg.* 2014 May;28(2):79-86.

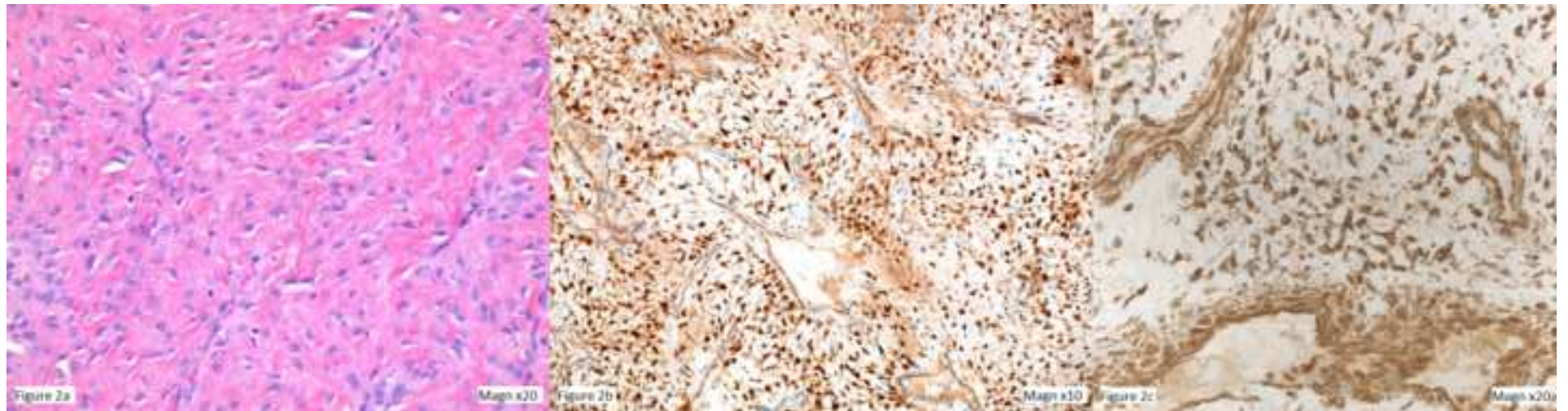
## Figures

**Figure 1:** Coronal MRI image showing an extensive JNA extending laterally into the pterygopalatine and masseter spaces and inferiorly into the infratemporal fossa. It extends into the right cavernous sinus and involves the right Meckel's cave.

**Figure 2:** Pathology micrographs of the JNA featured in the case: **2a)** Hematoxylin and eosin stain; **2b)**  $\beta$ -Catenin stain; **2c)** Vimentin stain.







**Table I: Fisch Classification of Juvenile Nasopharyngeal Angiofibroma**

<b>Stage</b>	<b>Characteristics</b>
I	Limited to the nasopharynx and nasal cavity without bone destruction.
II	Invading the pterygomaxillary fossa and the maxillary, ethmoid and sphenoid sinus with bone destruction.
III	Invading the infratemporal fossa, orbit and parasellar region remaining lateral to the cavernous sinus.
IV	Massive invasion of cavernous sinus, the optic chiasmal region or pituitary fossa.

**Table II: Summary of adjunctive treatment of JNA**

<b>Study [reference]</b>	<b>Patient number</b>	<b>Treatment</b>	<b>Outcome</b>
<b>Radiation Therapy</b>			
McAfee et al (2006) [9]	22	30 – 36 Gy	Local control in 90% of patients, late complications in 32%
Lee et al (2002) [10]	27	30-55 Gy	Recurrence in 15% of patients, complications in 15%
Chakraborty et al (2011) [11]	7	Intensity modulated radiotherapy	88% of patients disease free at 17 months. 1 death from massive epistaxis.
<b>Cytotoxic Drugs</b>			
Goepfert et al (1985) [12]	5	Doxorubicin, vincristine, dactinomycin and cyclophosphamide	0% recurrence
Schick et al (1996) [13]	1	Adriamycin and decarbazine	Partial response (RECIST criteria)
<b>Flutamide</b>			
Gates et al (1992) [14]	5	500mg/day for 6 weeks pre-operatively	Mean volume reduction: 29%
Labra et al (2004) [15]	7	600mg/dag for 3 weeks pre-operatively	Mean volume reduction: 7.2%
Thakar et al (2011) [16]	20	10mg/kg/day for 6 weeks	Mean volume reduction: -2.3% in pre-pubertal, 16.5% in post-pubertal
<b>Targeted therapies</b>			
Saylam et al (2006) [17]	N/A – in vitro	89% of JNA samples VEGF positive	
Wendler et al (2012) [19]	N/A – in vitro	Glucocorticoids	Antiproliferative effects demonstrated

## Adjunctive Treatment In Juvenile Nasopharyngeal Angiofibroma: How Should We Approach Recurrence?

Daniel W Scholfield BSc (Hons) MBChB<sup>1</sup>, Marie-Anne Brundler MD FRCPATH<sup>2</sup>, Ann-Louise McDermott  
FDS RCS FRCS<sup>3</sup>, Francis Mussai MA (Oxon) BM BCh DPhil MRCPCH<sup>1,4</sup>, Pamela Kearns MBChB BSc  
(Hons) PhD FRCPCH<sup>1,4</sup>

<sup>1</sup>Paediatric Oncology Department, Birmingham Children's Hospital

<sup>2</sup>Department of Pathology, Birmingham Children's Hospital, Birmingham UK

<sup>3</sup>ENT Department, Birmingham Children's Hospital, Birmingham UK

<sup>4</sup>School of Cancer Sciences, University of Birmingham, UK

### Disclosures:

The authors have no conflicts of interest or funding to disclose.

### Correspondence:

Daniel Scholfield

Whipps Cross Hospital

London, UK

E11 1NR

Email: danwscholfield@doctors.org.uk

Telephone: +44(0) 7817 262259

### Key words:

Juvenile Nasopharyngeal Angiofibroma

Radiotherapy

Flutamide

Dexamethasone

## Abstract

1  
2 A recent case of advanced, recurrent Juvenile Nasopharyngeal Angiofibroma (JNA) at our institution  
3  
4 has highlighted the limited evidence regarding adjunctive treatment. We present the case of a ten  
5  
6 year old boy who is the first to undergo multiple staged surgical resections alongside vincristine  
7  
8 treatment. We performed a review of the literature analyzing the roles of radiation therapy,  
9  
10 cytotoxic drugs and novel targeted agents in JNA relapse. Small cohort studies suggest radiotherapy  
11  
12 and flutamide are the most rational treatment options for residual and recurrent JNA. Our review  
13  
14 highlights the need for further research into the management of primary and recurrent JNA.  
15  
16  
17  
18  
19  
20  
21  
22

## Introduction

23  
24  
25  
26 Juvenile nasopharyngeal angiofibroma (JNA) is a benign, highly vascular and locally invasive lesion  
27  
28 that develops almost exclusively in the nasopharynx of peripubertal boys. JNA represents 0.5% of all  
29  
30 head and neck tumors, with an incidence of approximately 1:150,000. Large cohort studies report  
31  
32 median ages of 15 years (range 10-24 years) and 18.5 years (range 18-35 years) (1).  
33  
34  
35  
36  
37  
38  
39

40 Histologically JNA is pseudocapsulated, characterized by an irregular vascular component embedded  
41  
42 in a fibrous stroma, densely populated by collagen and fibroblasts. Mitotic figures are rare and the  
43  
44 vessels are organized in clusters, without elastic fibers in their walls or a muscular lining in smaller  
45  
46 vessels (2). Electron microscopy and immunohistological studies demonstrating morphological  
47  
48 irregularities such as focal lack of pericytes, discontinuous vascular basal laminae and irregularity of  
49  
50 smooth muscle layers, suggest that JNA is not a tumor, but a vascular malformation (3). JNA  
51  
52 originates from the first branchial arch artery and usually regresses between embryological day 22  
53  
54 and 24 to form a venous plexus in the sphenopalatine foramen, the typical site of JNA origin.  
55  
56  
57  
58  
59 Incomplete regression of the vascular plexus leaves it vulnerable to growth stimulation at the time of  
60  
61  
62  
63  
64  
65

1 adolescence to form JNA (3). Predominance in adolescent males suggests a hormonal influence on  
2 growth, supported by the presence of androgen receptors on JNA cell membranes (4). **The male to**  
3  
4 **female ratio of patients in our review is 94:0.**  
5  
6  
7

8  
9  
10 JNA is locally destructive, often extending intracranially into the paranasal sinuses and along the  
11 skull base (5). Patients present with nasal obstruction, facial numbness, headaches and visual  
12 changes (6). Nasal endoscopy typically reveals a large hypervascularized, lobulated mass extending  
13 into the nasopharynx and diagnosis is confirmed with computed tomography (CT), which usually  
14 reveals widening of the sphenopalatine foramen and extension into surrounding areas (5). Contrast  
15 enhanced magnetic resonance imaging (MRI) shows further characteristic features - “flow voids”  
16 caused by the highly vascular nature of JNA. MRI is superior to CT for diagnosis and surgical planning  
17 due to greater sensitivity in distinguishing JNA from retained mucous or inflammation, eliminating  
18 other benign or malignant tumors and assessing intracranial extent (1).  
19  
20  
21  
22  
23  
24  
25  
26  
27  
28  
29  
30  
31  
32  
33  
34  
35

36 Surgery remains the mainstay of treatment, preceded by intravascular embolization to reduce intra-  
37 operative bleeding (5). Adjunctive radiotherapy and chemotherapy are uncommon, but may be the  
38 only option in inoperable recurrence. A recent case at our institution has highlighted the  
39 exceptionally limited evidence regarding adjunctive treatment and questions how best to approach  
40 recurrence.  
41  
42  
43  
44  
45  
46  
47  
48  
49  
50  
51

## 52 **Case**

53  
54  
55 A ten year old boy presented to our institution with a two month history of deteriorating vision and  
56 proptosis of his right eye. He complained of nasal obstruction and sleep disordered breathing for  
57  
58  
59  
60  
61  
62  
63  
64  
65

1 more than a year and examination revealed a large right-sided nasal mass, paraesthesia of his right  
2 cheek, nose and teeth, a right middle ear effusion and displacement of the right tonsil. CT and MRI  
3 exhibited features consistent with Stage 4 JNA (Fisch classification, see Table I) (Figure 1). The  
4 patient underwent pre-operative embolization of the right internal maxillary artery and other  
5 significant bilateral tumor feeding vessels with Onyx (Ethylene vinyl alcohol copolymer), followed by  
6 the first stage of endoscopic transnasal resection. An extended endoscopic approach utilizing a  
7 Denker's maxilotomy was performed, although extensive blood loss limited the procedure.  
8  
9  
10  
11  
12  
13  
14  
15  
16  
17  
18  
19  
20

21 Histology of the resected specimen showed a spindle cell lesion containing numerous angulated and  
22 circular vascular spaces (Figure 2a). Cells showed relatively plump nuclei with small indistinct  
23 nucleoli and the background stroma was mainly composed of dense fibrous tissue.  
24  
25  
26

27 Immunohistochemistry revealed the cells to be strongly positive for  $\beta$ -catenin (Figure 2b) and  
28 vimentin (Figure 2c). CD31 and CD34 highlighted angulated and larger ectatic vessels.  
29  
30  
31  
32  
33  
34  
35

36 Post-operative MRI scan confirmed a substantial residual tumor encasing the right internal carotid  
37 artery (ICA), with extension between the pterygoid muscles down to the angle of the mandible. The  
38 case was discussed by pediatric oncology, radiation oncology and otolaryngology teams at a multi-  
39 disciplinary meeting, with particular focus on the problem of excessive blood loss despite  
40 embolization.  
41  
42  
43  
44  
45  
46  
47  
48  
49  
50  
51

52 No standard therapeutic approach exists for recurrent and unresectable JNA. Based on a small case  
53 series the patient was treated with 1.5mg/m<sup>2</sup> of vincristine weekly for four weeks, with the aim of  
54 assessing chemosensitivity prior to surgery.  
55  
56  
57  
58  
59  
60  
61  
62  
63  
64  
65

1  
2  
3 Restaging MRI six weeks post-operatively showed the tumor had failed to respond and had  
4  
5 increased in size to 75 x 75 x 45 mm (anteroposterior x craniocaudal x transverse long axis),  
6  
7 categorized by Response Evaluation Criteria in Solid Tumors (RECIST) as progressive disease. Further  
8  
9 endoscopic resection with embolization took place, again limited by blood loss and the risk of  
10  
11 deranged clotting from repeated transfusions. Extensive resection via an expanded endonasal  
12  
13 approach (EEA) was subsequently achieved. Four months post-surgery, MRI scans revealed a  
14  
15 residuum adjacent to the internal carotid artery. The child has since made an excellent recovery and  
16  
17 is currently under surveillance. MRI scans show no disease progression 28 months post-surgery via  
18  
19 EEA.  
20  
21  
22  
23  
24  
25  
26  
27

28  
29 This case raises the question of management options in the event of further growth. A review of  
30  
31 possible therapeutic options is outlined below and summary provided in Table II.  
32  
33  
34  
35  
36

### 37 **Discussion and Review of Adjunctive Treatment**

38  
39  
40 Biopsy is contra-indicated in JNA due to its highly vascularized nature. Accurate diagnosis and  
41  
42 differentiation from parameningeal tumors relies on MRI imaging, whilst CT provides bony land  
43  
44 marks for surgery. Characteristic signs on MRI include signal voids that represent major intra-  
45  
46 lesional vessels, “finger-like” projections of JNA extension into soft tissue and submucosal invasion  
47  
48 of the basisphenoid (1). Combining these characteristics leads to the diagnosis of JNA. There have  
49  
50 been no reports in the literature of these characteristic signs being present in other lesions.  
51  
52  
53  
54  
55  
56  
57  
58  
59  
60  
61  
62  
63  
64  
65



1 JNA is principally a surgical lesion that should initially be discussed with the otolaryngology team  
2 after recurrence. Transnasal endoscopic resections are most effective in combination with pre-  
3  
4 operative embolization. The surgical approach involves extensive exposure of the tumor, utilizing  
5  
6 resection of the posterior third of the nasal septum and the posterior wall of the maxillary sinus.  
7  
8 Accurate subperiosteal dissection and extensive drilling of any bone adhered to by JNA completes  
9  
10 the procedure (2). Endoscopic excision of smaller tumors is the gold standard for surgical resection  
11  
12 due to significantly reduced blood loss. The EEA approach utilizes the same principles in tackling  
13  
14 larger lesions that extend intracranially and into the skull base, the key advantage being that it  
15  
16 provides access to more deeply seated lesions (1).  
17  
18  
19  
20  
21  
22  
23  
24

25 Control of bleeding is the most significant intraoperative challenge, whilst skull base infiltration or  
26  
27 encasement of the ICA provide further surgical hazards that may result in inoperability. In contrast to  
28  
29 malignancies of the nasopharynx, such as rhabdomyosarcoma, a “piecemeal” resection is acceptable  
30  
31 and often preferable when approaching difficult anatomical locations (1). Endoscopic surgery is  
32  
33 contraindicated in residual tumors involving critical areas and it is in these cases where adjuvant  
34  
35 therapy needs to be discussed.  
36  
37  
38  
39  
40  
41  
42  
43

44 Radiation therapy (RT) for JNA is a contentious topic due to the potential for malignant  
45  
46 transformation to fibrosarcoma, although only two cases are reported in the literature, occurring 18  
47  
48 and 20 years after radiation (7, 8). Other long term sequelae include growth impairment,  
49  
50 encephalopathy and secondary malignancies (1, 9). Nevertheless, adjuvant radiotherapy is  
51  
52 recommended by some authors after incomplete resection (5). McAfee et al used RT to treat 22  
53  
54 adolescent males with high stage JNA, with a total dose range of 30 to 36 Gy (9). Ten were for  
55  
56 primary treatment and 12 for recurrence, resulting in local control in 90% of patients, with a median  
57  
58  
59  
60  
61  
62  
63  
64  
65

1 follow up of 12.7 years. However, late complications occurred in 32% of patients, including transient  
2 ischemic vascular stroke and basal cell carcinoma. Long term complications also occurred in a study  
3 of 27 patients, where RT was used as primary treatment (30-55 Gy) for advanced JNA (10). The  
4 recurrence rate was 15% at 2 to 5 years and 15% suffered complications. Nevertheless, the authors  
5 concluded that the risk of surgical intervention in advanced JNA is greater than the risk of fatal RT  
6 complications. The concern for damage to surrounding structures by conventional RT may be  
7 overcome by intensity-modulated radiation therapy (IMRT), offering superior target coverage and  
8 lower risk to surrounding tissue (6). Chakraborty et al treated 8 patients with conformal RT, including  
9 7 with IMRT, with a median age of 14 years (11). At last follow up 87.5% were free of disease  
10 (median: 17 months), whilst one patient died a month after radiotherapy due to massive epistaxis.  
11  
12  
13  
14  
15  
16  
17  
18  
19  
20  
21  
22  
23  
24  
25  
26

27 There are few reports on the use of cytotoxic drugs for treatment of JNA. Goepfert et al described  
28 tumor remission in five patients with recurrent disease using combinations of doxorubicin,  
29 vincristine, dactinomycin and cyclophosphamide, none of which had further recurrence (12). Schick  
30 et al reported a patient with advanced and unresectable disease who underwent palliative  
31 treatment with adriamycin and decarbazine, which led to a partial response (RECIST) (13). Limited  
32 evidence and lack of randomized control trials result in chemotherapy approaches that are not  
33 uniform and remain experimental in nature.  
34  
35  
36  
37  
38  
39  
40  
41  
42  
43  
44  
45  
46  
47

48 The growth of JNA is highly influenced by hormonal levels, due to the presence of testosterone and  
49 dihydrotestosterone receptors. Hwang et al provided immunocytochemical evidence for the  
50 presence of androgen receptors (AR) on 75% of JNAs using antibodies to AR (4). The non-steroidal  
51 androgen antagonist, flutamide, blocks androgen receptors without the side effects of estrogen  
52 analogues. Gates et al conducted a pilot study of five male patients with Fisch stage I – III lesions  
53  
54  
55  
56  
57  
58  
59  
60  
61  
62  
63  
64  
65

1 (Table I), treated pre-operatively with 500mg/day of flutamide for six weeks (14). CT showed tumor  
2 volume reduction in four patients and increase in one, resulting in a mean volume reduction of 29%.  
3  
4 Flutamide was well tolerated and serum testosterone levels were normal 2 years post operatively,  
5  
6 although it is not clear whether the patients remained in remission. Labra et al investigated the  
7  
8 effect of flutamide on seven patients with advanced intracranial disease and a mean age of 15.6  
9  
10 years (Fisch stage IV; Table I) (15). 600mg/day of flutamide was administered for three weeks pre-  
11  
12 operatively resulting in a non-statistically significant mean volume reduction of 7.2%. The larger  
13  
14 tumor size (mean 202.45 cm<sup>3</sup>), stage or shorter course may have contributed to the ineffectiveness  
15  
16 of flutamide in this study. Thakar et al performed a phase II evaluation of activity and safety of  
17  
18 flutamide (16). Their study included 20 male patients with Fisch stage II – IV JNA (Table I) with a  
19  
20 mean age of 15.7 years. A six week course of 10mg/kg/day was chosen based on Gates et al's regime  
21  
22 and tumor volume was assessed by MRI (14). Pre-pubertal patients had a mean reduction of -2.3%  
23  
24 including two patients that had significant tumor progression. Conversely, post-pubertal patients  
25  
26 had a mean volume reduction of 16.5% (p=0.04). However, volume reduction was only partially  
27  
28 attributed to serum testosterone levels (R<sup>2</sup> = 0.28) and the study does not report data on event free  
29  
30 and overall survival. Three patients with tumor recurrence showed a reduction in JNA volume of 7%,  
31  
32 12% and 18%, suggesting flutamide may be a treatment option in post-excision residual or recurrent  
33  
34 intracranial and extracranial JNA. These pilot studies suggest that a six week course of flutamide  
35  
36 may have some activity in treating recurrent JNA, particularly in post-pubertal boys. Further  
37  
38 investigation into adjuvant or salvage flutamide treatment is warranted, as the current evidence on  
39  
40 flutamide efficacy is not entirely convincing.  
41  
42  
43  
44  
45  
46  
47  
48  
49  
50  
51  
52  
53

54 Endoglin (CD105) is an accessory receptor for transforming growth factor beta (TGF-β). Its  
55  
56 expression is up-regulated in actively proliferating endothelial cells and it is selectively expressed on  
57  
58 vascular tumor tissue (3). Wang et al retrospectively examined endoglin expression on JNA in  
59  
60  
61  
62  
63  
64  
65

1  
2  
3  
4  
5  
6  
7  
8  
9  
10  
11  
12  
13  
14  
15  
16  
17  
18  
19  
20  
21  
22  
23  
24  
25  
26  
27  
28  
29  
30  
31  
32  
33  
34  
35  
36  
37  
38  
39  
40  
41  
42  
43  
44  
45  
46  
47  
48  
49  
50  
51  
52  
53  
54  
55  
56  
57  
58  
59  
60  
61  
62  
63  
64  
65

seventy patients, with a median age of 17 years (5). Immunohistochemistry detected its expression on vascular endothelial cells (but not stromal cells) and revealed that the CD105-based microvessel density (MVD) correlated with JNA recurrence ( $p=0.013$ ).

The vascular endothelial growth factor (VEGF) pathway plays a key role in solid tumor angiogenesis. Saylam et al found that 24 of 27 JNA samples were VEGF positive, including all cases of recurrence tested (17). Bevacizumab is a humanized monoclonal antibody that inhibits VEGF-A and could be a potential therapeutic option, although there are no reports of VEGF inhibitors being investigated as treatment for JNA to date.

Schick et al found that estrogen receptor alpha mRNA is more significant in JNA cell lines than in the stroma of nasal mucosa (18). The estrogen receptor antagonist tamoxifen was also demonstrated to inhibit proliferation of cultured JNA mesenchymal cells. However, side-effects of tamoxifen limit its clinical use for this indication. Selective estrogen antagonists are being developed, but other specific molecular targets currently remain a more realistic option for experimental treatment of JNA.

Wendler et al demonstrated the greater anti-proliferative effects of glucocorticoids on 30 JNA tissue samples compared to 20 nasal mucosa tissues in vitro (19). They also showed up-regulation of glucocorticoid receptors in JNA tissue compared to nasal mucosa. Glucocorticoids are reported to downregulate VEGF, reducing microvessel density and tumor volume (19). This is of particular interest in JNA because of previously described overexpression of VEGF (17), making glucocorticoids an intriguing but untested option for management of unresectable or recurrent JNA.

1 The mTOR (mammalian target of rapamycin) inhibitor sirolimus (rapamycin) and its analogues may  
2 offer effective targeted treatment for JNA, due to its highly vascular nature. They are potent  
3  
4 inhibitors of serine/threonine kinase, which control cellular growth processes. Notably they appear  
5  
6 to have antiangiogenic activity and have led to partial response in a case series of six patients with  
7  
8 kaposiform hemangioendotheliomas (20).  
9

10  
11  
12  
13  
14  
15  
16 Beta blockers are used in infantile hemangiomas to reduce the expression of VEGF and it has been  
17  
18 theorized that propranolol induces apoptosis due to involvement of  $\beta$ 1-adrenoreceptors in  
19  
20 angiogenesis (20). Both mTOR inhibitors and beta blockers are options for further research into JNA  
21  
22 treatment.  
23  
24  
25  
26  
27  
28

## 29 **Conclusion**

30  
31  
32  
33 Managing recurrent and unresectable JNA remains a challenge. The absence of randomized control  
34  
35 trials for anti-neoplastic drugs and RT means the role of adjuvant therapy is not well established. The  
36  
37 greatest body of evidence surrounds radiation therapy or a six week course of flutamide, but both  
38  
39 are based on small cohorts. Dexamethasone is a possible therapeutic option due to its potential  
40  
41 impact on multiple pathways, but this is yet to be proven in a clinical setting. There is a biological  
42  
43 rationale for anti-angiogenic agents and trials on anti-endoglin monoclonal antibodies are on-going,  
44  
45 but VEGF-inhibitors such as bevacizumab have yet to be investigated. Should recurrence occur in the  
46  
47 patient described in this case, the evidence-base for effective treatment is limited, particularly as  
48  
49 being pre-pubertal reduces the potential benefit of flutamide. Radiotherapy is likely to remain the  
50  
51 next most rational course of therapy. It has been demonstrated to effectively reduce tumor volume  
52  
53 and is the best option for long term survival despite the potential side effects, until more targeted  
54  
55 therapeutic options are fully evaluated. JNA is a biologically rich tumor and there is a clear need for  
56  
57  
58  
59  
60  
61  
62  
63  
64  
65

1 clinical research to evaluate adjuvant treatments to improve the outcome for recurrent and  
2 inoperable JNA.  
3

4  
5  
6  
7  
8  
9 **Acknowledgements**

10  
11 The authors would like to thank Carl H. Snyderman C, Elizabeth C. Tyler-Kabara and Paul A. Gardner  
12 at the University Of Pittsburgh Medical Centre (UPMC) for their invaluable advice and surgical  
13 expertise in managing the case described.  
14  
15  
16  
17  
18  
19  
20  
21  
22  
23  
24  
25  
26  
27  
28  
29  
30  
31  
32  
33  
34  
35  
36  
37  
38  
39  
40  
41  
42  
43  
44  
45  
46  
47  
48  
49  
50  
51  
52  
53  
54  
55  
56  
57  
58  
59  
60  
61  
62  
63  
64  
65

## References

1. Lund VJ, Stammberger H, Nicolai P et al European Rhinologic Society Advisory Board on Endoscopic Techniques in the Management of Nose, Paranasal Sinus and Skull Base Tumours. European position paper on endoscopic management of tumours of the nose, paranasal sinuses and skull base. *Rhinol Suppl.* 2010 Jun 1;(22):1-143.
2. Nicolai P, Schreiber A, Bolzoni Villaret A. Juvenile angiofibroma: evolution of management. *Int J Pediatr.* 2012; 2012: 412545.
3. Schick B, Plinkert PK, Prescher A. [Aetiology of Angiofibromas: Reflection on their Specific Vascular Component]. *Laryngorhinootologie.* 2002 Apr;81(4):280-4.
4. Hwang HC, Mills SE, Patterson K, et al. Expression of androgen receptors in nasopharyngeal angiofibroma: an immunohistochemical study of 24 cases. *Mod Pathol.* 1998; 11: 1122–1126.
5. Wang JJ, Sun XC, Hu L, et al. Endoglin (CD105) expression on microvessel endothelial cells in juvenile nasopharyngeal angiofibroma: tissue microarray analysis and association with prognostic significance. *Head Neck.* 2013; 35(12): 1719-25.
6. Hodges JM, McDevitt AS, El-Sayed Ali AI, et al. Juvenile nasopharyngeal angiofibroma: current treatment modalities and future considerations. *Indian J Otolaryngol Head Neck Surg.* 2005; 62(3): 236-47.
7. Chen KT, Bauer FW. Sarcomatous transformation of nasopharyngeal angiofibroma. *Cancer.* 1982 Jan 15;49(2):369-71.
8. Makek MS, Andrews JC, Fisch U. Malignant transformation of a nasopharyngeal angiofibroma. *Laryngoscope.* 1989 Oct;99(10 Pt 1):1088-92.
9. McAfee WJ, Morris CG, Amdur RJ, et al. Definitive radiotherapy for juvenile nasopharyngeal angiofibroma. *Am J Clin Oncol.* 2006; 29(2): 168-70.
10. Lee JT, Chen P, Safa A, et al. The role of radiation in the treatment of advanced juvenile angiofibroma. *Laryngoscope.* 2002; 112: 1213-20.

- 1  
2  
3  
4  
5  
6  
7  
8  
9  
10  
11  
12  
13  
14  
15  
16  
17  
18  
19  
20  
21  
22  
23  
24  
25  
26  
27  
28  
29  
30  
31  
32  
33  
34  
35  
36  
37  
38  
39  
40  
41  
42  
43  
44  
45  
46  
47  
48  
49  
50  
51  
52  
53  
54  
55  
56  
57  
58  
59  
60  
61  
62  
63  
64  
65
11. Chakraborty S, Ghoshal S, Patil VM, et al. Conformal radiotherapy in the treatment of advanced juvenile nasopharyngeal angiofibroma with intracranial extension: an institutional experience. *Int J Radiat Oncol Biol Phys.* 2011; 80(5): 1398-404.
12. Goepfert H, Cangir A, Lee YY. Chemotherapy for aggressive juvenile nasopharyngeal angiofibroma. *Arch Otolaryngol.* 1985; 111(5): 285-9.
13. Schick B, Kahle G, Hässler R, et al. Chemotherapy of juvenile angiofibroma--an alternative? *HNO.* 1996; 44(3): 148-52.
14. Gates GA, Rice DH, Koopmann CF Jr, et al. Flutamide-induced regression of angiofibroma. *Laryngoscope.* 1992; 102(6):641-4.
15. Labra A, Chavolla-Magaña R, Lopez-Ugalde A, et al. Flutamide as a preoperative treatment in juvenile angiofibroma (JA) with intracranial invasion: report of 7 cases. *Otolaryngol Head Neck Surg.* 2004; 130(4): 466-9.
16. Thakar A, Gupta G, Bhalla AS, et al. Adjuvant therapy with flutamide for presurgical volume reduction in juvenile nasopharyngeal angiofibroma. *Head Neck.* 2011; 33(12): 1747-53.
17. Saylam G, Yücel OT, Sungur A, et al. Proliferation, angiogenesis and hormonal markers in juvenile nasopharyngeal angiofibroma. *Int J Pediatr Otorhinolaryngol.* 2006; 70(2): 227-34.
18. Schick B, Długaiczek J, Wendler O. Expression of sex hormone receptors in juvenile angiofibromas and antiproliferative effects of receptor modulators. *Head Neck.* 2014; 36(11): 1596-603
19. Wendler O, Długaiczek J, Birk S, et al. Anti-proliferative effect of glucocorticoids on mesenchymal cells in juvenile angiofibromas. *Head Neck.* 2012; 34(11): 1615-21.
20. Margolin JF, Soni HM, Pimpalwar S. Medical therapy for pediatric vascular anomalies. *Semin Plast Surg.* 2014 May;28(2):79-86.



## Figures

**Figure 1:** Coronal MRI image showing an extensive JNA extending laterally into the pterygopalatine and masseter spaces and inferiorly into the infratemporal fossa. It extends into the right cavernous sinus and involves the right Meckel's cave.

**Figure 2:** Pathology micrographs of the JNA featured in the case: **2a)** Hematoxylin and eosin stain; **2b)**  $\beta$ -Catenin stain; **2c)** Vimentin stain.