

# Diode laser assisted horizontal bone defect regeneration in the treatment of peri-implantitis

Habash, Ghassan; Jayash, Soher

DOI:

[10.1002/ccr3.3741](https://doi.org/10.1002/ccr3.3741)

License:

Creative Commons: Attribution (CC BY)

*Document Version*

Publisher's PDF, also known as Version of record

*Citation for published version (Harvard):*

Habash, G & Jayash, S 2021, 'Diode laser assisted horizontal bone defect regeneration in the treatment of peri-implantitis', *Clinical Case Reports*, vol. 9, no. 3, pp. 1247–1252. <https://doi.org/10.1002/ccr3.3741>

[Link to publication on Research at Birmingham portal](#)

## General rights

Unless a licence is specified above, all rights (including copyright and moral rights) in this document are retained by the authors and/or the copyright holders. The express permission of the copyright holder must be obtained for any use of this material other than for purposes permitted by law.

- Users may freely distribute the URL that is used to identify this publication.
- Users may download and/or print one copy of the publication from the University of Birmingham research portal for the purpose of private study or non-commercial research.
- User may use extracts from the document in line with the concept of 'fair dealing' under the Copyright, Designs and Patents Act 1988 (?)
- Users may not further distribute the material nor use it for the purposes of commercial gain.

Where a licence is displayed above, please note the terms and conditions of the licence govern your use of this document.

When citing, please reference the published version.

## Take down policy

While the University of Birmingham exercises care and attention in making items available there are rare occasions when an item has been uploaded in error or has been deemed to be commercially or otherwise sensitive.

If you believe that this is the case for this document, please contact [UBIRA@lists.bham.ac.uk](mailto:UBIRA@lists.bham.ac.uk) providing details and we will remove access to the work immediately and investigate.

# Diode laser assisted horizontal bone defect regeneration in the treatment of peri-implantitis

Ghassan Habash<sup>1,2</sup> | Soher Nagi Jayash<sup>3</sup> 

<sup>1</sup>Periodontology Department, Faculty of Dentistry, AlQuds University, Jerusalem, Palestine

<sup>2</sup>University of Health Science, Lahor, Pakistan

<sup>3</sup>School of Dentistry, University of Birmingham, Birmingham, UK

## Correspondence

Ghassan Habash, Periodontology Department, Faculty of Dentistry, AlQuds University, Jerusalem, Palestine.  
Email: ghassan\_habash@hotmail.com

Soher Nagi Jayash, School of Dentistry, University of Birmingham, 5 Mill Pool Way, Edgbaston, Birmingham B5 7EG, UK.  
Emails: sohernaji20@yahoo.com; s.jayash@bham.ac.uk

## Abstract

Our findings show the use of a diode laser to remove inflamed tissue and regenerate the horizontal bone defects around the implant. These findings could be applied in the clinic.

## KEYWORDS

bone regeneration, diode laser, horizontal bone loss, peri-implantitis

## 1 | INTRODUCTION

This paper describes a clinical case of peri-implantitis treatment using a diode laser. In the present report, a peri-implantitis case with bone resorption up to two-thirds of the implant healed by laser and nonsurgical treatment. It is recommended to use a diode laser for horizontal bone regeneration.

Most titanium implants were constructed with a rough surface to rise the implant-bone contact areas and fix the implant in the alveolar bone. However, this surface impedes the complete elimination of bacteria from implant surfaces and may lead to peri-implantitis. Peri-implantitis is an inflammatory process that affects the tissues around the implant causing bleeding, suppuration, increased probing depth, and radiographic bone loss. It was reported that the inflammation is more prominent and the inflammatory process is more aggressive around the dental implant than around the natural tooth.<sup>1</sup> Peri-implant defects can be classified as class

I - demonstrates moderate horizontal bone loss and minimal intra-bony component. This represents an early stage of peri-implant breakdown, class II - presents moderate to severe horizontal bone loss and minimal intrabony component, class III - presents minimal to moderate horizontal bone loss with an advanced circumferential intra-bony lesion, in class IV- more complicated defects with moderate horizontal bone loss and more an advanced circumferential intra-bony lesion, furthermore, buccal and/or lingual plate has been lost.<sup>2</sup> Therapeutic goals in the treatment of peri-implantitis are removal of inflammation, improved bony attachment, and regeneration. To achieve these goals; any foreign cells and toxins should be removed from the implant surface. Subsequently, the tissue inflammation is reduced, and the healthy tissue may attach and contact the implant surface again. Thus, decontamination and detoxification of the implant surface are important.<sup>3</sup> Some treatments have been produced for cleaning and decontamination of the

This is an open access article under the terms of the Creative Commons Attribution License, which permits use, distribution and reproduction in any medium, provided the original work is properly cited.

© 2021 The Authors. *Clinical Case Reports* published by John Wiley & Sons Ltd.

implant surfaces via metal or plastic curettes or ultrasonic scalers that may cause damage to the surface of implants so it was not recommended.<sup>4</sup> Antibacterial agents and local or systemic antibiotics can be helpful in the peri-implantitis treatment.<sup>5</sup> Most of these treatments are predominantly centralized around the elimination of bacterial infection. The regenerative approach for peri-implantitis treatment is a rising problem. The ideal treatment for peri-implantitis is the regeneration of soft and hard tissues supporting dental implants.<sup>6</sup> Laser technology is developing with broad characteristics that are available for use in tissue healing, diode laser is used in different medical applications especially in photodynamic therapy and noninvasive surgical procedures. The diode laser is usually used more than other lasers because of its reliability, brightness, and compact size. Also, low level laser therapy (LLLT) can be used to enhance wound healing and effect in modulating locally and systemically. LLLT is sometimes known as photobiomodulation and its effect causing by photochemical not thermal, and the light triggers biochemical changes within cells. The principle behind the application of low level lasers is light energy application with biomodulatory capacity on body cells leading to increase cell activity.<sup>7</sup> Laser treatments were used in different application for bone treatment. The assessment of the effects of laser therapy on horizontal bone regeneration is an important field of investigation. This case report aims to describe/assess and added clinical benefits of laser in the treatment of peri-implantitis.

## 2 | CASE REPORT

### 2.1 | Methods

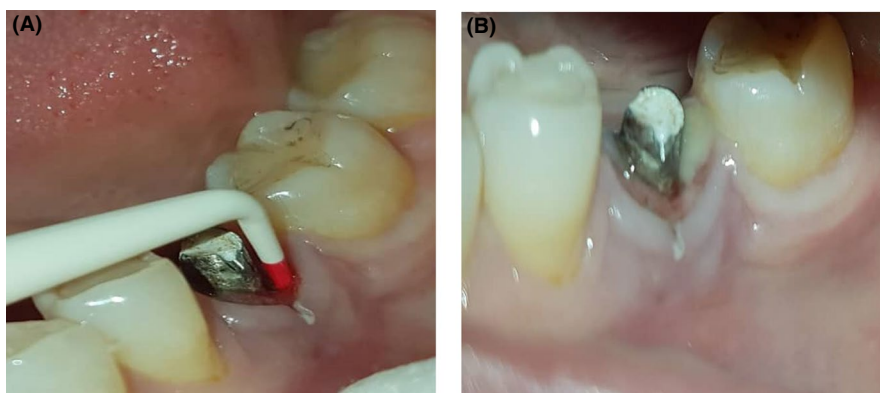
54-year-old female patient, with no significant past medical history and daily takes vitamin D (5000 IU), presented to the dental office with chief complaint pus in the implant site with a history of implant placement for lower left mandibular first molar 15 years back. On examination, peri-implant mucosa was inflamed, tender on palpation pus discharge around

implant ill-fitting crown (Figure 1). Panoramic and intraoral periapical radiographs showed crestal and horizontal bone loss around the implant (Figure 2). Also, cone beam computed tomography (CBCT) revealed bone loss around the implant suggestive of class II peri-implant defect. The bone resorption was up to two-thirds of the implant. The alveolar bone-height measurements from CBCT images bone were 3, 4.2, 3.6, 4.2 mm in mesial, distal, lingual, and buccal sides of implant respectively (Figure 3).

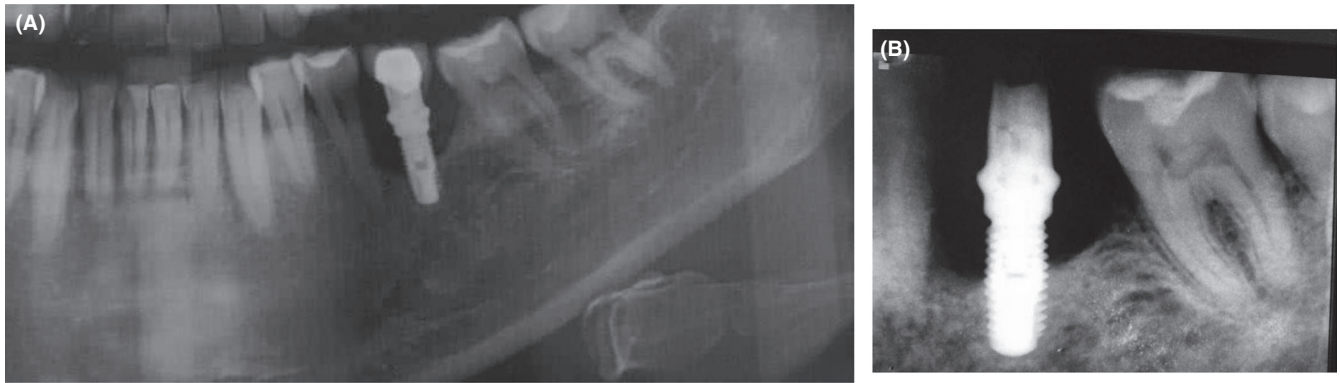
Peri-implant regenerative therapy was planned following patient consent for the treatment. The treatment started by removal of the ill-fitting crown. The pocket depth was 8 mm, nonsurgical debridement was done after achieving adequate local anesthesia by using manual titanium and plastic curettes, and excess cement removed. The air powder polishing (Prophy powder, US) was done followed by laser decontamination using hot tip (1 wt) with pulsating mode keep moving in and out for 30 seconds. Peri-implant bone was irradiated with low level laser therapy using 810 nm diode laser (QuickLase), in contact pulsating wave mode (0.1 W) in an apico-coronal, back and forth directions for 45 seconds then manual curettage and debridement followed by 12% chlorhexidine lavage. Postoperative instructions were given and Augmentin 500 mg and 250 mg flagyl for 1 week and Chlorhexidine mouthwash for 14 days twice daily. The patient was reviewed after 45 days. No fresh complaints were observed in relation to the treated site.

## 3 | RESULTS

On 2-month evaluation, intraoral periapical radiograph revealed bone lesion healing (Figure 4). On 1-year evaluation, CBCT and intraoral periapical radiograph revealed complete bone fill and the pocket depth reduced to 1 mm. The alveolar bone-height measurements from CBCT images bone were 8.5, 7.5, 6.8, 7.5 mm in mesial, distal, lingual, and buccal sides of implant respectively. The bone thickness adjacent to dental implant was 1.3, 2 mm on lingual and buccal sides of implant respectively (Figure 5).

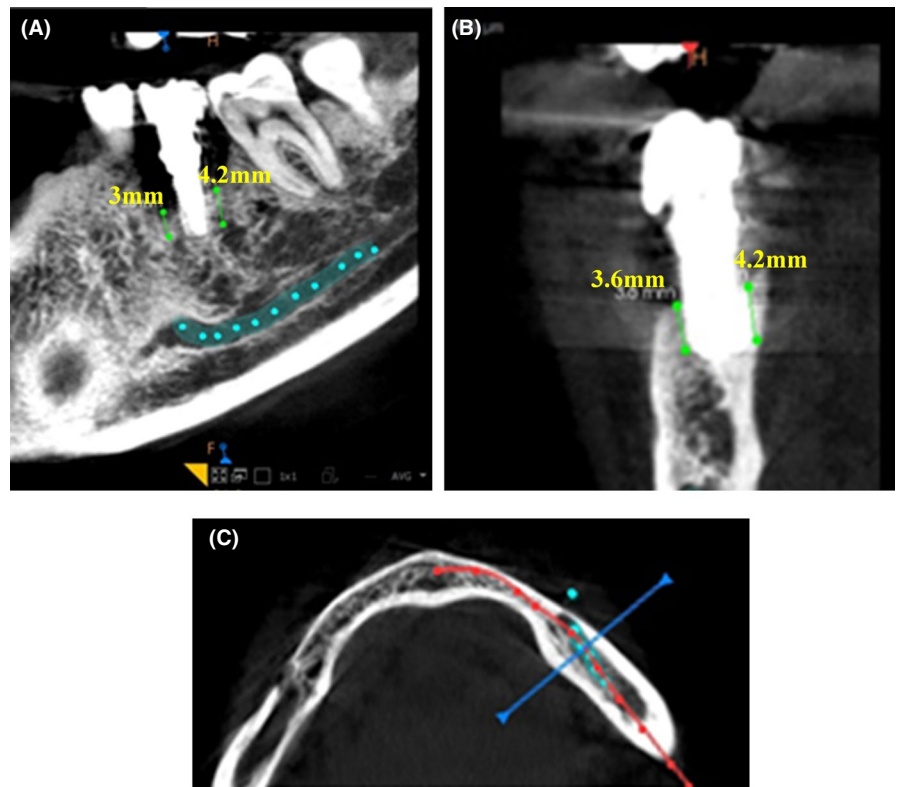


**FIGURE 1** A, Pocket depth around the implant. B, Pus discharge around implant



**FIGURE 2** A, panoramic radiograph of implant site B, Intraoral periapical radiograph of implant site

**FIGURE 3** The CBCT imaging of a peri-implantitis case showing bone resorption in mesiodistal view (A), buccolingual view (B) and axial view (C) around dental implant

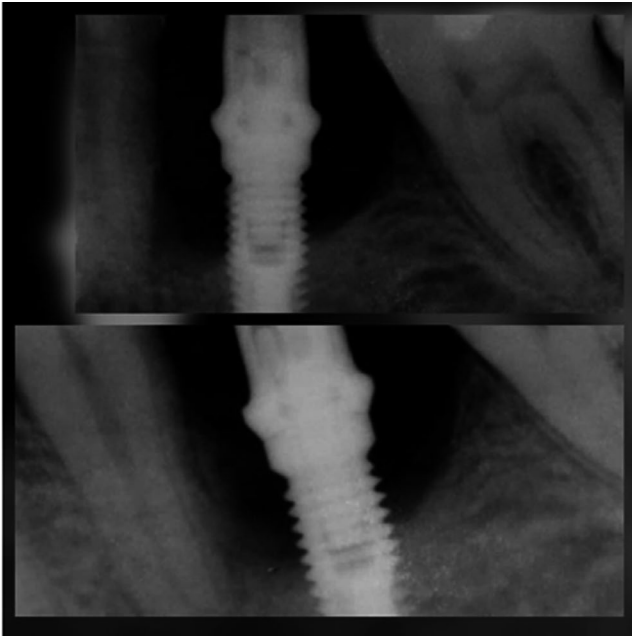


## 4 | DISCUSSION

Replacement of missing teeth with dental implants has become a standard procedure in modern day dentistry. Many clinical studies indicate that after 9-14 years post-implant placement, peri-implant lesions are a common clinical issue. Peri-implantitis is a common cause of implant loss which has some resemblance to periodontitis. Although, there are some exceptions that require the use of a different treatment technique. Nowadays, the various laser wavelengths are commonly used in implantology. However, the utilizing the high-power laser systems leading to increase in the temperature of treated tissues that may require to use laser with low level laser to provide a proper result on lesion without having

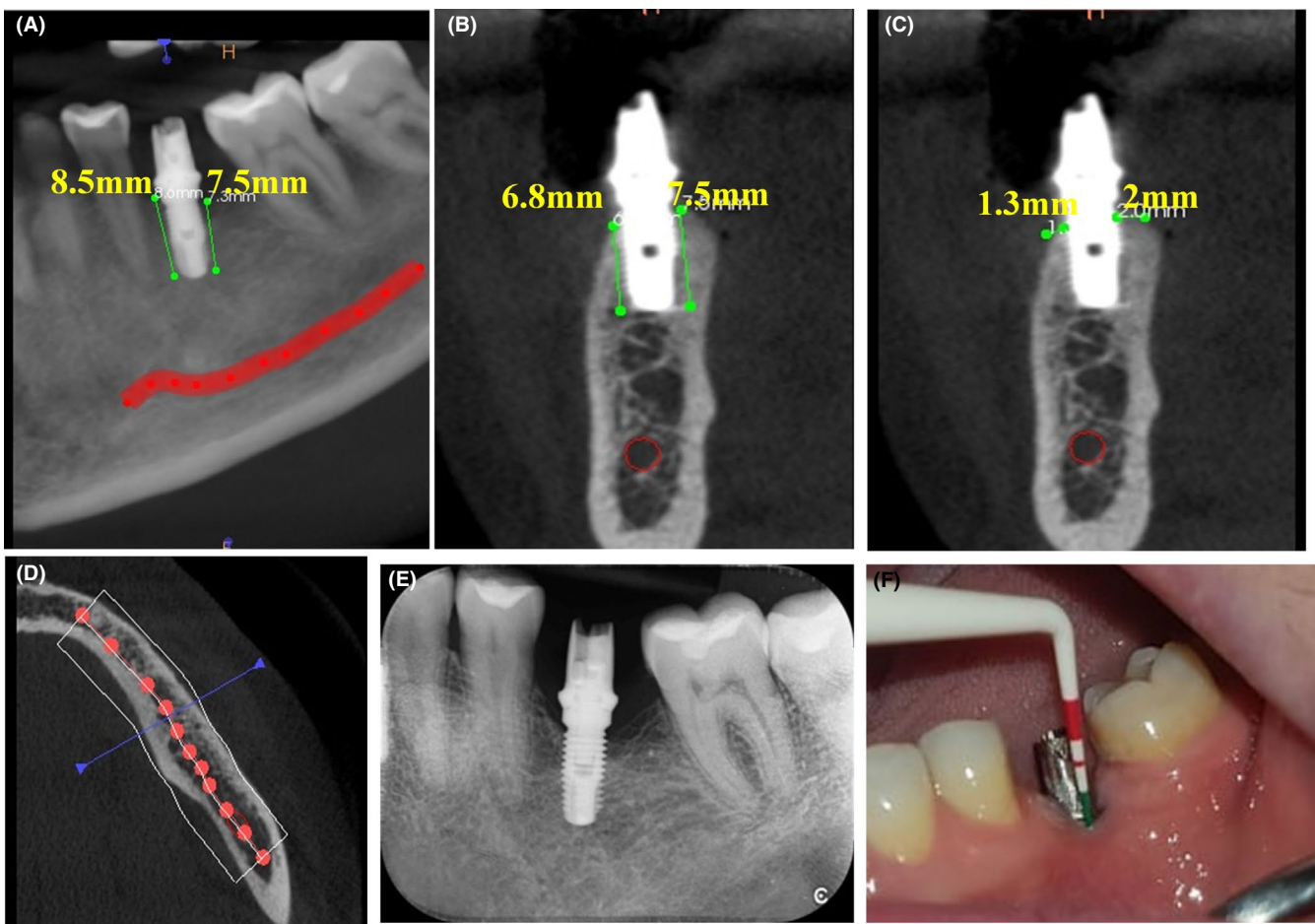
a harmful effect on surgical site.<sup>8,9</sup> The benefit of using laser around the implant over other techniques is their ability to reach hard areas around the implant to achieve better sterilization and debridement. The diode laser has a fine diode tip that removes the granulation tissue and does site sterilization without the need to remove the additional bone for treatment success and does not cause any alterations on polished and coated surfaces of implant.<sup>10</sup> Numerous in vitro and in vivo studies have been focused on the use of LLLT for oral and periodontal purposes. The current case report describes the clinical benefits of photobiomodulation in the treatment of peri-implantitis. LLLT's effect on the viability of osteocyte and tissue regeneration in peri-implant bone were evaluated using a 100-mW diode laser with 690 nm wavelength. Their





**FIGURE 4** Intraoral periapical radiograph of implant site 2 mo after treatment

results revealed a significantly higher percentage of osteocytes around implant subjected to laser irradiation immediately after implant placement compared to control. This is confirmed a positive effect of LLLT on the osseointegration.<sup>11</sup> In the same line, diode laser had a bio-stimulating effect on osteoblasts in vitro and this is may be effect on osseointegration of dental implants.<sup>12</sup> Also, animal studies showed that LLLT stimulates interaction between implant and bone, so resulting more mechanical strength on the first 8 weeks.<sup>13</sup> Another study reported a positive effect of LLLT treatment on osseointegration of dental implants placement with sinus augmentation, and enhance tissue healing.<sup>14,15</sup> In Pai et al study,<sup>16</sup> peri-implant infrabony defects showed adequate bone fill 6 months postoperatively after laser decontamination and bone augmentation. In the present case report, peri-implant infrabony defects showed adequate bone fill 1 year postoperatively after only laser therapy. Using the described protocol, the authors were able to decontaminate the implant surface efficiently and induce higher levels of cytokines eg, transforming growth factor beta-1 which promotes bone and soft tissue and bone mineralization. On the



**FIGURE 5** The CBCT imaging of a peri-implantitis case showing bone healing in mesiodistal view (A), buccolingual view (B,C) and axial view (D) around dental implant, Intraoral periapical radiograph of implant site (E), pocket depth around the implant (F) 1 y after treatment

other hand, the patient takes calcium/vitamin D daily that may enhance bone healing. However, the effects of vitamin D on bone healing are still not clear, a number of studies highlight the importance of vitamin D in bone healing. The vitamin D has an anabolic effect on osteoblasts and can to increase bone growth and bone density. Also, some studies revealed adequate calcium/vitamin D is important to provide sufficient calcium for mineralization to prevent bone loss.<sup>17-22</sup>

In this case report, complete healing and bone regeneration for horizontal bone defect around the implant which is observed by increase 3-4 mm bone height and 1-2 mm in bone thickness after one year of treatment. This is approving the effectiveness of nonsurgical treatment and LLLT in the treatment of peri-implantitis.

## 5 | CONCLUSION

This case report showed that a diode laser (810 nm) can be used for the debridement of the soft tissues around the implants. Low Level Laser Therapy using diode laser has possible bio-stimulating effects which might be used in the treatment of peri-implantitis and re-osseointegration of dental implants. Further studies on the application of this method will show the beneficial effects of laser therapy and vitamin D supplement in the treatment of peri-implantitis.

## ACKNOWLEDGEMENTS

This study acknowledges the support from the University of Birmingham and CARA.

## CONFLICT OF INTEREST

The authors declare that there are no competing interests.

## AUTHORS' CONTRIBUTIONS

GH: performed laser treatment and collect the data. SJ: wrote the manuscript and data analysis.

## ETHICAL APPROVAL

Patient consent to participate is signed before starting the treatment and submitted as supplementary1. However, ethical Approval is not applicable.

## CONSENT FOR PUBLICATION

Consent for publication is signed and submitted as supplementary1.

## DATA AVAILABILITY STATEMENT

All supporting data are available.

## ORCID

Soher Nagi Jayash  <https://orcid.org/0000-0001-5263-8557>

## REFERENCES

- Gupta HK, Garg A, Bedi NK. Peri-implantitis: a risk factor in implant failure. *J Clin Diagn Res.* 2011;5(1):138-141.
- Newman MG, Takei HH, Carranza FA. *Carranza's Clinical Periodontology*, 9th edn. Philadelphia, PA: WB Saunders; 2002:931-942.
- Valderrama P, Blansett JA, Gonzalez MG, Cantu MG, Wilson TG. Suppl 1: detoxification of implant surfaces affected by peri-implant disease: an overview of non-surgical methods. *Open Dent J.* 2014;8:77.
- Fox SC, Moriarty JD, Kusy RP. The effects of scaling a titanium implant surface with metal and plastic instruments: an in vitro study. *J Periodontol.* 1990;61(8):485-490.
- Salvi GE, Persson GR, Heitz-Mayfield LJ, Frei M, Lang NP. Adjunctive local antibiotic therapy in the treatment of peri-implantitis II: clinical and radiographic outcomes. *Clin Oral Implant Res.* 2007;18(3):281-285.
- Dreyer H, Grischke J, Tiede C, et al. Epidemiology and risk factors of peri-implantitis: a systematic review. *J Periodontol Res.* 2018;53(5):657-681.
- Fekrazad R, Chiniforush N, Bouraima SA, et al. Low level laser therapy in management of complications after intra oral surgeries. *Journal of Lasers in Medical Sciences.* 2012;3(4):135-140.
- Roos-Jansåker A-M. Long time follow up of implant therapy and treatment of peri-implantitis. *Swed Dent J Suppl.* 2007;188:7-66.
- Nikitas A. Er:YAG and diode lasers in treatment of peri-implantitis—A case report. *J Clin Diagn Res.* 2019;13(1):ZD08–ZD10.
- Stübinger S, Etter C, Miskiewicz M, et al. Surface alterations of polished and sandblasted and acid-etched titanium implants after Er: YAG, carbon dioxide, and diode laser irradiation. *Int J Oral Maxillofac Implants.* 2010;25(1):104.
- Dörtbudak O, Haas R, Mailath-Pokorny G. Effect of low-power laser irradiation on bony implant sites. *Clin Oral Implant Res.* 2002;13(3):288-292.
- Dörtbudak O, Haas R, Mailath-Pokorny G. Biostimulation of bone marrow cells with a diode soft laser. *Clin Oral Implant Res.* 2000;11(6):540-545.
- Khadra M. The effect of low level laser irradiation on implant-tissue interaction. In vivo and in vitro studies. *Swed Dent J Suppl.* 2005;172:1-63.
- Jakse N, Payer M, Tangl S, Berghold A, Kirmeier R, Lorenzoni M. Influence of low-level laser treatment on bone regeneration and osseointegration of dental implants following sinus augmentation: an experimental study on sheep. *Clin Oral Implant Res.* 2007;18(4):517-524.
- Markovic A, Kokovic V, Todorovic L. The influence of low-power laser on healing of bone defects: an experimental study. *J Oral Laser Appl.* 2005;5(3):169–172.
- Pai BJ, Shridhar A, Kamath V, Jaiswal N, Malagi S, Radhika B. Adjunctive use of diode lasers in the treatment of peri-implantitis: a case series. *J Dent Implants.* 2014;4(1):91.
- de Freitas RP, Nunes FP, dos Santos LM, et al. Influence of vitamin D in bone healing. *J Oral Diag.* 2017;2(1):1-8.
- Gorter EA, Hamdy NA, Appelman-Dijkstra NM, Schipper IB. The role of vitamin D in human fracture healing: a systematic review of the literature. *Bone.* 2014;64:288-297.
- Bee CR, Sheerin DV, Wuest TK, Fitzpatrick DC. Serum vitamin D levels in orthopaedic trauma patients living in the northwestern United States. *J Orthop Trauma.* 2013;27(5):e103-e106.

20. Fischer V, Haffner-Luntzer M, Prystaz K, et al. Calcium and vitamin-D deficiency marginally impairs fracture healing but aggravates posttraumatic bone loss in osteoporotic mice. *Sci Rep.* 2017;7(1):1-13.
21. Anderson PH. Vitamin D activity and metabolism in bone. *Curr Osteoporos Rep.* 2017;15(5):443-449.
22. Ray M. Vitamin D and fracture healing: an ongoing puzzle. *Int J Orthopaedics.* 2019;6(2):1050-1060.

**How to cite this article:** Habash G, Jayash SN. Diode laser assisted horizontal bone defect regeneration in the treatment of peri-implantitis. *Clin Case Rep.* 2021;9:1247–1252. <https://doi.org/10.1002/ccr3.3741>