

Delayed presentation of a traumatic descending thoracic aorta aneurysm as an aorto-oesophageal fistula

Mohamed, Saifullah; Patel, Akshay J; Iqbal, Yassir H; Ranasinghe, Aaron

DOI:

[10.1093/jscr/rjaa135](https://doi.org/10.1093/jscr/rjaa135)

License:

Creative Commons: Attribution-NonCommercial (CC BY-NC)

Document Version

Publisher's PDF, also known as Version of record

Citation for published version (Harvard):

Mohamed, S, Patel, AJ, Iqbal, YH & Ranasinghe, A 2020, 'Delayed presentation of a traumatic descending thoracic aorta aneurysm as an aorto-oesophageal fistula', *Journal of Surgical Case Reports*, vol. 2020, no. 7, rjaa135. <https://doi.org/10.1093/jscr/rjaa135>

[Link to publication on Research at Birmingham portal](#)

General rights

Unless a licence is specified above, all rights (including copyright and moral rights) in this document are retained by the authors and/or the copyright holders. The express permission of the copyright holder must be obtained for any use of this material other than for purposes permitted by law.

- Users may freely distribute the URL that is used to identify this publication.
- Users may download and/or print one copy of the publication from the University of Birmingham research portal for the purpose of private study or non-commercial research.
- User may use extracts from the document in line with the concept of 'fair dealing' under the Copyright, Designs and Patents Act 1988 (?)
- Users may not further distribute the material nor use it for the purposes of commercial gain.

Where a licence is displayed above, please note the terms and conditions of the licence govern your use of this document.

When citing, please reference the published version.

Take down policy

While the University of Birmingham exercises care and attention in making items available there are rare occasions when an item has been uploaded in error or has been deemed to be commercially or otherwise sensitive.

If you believe that this is the case for this document, please contact UBIRA@lists.bham.ac.uk providing details and we will remove access to the work immediately and investigate.

CASE REPORT

Delayed presentation of a traumatic descending thoracic aorta aneurysm as an aorto-oesophageal fistula

Saifullah Mohamed¹, Akshay J. Patel^{1,2,*}, Yassir H. Iqbal¹, and Aaron Ranasinghe¹

¹Department of Cardiac Surgery, Queen Elizabeth Hospital, Birmingham, Mindelsohn Way, Edgbaston, Birmingham, UK, and ²Institute of Immunology and Immunotherapy, University of Birmingham, Vincent Drive, Edgbaston, Birmingham, UK

*Correspondence address. Department of Cardiac Surgery, Queen Elizabeth Hospital Birmingham, Mindelsohn Way Edgbaston Birmingham, B15 2GW, UK. Tel: 0121 3712000; E-mail: ajp.788@gmail.com

Abstract

Aorto-oesophageal fistula is a rarely described but life-threatening complication presenting with upper gastrointestinal haemorrhage. We present a case of a 58-year-old gentleman who presented to a peripheral hospital with a short duration of haematemesis and melaena and recent onset symptoms of dysphagia. This gentleman had a past medical history of alcohol excess and a history of trauma following a road traffic accident 38 years ago. Initial computer tomography scan demonstrated a large saccular aneurysm arising from the descending thoracic aorta adjacent to the oesophagus. The patient underwent radiological stenting of the large aneurysm with thoracic endovascular aortic replacement procedure. Follow-up computerized tomography (CT) angiography demonstrated satisfactory appearances of the thoracic aortic stent graft with no evidence of endo-leak. The triad of dysphagia, occult gastrointestinal blood loss and CT findings of a large aneurysm should prompt diagnosis of aorto-oesophageal fistula until proven otherwise.

INTRODUCTION

Aorto-oesophageal fistula is a rarely described but life-threatening complication presenting with upper gastrointestinal haemorrhage. It is often insidious in onset and has a high mortality but can be managed effectively if identified promptly [1]. The causes are multifactorial and it arises as a direct communication between the oesophagus and thoracic aorta leading to catastrophic haemorrhage. Management options initially involve resuscitation, stabilization, identification of cause and initial management, which can be definitive, or as a bridge to surgery. Thoracic endovascular aortic replacement (TEVAR) has been described for managing this complex condition with mixed

results [2–4]. The prognosis of this condition is poor often due to the requirement of oesophageal procedure once the fistulous communication has been addressed. Sepsis due to infections and re-rupture is often ensuing sequelae. Spontaneous aorto-oesophageal fistula following previous history of trauma causing an undiagnosed aortic injury is rare.

CASE DISCUSSION

We present a case of a 58-year-old gentleman who presented to a peripheral hospital with a short duration of haematemesis and melaena and recent onset symptoms of dysphagia.

Received: April 8, 2020. Accepted: April 17, 2020

Published by Oxford University Press and JSCR Publishing Ltd. All rights reserved. © The Author(s) 2020.

This is an Open Access article distributed under the terms of the Creative Commons Attribution Non-Commercial License (<http://creativecommons.org/licenses/by-nc/4.0/>), which permits non-commercial re-use, distribution, and reproduction in any medium, provided the original work is properly cited. For commercial re-use, please contact journals.permissions@oup.com

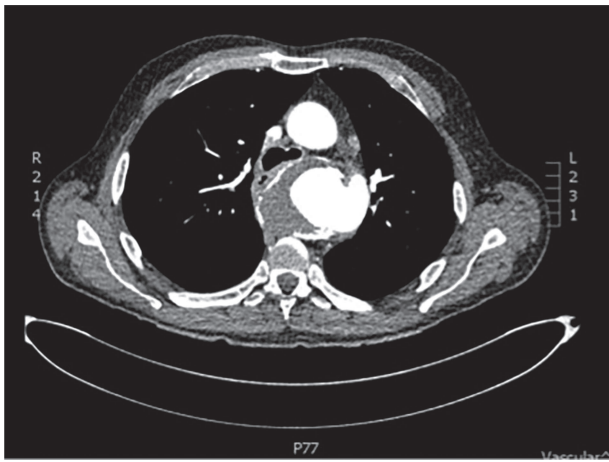


Figure 1: CT scan demonstrating close relationship of oesophagus and aortic aneurysm sac.

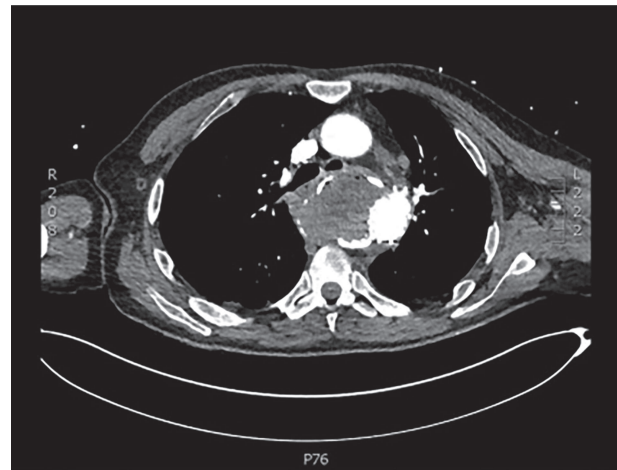


Figure 2: Angiography scan demonstrating TEVAR stent position.

This gentleman had a past medical history of alcohol excess and a history of trauma following a road traffic accident 38 years ago. The patient had no other risk factors or family history of aortopathy.

Initial basic investigations demonstrated a fall in his haemoglobin consistent with his history from 14 to 8 g/dl. Oesophago-gastro-duodenoscopy performed at the peripheral hospital was suggestive of a large Mallory-Weiss tear which was injected with adrenaline. Patient also underwent a computer tomography scan which demonstrated a large saccular aneurysm arising from the descending thoracic aorta adjacent to the oesophagus with secondary compression and displacement without any inflammatory or infective features (Fig 1). CT aortogram did not demonstrate any contrast extravasation or blush into the oesophagus, but a fistula could not be excluded. Upon review of the imaging, it was decided that the patient should be transferred to our tertiary institution for further management with a probable diagnosis of aorto-oesophageal fistula.

The patient was transferred and stabilized on the critical care unit and discussed with the interventional radiologist. In conjunction with the interventional radiologist and cardio-thoracic teams, the patient underwent radiological stenting of the large aneurysm with TEVAR procedure (Figs 2 and 3). Following the procedure, the patient continued to have large volume haematemesis and melaena and underwent repeat oesophago-gastro-duodenoscopy which demonstrated large amount of blood and clot in the distal oesophagus and stomach with continuous brisk active arterial bleeding at approximately 40 cm, which was unsuitable for any endoscopic therapy. Follow-up CT angiography demonstrated satisfactory appearances of the thoracic aortic stent graft with no evidence of endo-leak. The left subclavian artery was well opacified, and the excluded aneurysm sac contained multiple locules of gas suspicious of ongoing fistulous communication with the oesophagus. Following further stabilization, the patient underwent repeat procedure with identification of a tear in the lower third of the oesophagus. The patient was subsequently managed as an oesophageal perforation with no fluid or oral intake and was commenced on peripheral total parenteral nutrition prior to definitive primary repair.

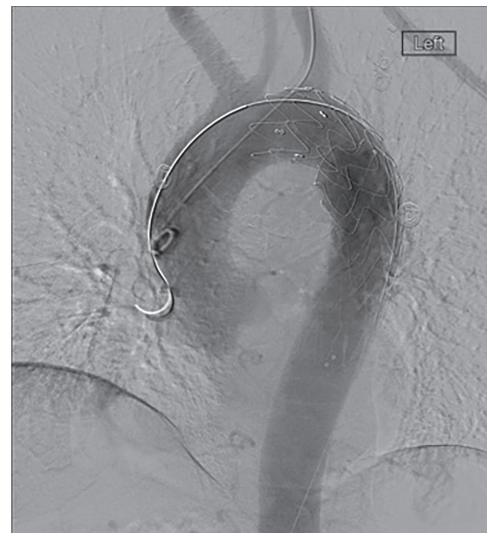

Figure 3: CT scan demonstrating patent stent with no suggestion of endoleak and lack of contrast in aneurysm sac.

DISCUSSION

We describe a rare presentation of a probable contained traumatic aortic rupture from a historical high-velocity road traffic accident presenting as an aorto-oesophageal fistula in later life. There are sparse cases in written literature discussing this life-threatening complication. With the advent of trauma guidelines and recent advances in trauma medicine, it is likely that this complication is very unlikely to be described in the future for patients who attend hospital following high-impact trauma due to the high-quality diagnostic imaging that is readily available for this cohort if patients. The triad of dysphagia, occult gastrointestinal blood loss and CT findings of a large aneurysmal aorta should always lead to the diagnosis of an aorto-oesophageal fistula until proven otherwise. Furthermore, extrinsic compression of the oesophagus with any aortic pathology or the presence of locules of gas within the aneurysm sac should be highly suspicious for the presence of an aorto-oesophageal fistula. Onset of symptoms such as dysphagia and a minor bleed (sentinel

bleed) should result in prompt referral and discussion with cardiothoracic unit for definitive management. Initial management should focus on resuscitation, stabilization and transfer to unit for definitive management. This case report illustrates the risk and management of ensuing sequelae such as the risk of re-rupture and persistent communication which also would need definitive surgical management.

CONFLICTS OF INTEREST

None to Declare.

FUNDING

Nothing to declare.

REFERENCES

1. Hollander JE, Quick G. Aorto-esophageal fistula: a comprehensive review of the literature. *Am J Med* 1991;**91**:279–87.
2. Ehara K, Tsutsumi K, Udagawa H. Surgical case report - a case of useful preventive aortic stent-grafting for an aorto-esophageal fistula that developed during a multidisciplinary therapy of an esophageal cancer invading the aorta. *Operation* 2007;**61**:1965–70.
3. Canaud L, Ozdemir BA, Bee WW, Bahia S, Holt P, Thompson M. Thoracic endovascular aortic repair in management of aorto-esophageal fistulas. *J Vasc Surg* 2014;**59**:248–54.
4. Kato N, Tadanori H, Tanaka K. Aorto-esophageal fistula-relief of massive hematemesis with an endovascular stent-graft. *Eur J Radiol* 2000;**34**:63–6.