

## Pneumatic-aorta

Mazhar, Khurum; Narain, Aditya; Mohamed, Saifullah; Patel, Akshay J; Abid, Qamar; Bouras, George

DOI:

[10.1093/jscr/rjaa193](https://doi.org/10.1093/jscr/rjaa193)

License:

Creative Commons: Attribution-NonCommercial (CC BY-NC)

*Document Version*

Publisher's PDF, also known as Version of record

*Citation for published version (Harvard):*

Mazhar, K, Narain, A, Mohamed, S, Patel, AJ, Abid, Q & Bouras, G 2020, 'Pneumatic-aorta: an unusual aetiology for stroke', *Journal of Surgical Case Reports*, vol. 2020, no. 6, rjaa193.  
<https://doi.org/10.1093/jscr/rjaa193>

[Link to publication on Research at Birmingham portal](#)

### General rights

Unless a licence is specified above, all rights (including copyright and moral rights) in this document are retained by the authors and/or the copyright holders. The express permission of the copyright holder must be obtained for any use of this material other than for purposes permitted by law.

- Users may freely distribute the URL that is used to identify this publication.
- Users may download and/or print one copy of the publication from the University of Birmingham research portal for the purpose of private study or non-commercial research.
- User may use extracts from the document in line with the concept of 'fair dealing' under the Copyright, Designs and Patents Act 1988 (?)
- Users may not further distribute the material nor use it for the purposes of commercial gain.

Where a licence is displayed above, please note the terms and conditions of the licence govern your use of this document.

When citing, please reference the published version.

### Take down policy

While the University of Birmingham exercises care and attention in making items available there are rare occasions when an item has been uploaded in error or has been deemed to be commercially or otherwise sensitive.

If you believe that this is the case for this document, please contact [UBIRA@lists.bham.ac.uk](mailto:UBIRA@lists.bham.ac.uk) providing details and we will remove access to the work immediately and investigate.

## CASE REPORT

# Pneumatic-aorta: an unusual aetiology for stroke

Khurum Mazhar<sup>1</sup>, Aditya Narain<sup>1</sup>, Saifullah Mohamed<sup>1</sup>, Akshay J. Patel<sup>1,2,\*</sup>, Qamar Abid<sup>1</sup>, and George Bouras<sup>1</sup>

<sup>1</sup>Department of Cardiothoracic Surgery, Royal Stoke University Hospital, Stoke-on-Trent, UK, and <sup>2</sup>Institute of Immunology and Immunotherapy, University of Birmingham, Birmingham, UK

\*Correspondence address. Institute of Immunology and Immunotherapy, University of Birmingham, Edgbaston, Birmingham B15 2TT, UK.  
Tel: 0121 4143344; E-mail: [ajp.788@gmail.com](mailto:ajp.788@gmail.com)

## Abstract

The following report describes a case in which air in the aorta led to stroke from cerebral emboli in a patient with distal oesophageal cancer. The patient presented with clinical features of a right-sided stroke. Computed tomography scans revealed air in the ascending aorta and brachiocephalic artery as a result of an oesophago-atrial fistula. The patient deteriorated and died soon after hospital admission despite conservative measures successfully dissipating the air. When encountered, emergent treatment of the underlying cause should be addressed but the outcome remains poor.

## INTRODUCTION

Pneumatic aorta (pneumo-aorta) or the entrapment of air into the aorta is a very rare occurrence with either a poor prognosis or diagnosis at post-mortem. Limited case numbers have been described, the main causes being iatrogenic, such as cardiopulmonary bypass and arterial endovascular management [1]. Less well-known causes include decompression-sickness and intra-arterial gas, penetrating rib injury of the aorta and associated pneumothorax [2], transthoracic needle lung biopsy, necrotizing gastroenteritis and aorto-oesophageal fistula from chronic dissection [3]. This report describes a case of pneumo-aorta secondary to oesophago-atrial fistulation and its consequent complications.

## CASE REPORT

We report a 75-year-old man with a previous diagnosis of T3N1M0 distal oesophageal adenocarcinoma, who was not considered fit enough to withstand treatment with radical intent (chemotherapy followed by surgery) due to multiple comorbidities including previous renal transplant. He was managed with palliative stenting (uncovered metal stent,

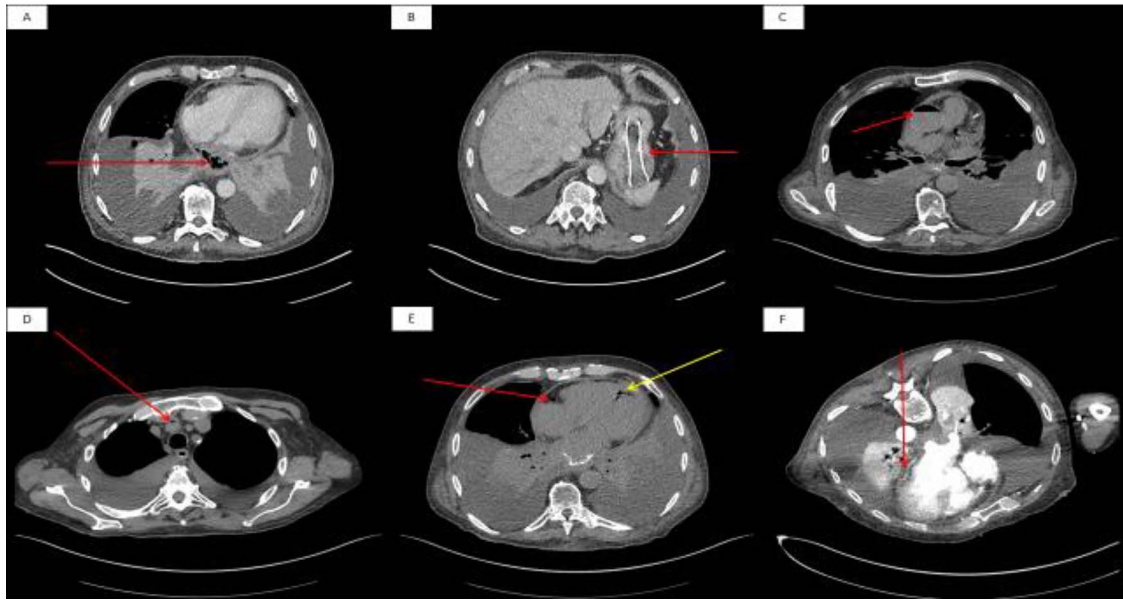
Ultraflex<sup>®</sup>, Boston Scientific), and palliative radiotherapy to achieve local disease control. As per policy of the regional cancer network, there was no plan for radiological surveillance. Any imaging offered would have been expectant and after the development of new symptoms, which the patient did not have for 6 months after his treatment and up to the point of presentation.

He presented to the acute medical service with a 2-week history of increasing lethargy and dyspnoea. An initial non-contrast enhanced computed tomography (CT) scan of his chest and abdomen (Fig. 1A and B) showed a lower oesophageal perforation and migration of the oesophageal stent into the stomach. Several hours later, the patient became somnolent and examination revealed left-sided hyper-reflexia with power 0/5 (Medical Research Council scale), left-sided facial weakness and inattention. A repeat CT scan revealed air in the ascending aorta, brachiocephalic artery and right posterior descending artery (Fig. 1C, D and E, respectively). Conservative measures were taken including nursing in the Trendelenburg position, and a repeat CT scan with contrast was organized. This third scan showed dissipation of the air, but loss of the fat plane between the left atrium and oesophagus (Fig. 1F); this was suggestive of an

Received: April 13, 2020. Revised: May 12, 2020. Accepted: May 23, 2020

Published by Oxford University Press and JSCR Publishing Ltd. All rights reserved. © The Author(s) 2020.

This is an Open Access article distributed under the terms of the Creative Commons Attribution Non-Commercial License (<http://creativecommons.org/licenses/by-nc/4.0/>), which permits non-commercial re-use, distribution, and reproduction in any medium, provided the original work is properly cited. For commercial re-use, please contact [journals.permissions@oup.com](mailto:journals.permissions@oup.com)



**Figure 1:** Initial non-contrast enhanced axial CT scan of the thorax. (A): The arrow shows lower oesophageal perforation with cavity containing air and debris in the posterior mediastinum. (B): The arrow shows migration of oesophageal stent into the stomach. A second non-contrast enhanced axial CT scan of the thorax showed air in the ascending aorta (C), brachiocephalic artery (D) and (E) right coronary artery (red arrow) and posterior descending artery (yellow arrow). A final contrast-enhanced axial CT scan of the thorax (prone position) shows loss of the fat plane at the junction of the oesophageal tumour and left atrium.

oesophago-atrial fistula (OAF). The patient developed seizures and his conscious level declined. He was treated with palliative intent and died a few hours later.

## DISCUSSION

In the present case, an OAF caused entrapment of air into the aorta. Normal left atrial pressure is 6–12 mmHg, whereas a normal oesophageal peristaltic wave generates pressures up to 80 mmHg. While a fistula between the aorta and oesophagus would normally lead to massive gastrointestinal bleeding, fistula between the oesophagus and the lower pressure left atrium would allow passage of air into the circulation, especially upon swallowing or increased intra-thoracic pressure during coughing. Air emboli, once established in the systemic circulation, would enter the cerebral circulation and result in embolic stroke. Cerebral arterial embolism as a result of OAF has been described previously, with only one case being attributed to oesophageal carcinoma [4]. We describe the first case of pneumatic-aorta as a result of such an anomalous communication causing cerebral emboli. The proximity of the left atrial (LA) to the oesophageal wall is < 5 mm in 40% of cadaveric specimens [5]. This makes it susceptible to injury during catheter ablation for atrial fibrillation. Consequential OAF has a reported incidence of up to 1% in pulmonary vein isolation and also has a grave prognosis [6, 7]. In our case, neoplastic processes had eroded the very thin fat pad layer between the infero-posterior LA wall and distal oesophagus [5]. Fistulation introduces air, food and bacteria to the circulation resulting in sepsis and embolization to the brain with multifocal infarctions. Post-mortem reports have shown the brain to be oedematous, with variably sized haemorrhagic infarctions and smooth spaces from air emboli [3]. Treatment should be directed at reversal of the underlying cause, although, in the present case, re-stenting of the oesophagus was not possible due to the patient's rapid deterioration. Intravenous antibiotics

should be administered for sepsis from migratory oesophageal particulate matter in the systemic circulation. Pneumatic-aorta in the present case was managed by the Trendelenberg position and repeat CT scan showed resolution by this measure.

## CONCLUSION

This case adds OAF to the list of aetiologies for pneumatic aorta. Furthermore, we provide evidence that simple conservative measures aid in its dissipation; it is still, unfortunately, associated with a poor outcome.

## CONFLICTS OF INTEREST

None declared.

## FUNDING

None.

## REFERENCES

1. Kao YT, Shih CM, Lin FY, Tsao NW, Chang NC, Huang CY. An endoluminal aortic prosthesis infection presenting as pneumo-aorta and aortoduodenal fistula. *World J Gastroenterol* 2012;18:5309–11.
2. Yanagawa Y, Kondo A, Yoshizawa T, Jitsuiki K, Miyake T, Ohsaka H, et al. The migration of air into the aorta from a pneumothorax in a patient with a penetrating injury of the aorta. *AORTA Journal* 2016;4:102–4.
3. Iwaki H, Kuraoka S, Tatebe S, Hioki M, Nitta T, Ochi M, et al. Pneumatic aorta: aortoesophageal fistula due to chronic aortic dissection. *J Nippon Med Sch* 2007;74:90–1.

4. Williams TL, Parikh DR, Hopkin JR, Lukovits TG, Kono AT, et al. Teaching NeuroImages: cerebral air embolism secondary to atrial-esophageal fistula. *Neurology* 2009; **72**:e54–e55.
5. Sánchez-Quintana D, Cabrera JA, Climent V, Farré J, Mendonça MC, Ho SY. Anatomic relations between the esophagus and left atrium and relevance for ablation of atrial fibrillation. *Circulation* 2005; **112**:1400–5.
6. French KF, Garcia C, Wold JJ, Hoesch RE, Ledyard HK. Cerebral air emboli with atrial-esophageal fistula following atrial fibrillation ablation: a case report and review. *The Neurohospitalist* 2011; **1**:128–32.
7. Siegel MO, Parenti DM, Simon GL. Atrial-esophageal fistula after atrial radiofrequency catheter ablation. *Clin Infect Dis* 2010; **51**:73–6.