

Geometric description for the anatomy of the mitral valve

Cruz De Oliveira, Diana; Srinivasan, Janaki; Espino, Daniel; Buchan, Keith; Dawson, Dana; Shepherd, Duncan

DOI:
[10.1111/joa.13196](https://doi.org/10.1111/joa.13196)

License:
Other (please specify with Rights Statement)

Document Version
Peer reviewed version

Citation for published version (Harvard):
Cruz De Oliveira, D, Srinivasan, J, Espino, D, Buchan, K, Dawson, D & Shepherd, D 2020, 'Geometric description for the anatomy of the mitral valve: a review', *Journal of Anatomy*, vol. 237, no. 2, pp. 209-224. <https://doi.org/10.1111/joa.13196>

[Link to publication on Research at Birmingham portal](#)

Publisher Rights Statement:

This is the peer reviewed version of the following article: Oliveira, D, Srinivasan, J, Espino, D, Buchan, K, Dawson, D, Shepherd, D. Geometric description for the anatomy of the mitral valve: A review. *J. Anat.* 2020, which has been published in final form at <https://doi.org/10.1111/joa.13196>. This article may be used for non-commercial purposes in accordance with Wiley Terms and Conditions for Use of Self-Archived Versions.

General rights

Unless a licence is specified above, all rights (including copyright and moral rights) in this document are retained by the authors and/or the copyright holders. The express permission of the copyright holder must be obtained for any use of this material other than for purposes permitted by law.

- Users may freely distribute the URL that is used to identify this publication.
- Users may download and/or print one copy of the publication from the University of Birmingham research portal for the purpose of private study or non-commercial research.
- User may use extracts from the document in line with the concept of 'fair dealing' under the Copyright, Designs and Patents Act 1988 (?)
- Users may not further distribute the material nor use it for the purposes of commercial gain.

Where a licence is displayed above, please note the terms and conditions of the licence govern your use of this document.

When citing, please reference the published version.

Take down policy

While the University of Birmingham exercises care and attention in making items available there are rare occasions when an item has been uploaded in error or has been deemed to be commercially or otherwise sensitive.

If you believe that this is the case for this document, please contact UBIRA@lists.bham.ac.uk providing details and we will remove access to the work immediately and investigate.

Geometric description for the anatomy of the mitral valve: A review

Authors

Diana Oliveira^{a,*}, Janaki Srinivasan^b, Daniel Espino^a, Keith Buchan^c, Dana Dawson^d, Duncan Shepherd^a

^a Department of Mechanical Engineering, University of Birmingham
Edgbaston, Birmingham
B15 2TT

* Corresponding author: DMC795@student.bham.ac.uk

^b Cardiac Department
Aberdeen Royal Infirmary
Aberdeen
AB25 2ZN, Scotland

^c Department of Cardiothoracic Surgery
Aberdeen Royal Infirmary
Aberdeen
AB24 2ZD, Scotland

^d Cardiology Research Facility
University of Aberdeen and Aberdeen Royal Infirmary
Aberdeen
AB25 2ZN, Scotland

Abstract

The mitral valve is a complex anatomical structure, whose physiological-functioning relies on the biomechanical properties and structural integrity of its components. Their compromise can lead to mitral valve dysfunction, associated with morbidity and mortality. Therefore, a review on the morphometry of the mitral valve is crucial, more specifically on the importance of valve dimensions and shape for its function. This review initially provides a brief background on the anatomy and physiology of the mitral valve, followed by an analysis of the morphological information available. A characterization of mathematical descriptions of several parts of the valve is performed and the impact of different dimensions and shape changes in disease is then outlined. Finally, a section regarding future directions and recommendations for the use of morphometric information in clinical analysis of the mitral valve is established.

Keywords: biomechanics, computational anatomy, mitral valve, mitral valve disease, morphology analysis

1. Introduction

The mitral valve (MV) is one of the heart's four valves, lying between the left atrium and the left ventricle. It prevents blood from flowing backwards as it moves through the heart and it has a complex geometry, comprising the mitral annulus, the anterior and posterior leaflets and the subvalvular apparatus (Figure 1). The latter is formed by the chordae tendineae and the papillary muscles (PM), which are inserted into the left ventricular wall (McCarthy et al., 2010, Dal-Bianco and Levine, 2013). These structures work in synchrony towards its effective mechanics to enable closing and opening through the cardiac cycle (McCarthy et al., 2010).

The shape of the valve is key to many aspects of its function and disease, as identified by clinical (Lee et al., 2013, Jassar et al., 2014) studies, as well as *in silico* studies, based on either porcine (Kunzelman et al., 2007), ovine (Eckert et al., 2009) or human (Stevanella et al., 2011) models, and *in vitro* studies, based on porcine (Espino et al., 2007) and ovine (Bloodworth et al., 2017) models. Assessing its morphology can reveal various normal and abnormal features, which can be associated with deteriorating clinical outcomes (Lee et al., 2013, Sonne et al., 2009, Jolley et al., 2017, Mihaila, 2013). Moreover, the physiological-functioning of the components of the MV, as well as their ability to adapt to altered stress state imposed by the passage of blood flow, rely on their biomechanical properties and structural integrity (Al-Atabi et al., 2012, Espino et al., 2007). The success of surgical interventions (such as edge-to-edge repair or chordal replacement (Al-Atabi et al., 2012)) greatly depends on the restoration of normal fluid dynamics, which typically requires valve mechanics to be corrected (Al-Atabi et al., 2012). Thus optimising a surgical procedure, or surgical timing for MV repair, is arduous (Gao et al., 2017b). The design of medical devices for the MV is also determined by its morphometry, with a previous *in vitro* study based on porcine MVs supporting the use of saddle-shaped annuloplasty ring designs to better mimic annular shape (Jimenez et al., 2007).

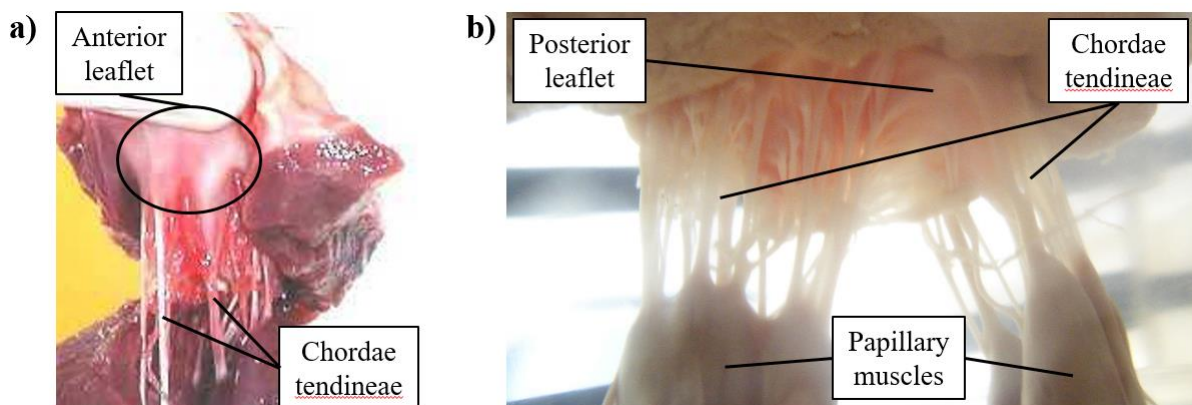


Figure 1. Porcine mitral valve apparatus: a) displays the anterior leaflet and chordae tendineae and b) focuses on the subvalvular apparatus, where chordae arise from both the PM and insert into the rough region of the posterior leaflet.

The first study reviewing the anatomic structure of the MV to identify key dimensions appeared at the beginning of the 1990s and was based on excised human and porcine MV apparatus (Kunzelman et al., 1994). This yielded basic human and porcine MV *ex vivo* measurements concerning annular and leaflet length and height, and chordal distribution. With the evolution of medical imaging modalities, *in vivo* procedures, such as three-dimensional (3D) transesophageal echocardiography, have been used to quantitatively evaluate human MV morphology in healthy and diseased cases (Lee et al., 2013, Sonne et al., 2009, Jolley et al., 2017, Mihaila, 2013, Delgado et al., 2009), proving crucial for 3D printing purposes or transcatheter MV implantation, for example. On the other hand, computational studies have mathematically represented the MV (Park et al., 2019, Salgo et al., 2002, Stevanella et al., 2009), including the annulus (Salgo et al., 2002, Stevanella et al., 2009), leaflet shape (Park et al., 2019, Stevanella et al., 2009, Shen et al., 2017), and chordae architecture (Kaiser et al., 2019) from both human and porcine dimensions and characteristics. Although many sources of MV anatomy quantification exist, a single study bringing together the current best knowledge around its morphometry, including related mathematical definitions, is lacking.

This review article aims to examine the morphometry of the MV and determine the current state of mathematical definitions of its geometrical shape. The focus is on compiling *ex vivo/in vivo* descriptions which are currently available in the literature to define the 3D geometry of the MV. The anatomy and physiology of the MV are briefly described, followed by mathematical definitions and morphometric information available (including associations between valve dimensions). Subsequently, a description of the impact of changes in MV morphometry in valve disease is performed and future recommendations for the use of morphometric information in MV clinical analysis are given.

2. Anatomy and physiology of the mitral valve

2.1 Mitral annulus and leaflets

The annulus is a ring of fibrous tissue that circumscribes the perimeter of the valvular orifice and the base of the valve, anchoring it within the left heart (Dal-Bianco and Levine, 2013). It is adjacent to the aortic valve, sharing a fibrous continuity with the left coronary and half of the non-coronary cusps of the aortic annulus (Veronesi et al., 2009, Ranganathan et al., 1970). This adjacent section defines the anterior portion of the mitral annulus, limited by the left and right fibrous trigones; the posterior part of the annulus is distal to the trigones and includes the lower points of its saddle shape (Dal-Bianco and Levine, 2013). Its shape and diameter vary during the cardiac cycle (Jiang et al., 2014),

making it a dynamic structure: in diastole the annulus has a more circular shape, while in systole it changes into a non-planar saddle shape in synchrony with valve closure/leaflet coaptation (Garbi and Monaghan, 2015, Al-Atabi et al., 2012, Dal-Bianco and Levine, 2013).

The leaflets of the MV are a continuous band of tissue extending from the annulus. According to their geometrical form and anatomical connection to the annulus, the leaflets are divided into anterior, posterior and commissural parts (Dal-Bianco and Levine, 2013, McCarthy et al., 2010). According to previous studies focusing on the human MV, the posterior leaflet has a semilunar shape and a relatively short radial length in comparison with the anterior leaflet, being composed of three minor semi-oval scallops: a central one opposite to the anterior leaflet, and two other, to each side (Ranganathan et al., 1970, Dal-Bianco and Levine, 2013, Carpentier et al., 1995). The anterior leaflet, on the other hand, is dome-shaped, longer and thicker (Ranganathan et al., 1970, Dal-Bianco and Levine, 2013). In systole, the free edge of both leaflets coapt, closing the valve (Ranganathan et al., 1970); in diastole, the free edges separate and the valve opens (McCarthy et al., 2010). Tissue characteristics of both leaflets also change accordingly to region, as stated by previous human mitral valve studies and as displayed in Figure 2: while the central portion is thinner and smoother (clear zone), towards the free edges (coaptation region) the tissue becomes thicker and rougher (rough zone) (Al-Atabi et al., 2012, Dal-Bianco and Levine, 2013, McCarthy et al., 2010): this is the main area of chordae tendineae attachment (Lam et al., 1970, Dal-Bianco and Levine, 2013). The posterior leaflet also possesses a chordae attachment area near the annulus, named the basal zone (Lam et al., 1970). Both leaflets consist of four histological layers: the uppermost one adjacent to the left atrium is the atrialis, composed of mainly aligned elastic/collagen fibres; beneath the atrialis is the spongiosa, which consists of an extracellular matrix of proteoglycans and glycosaminoglycans, along with elastic fibres, comprising the majority of the free edge; beneath the spongiosa is the fibrosa, a major load-bearing layer forming the central structural collagenous core of each leaflet, with aligned collagen fibres; finally, the ventricularis layer is covered by a continuous sheet of endothelial cells folded with elastic and collagen fibres (McCarthy et al., 2010).

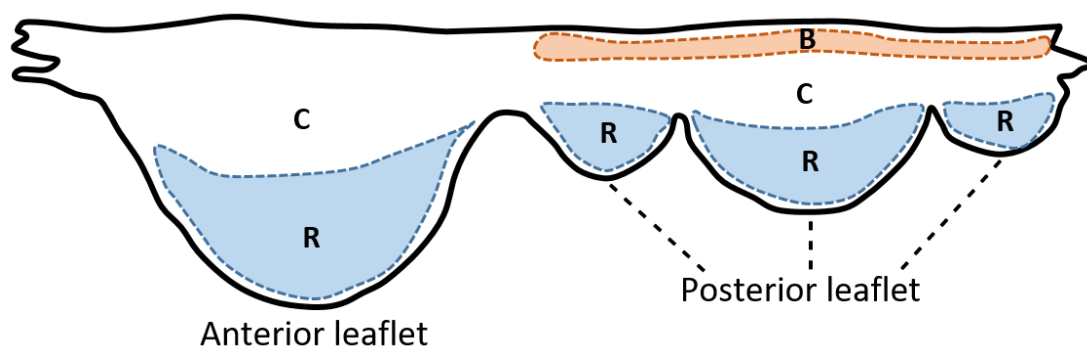


Figure 2. Human MV leaflet tissue areas. Notes: C, clear zone; R, rough zone; B, basal zone.

2.2 Subvalvular apparatus

The chordae are chord-like structures that arise from the tip of either of the two PM and insert into the leaflets (Lam et al., 1970, Al-Atabi et al., 2012). The two PMs are known as anterolateral and posteromedial, relative to the anterior and lateral body orientations and indicating the anatomical parts of the left ventricular wall into which they insert. Similarly to the mitral annulus, they are dynamic structures that move through the cardiac cycle. However, their role is unclear in the literature: previous studies focusing on dog mitral valves state that PM contraction/shortening assists in opening the MV and their elongation aids in coaptation (Marzilli et al., 1980) or that MV closing relies on PM contraction instead (Hirakawa et al., 1977). The chordae themselves are characterized according to their point of attachment and size: in a human MV, the marginal chordae are thinnest and attach to the free edge of the leaflets; basal chordae are thicker and more extensible, inserting between the free edges and the leaflet's attachment to the annulus (rough zone).

There are two thick basal chords (strut chordae) that arise from the tip of each PM and insert into the anterior leaflet: these are the largest and thickest of all chordae, carrying also the highest tension (Al-Atabi et al., 2012, Lam et al., 1970, Dal-Bianco and Levine, 2013, Lomholt et al., 2002, Wilcox et al., 2014). Their insertion region into the anterior leaflet experiences varying stretch during the cardiac cycle, which demonstrates a transfer of forces from the leaflets to the chordae and vice versa and aids in valve function (Padala et al., 2010). There are also tertiary chordae, which originate at the left ventricular wall and connect to the basal region of the posterior leaflet (Al-Atabi et al., 2012, McCarthy et al., 2010). According to porcine and ovine studies, different types of chordae have different functions: while marginal chordae maintain the leaflets closed during systole, averting regurgitation, basal chordae support and transfer loads to the leaflets, carrying also higher loads to protect marginal chordae from failure (Espino et al., 2005, Timek et al., 2001, Nielsen et al., 2003, Sedransk et al., 2002, Wilcox et al., 2014).

3. Insights into mitral valve morphometry

3.1 Mitral valve key landmarks and morphometric data

Mathematical algorithms that automatically generate parametric 3D human MV models have been developed from *in vivo* echocardiographic data (Grbic et al., 2017), four-dimensional computed tomography images (Ionasec et al., 2010) and 3D transesophageal echocardiography (Mansi et al., 2012, Zhang et al., 2017). Despite the creation of patient-specific geometries, these frameworks rely on common anatomic MV landmarks (Figure 3), from which parametric surfaces corresponding to the

mitral leaflets can be generated. These include: the left and right trigones, situated at the fibrous border between the mitral and aortic valves (Veronesi et al., 2009); the anterolateral and posteromedial commissures, located at the free edges, which are the interconnection points of the leaflets (McCarthy et al., 2010); the leaflet tips, corresponding to the line of each leaflet free-edge (Ionasec et al., 2010, Mansi et al., 2012); the posterior annular midpoint; and the PM tips (Ionasec et al., 2010, Mansi et al., 2012).

Both *ex vivo* and *in vivo* studies defined parameters that describe the human MV geometrical shape and are vital to its function. These are discretized in Table 1, and ranges of values for healthy and diseased valves are provided.

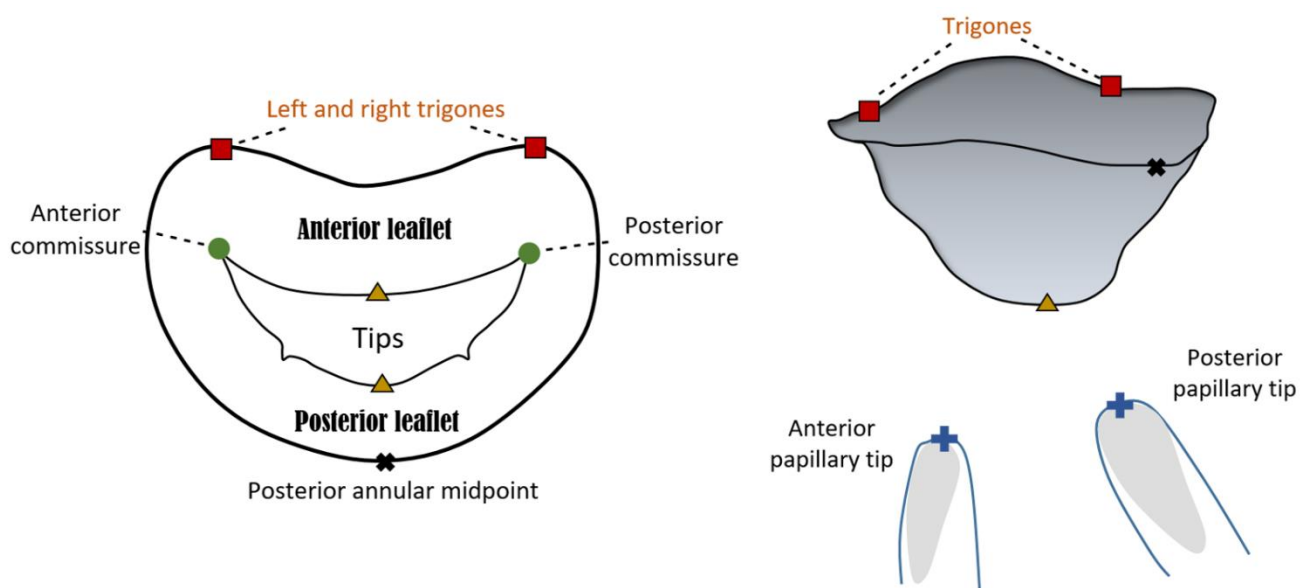


Figure 3. Atrial and lateral views of a MV schematic model based upon nine landmarks. The annulus, anterior and posterior leaflets and papillary muscle tips can be observed.

3.2 Annular proportions and saddle shape: geometrical relationships

The geometrical components of the annulus including annular anterior and posterior areas, the antero-posterior (AP), the anterolateral-posteromedial (AL-PM) and the inter-trigonal distances, represented in Figure 4a, vary over the cardiac cycle (Jiang et al., 2014). Both anterior and posterior annular portions contribute to changes in mitral annular area: although standard literature refers to annular contraction as occurring during systole, as stated in a previous ovine study (Rausch et al., 2011), there are studies based on human MVs showing annular expansion from mid-systole to early-diastole and contraction between mid-diastole and early-systole (Jiang et al., 2014, Levack et al., 2012). In addition, an *in vivo* study based on ovine MVs providing showed the presence of dynamic annular strain, with

the largest strains belonging to the posterior region and the commissural regions showing the least amount of variation (Eckert et al., 2009).

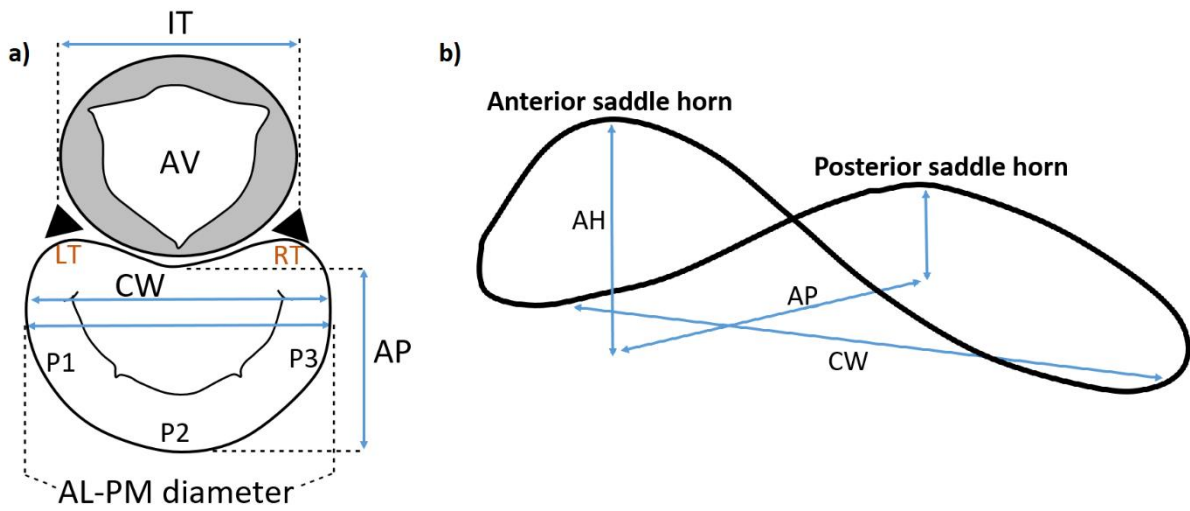


Figure 4. Atrial (a) and lateral (b) views of important mitral annular dimensions. Notes: AV, aortic valve; LT, left trigone; RT, right trigone; P1, P2, P3, posterior leaflet scallops; AL-PM diameter, anterolateral-posteromedial diameter; AP, antero-posterior distance; CW, commissural width; IT, inter-trigonal distance.

Despite this dynamic variability, the proportion concerning anterior and posterior annular circumferences in the human MV remains practically unchanged. This proportion is contradictory in the literature: while some studies mention that the anterior and posterior parts correspond to about 1/3 and 2/3 of the total annular perimeter (Garbi and Monaghan, 2015), others yield a proportionality of about 2/5 and 3/5, respectively (Pouch et al., 2014, Jassar et al., 2014). However, this proportion depends on the assumed division between leaflets, which is usually considered at the commissural level. Nonetheless, other studies divide the leaflets at the lowest annular height. The correct proportion is reflected in the literature values (obtained at mid-systole) present in Table 1 (Pouch et al., 2014, Jassar et al., 2014) and is described quantitatively by equations 1 and 2,

$$P_{AC} = 3/5 \cdot A_C \quad (1)$$

$$A_{AC} = 2/5 \cdot A_C, \quad (2)$$

where A_C is the total annular circumference and P_{AC} and A_{AC} are the posterior and anterior annular circumferences, respectively. Moreover, these proportions are firmed by correlations found in the literature, based upon dimensional data retrieved during intra-cardiac operations and dissection of fresh human hearts (Duplessis and Marchand, 1964). These yielded equations 3 ($R^2 = 0.72$, p-value < 0.01) and 4 ($R^2 = 0.93$, p-value < 0.01),

$$A_{AC} = 4.137 + 0.305 \cdot A_C, \quad (3)$$

where the A_C and A_{AC} are in mm,

$$P_{AC} = -4.137 + 0.695 \cdot A_C, \quad (4)$$

where the A_C and P_{AC} are in mm. The correlation from equation (4) was further validated through a 2D echocardiographic study concerning imaging data from 15 healthy subjects and performed by the authors. Valvar dimensions were obtained at end systole and generated a moderate correlation between the A_C and P_{AC} ($R^2 = 0.674$, p-value < 0.01). The methodology employed for equation prediction generation, as well as further characteristics of the correlations found on our study, are present in the Supplementary material.

An *ex-vivo* human study, performed within 6 hours of MV removal, examined MV geometry by assuming the mitral annulus as a circle and the A_{AC} and P_{AC} as arc lengths. This work also underlined positive linear relationships between these dimensions and the mitral annular diameter (or AL-PM distance), as given by equations 5 ($R^2 = 0.66$, p-value < 0.01) and 6 ($R^2 = 0.91$, p-value < 0.01) (Okamoto et al., 2007):

$$A_{AC} = 2.500 + 0.420 \cdot \gamma, \quad (5)$$

where γ represents the AL-PM distance and both variables are in cm,

$$P_{AC} = 4.400 + 1.200 \cdot \gamma, \quad (6)$$

where both variables are in cm. For equations 5 and 6, γ is expressed as a dimensionless Z-value in agreement with Okamoto *et al.* (2007). Further, the authors of this study have mathematically defined the A_{AC} , P_{AC} and IT distance, assuming the annulus as divided into anterior and posterior portions by the left and right trigones or commissures, as represented in Figure 5.

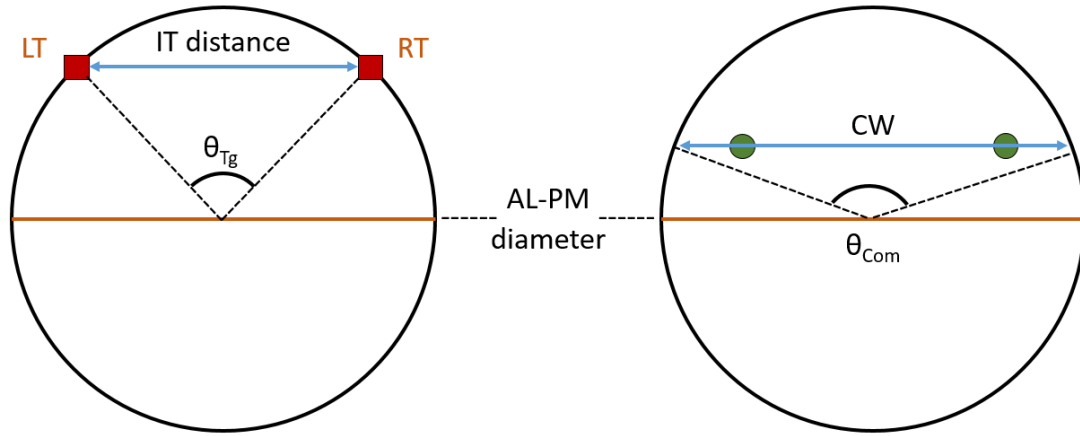


Figure 5. Circle representing the annulus, according to Okamoto *et al.* (2007), with relevant dimensions highlighted. Notes: LT, left trigone; RT, right trigone; AL-PM diameter, anterolateral-posteromedial diameter; CW, commissural width; IT distance, inter-trigonal distance; θ_{Tg} , trigonal angle; θ_{Com} , commissural angle.

Equations 7, 8 and 9 represent the mathematical definitions employed by Okamoto *et al.* (2007),

$$IT = 2 \cdot \gamma \cdot \sin\left(\frac{\theta_{Tg}}{2}\right), \quad (7)$$

$$A_{AC} = \pi \cdot \gamma \cdot \theta_{Tg} \cdot \theta_{Com}, \quad (8)$$

$$P_{AC} = \pi \cdot \gamma \cdot (360 - \theta_{Tg} \cdot \theta_{Com})/360, \quad (9)$$

where IT is the inter-trigonal distance, γ is the AL-PM distance, θ_{Tg} is the angle between left and right trigones and θ_{Com} is the angle between commissures at the annular plane (Okamoto et al., 2007). However, these definitions simplify the shape of the anterior leaflet to great extent and do not accurately represent its real configuration.

An association between the annular circumference and the total leaflet free edge length has also been found based on the *ex vivo* human MV data from Duplessis *et al.* (1964). Greater total and posterior annular circumferences were moderately correlated with increased free edge lengths, as provided in the equations below,

$$\delta = 18.824 + 0.704 \cdot A_C, \quad (10)$$

where δ represents the free edge length, and both variables are in mm ($R^2 = 0.76$, p-value < 0.01),

$$\delta = 26.301 + 0.964 \cdot P_{AC}, \quad (11)$$

where both variables are in mm ($R^2 = 0.74$, p-value < 0.01),

Annular shape is distinctive due to its similarity with a saddle, being characterized by an annular height (AH) (Figure 4b). This is characteristic of a healthy valve, as it reduces leaflet stress and decreases anterior systolic strain, potentially increasing repair durability (Salgo et al., 2002, Jimenez et al., 2007). In practice, a deeper saddle relates to more apical positions of the medial and lateral aspects of the annulus, while the anterior and posterior aspects remain basal (Salgo et al., 2002). This is mathematically described by the annular height to commissural width ratio (AHCWR), which provides with a quantitative measure of annular nonplanarity (Lee et al., 2013, Pouch et al., 2014, Jassar et al., 2014). According to this, we can also define the AHCWR as

$$\varepsilon = \text{AH/AP} \cdot \text{CI}, \quad (12)$$

where ε represents the AHCWR, AH is the annular height, AP is the antero-posterior distance and CI is the circularity index. The latter is defined as the ratio between the AP diameter and the commissural width (CW) and accounts for the greater or smaller ellipsoidal shape of the annulus (Lee et al., 2013, Pouch et al., 2014).

The human MV AHCWR profile depends on the rotational position of the annulus, and has led to the generation of new annuloplasty ring designs (Pouch et al., 2014, Jassar et al., 2014). In fact, saddle shape variability impacts on leaflet stress variation (Salgo et al., 2002): a deeper saddle shape, associated with a higher AHCWR percentage (Lee et al., 2013), leads to leaflet peak stress reduction, as predicted by computational studies (Salgo et al., 2002). Further, geometric correlations concerning the AL-PM distance and other mitral annular dimensions have been found both in the literature and in our 2D echocardiographic study. For example, a clinical 3D transesophageal echocardiography study focusing on the end-systolic frame yielded that lower non-planarity angles (NPA) were associated with increased AH to the AL-PM distance ratios, as given by equation 13 ($R^2 = 0.70$, p-value < 0.01) (Warrach et al., 2012),

$$\text{NPA} = 179.600 - 163.900 \cdot \sigma, \quad (13)$$

where σ represents the AH to the AL-PM distance ratio (dimensionless) and the NPA is in $^\circ$. A moderate association between the ratio of the AH to the AL-PM distance and the ratio of the AH to the AP distance was also found ($R^2 = 0.78$, p-value < 0.01) (Warrach et al., 2012):

$$\sigma = 0.027 + 0.970 \cdot \tau, \quad (14)$$

where τ represents the AH to the AP distance ratio. Nonetheless, given mitral annular dynamic shape changes through the cardiac cycle (the AH suffers a total percentage change of 13.5 ± 7.8 in the cardiac cycle, for example (Tang et al., 2019)), we cannot assume that the relationships afore mentioned are maintained both in systole and in diastole.

Our 2D echocardiographic study revealed a moderate association between the AL-PM distance and the inter-trigonal distance at end-systole, displayed in equation 15 ($R^2 = 0.65$, p-value < 0.01):

$$IT = 19.280 \cdot e^{(0.017 \cdot \gamma)} \quad (15)$$

where IT represents the inter-trigonal distance and both variables are in mm.

The AP distance is also geometrically associated with other annular parameters in the human MV. Equations 16 and 17 present moderate correlations between the ratio of the AH to the AP distance and the NPA ($R^2 = 0.64$, p-value < 0.01) and between the 2D annular area and the AP distance ($R^2 = 0.65$, p-value < 0.01), respectively, generated with data obtained at end-systole:

$$NPA = 177.580 - 142.880 \cdot \tau, \quad (16)$$

where τ is dimensionless and the NPA is in $^\circ$,

$$AP = 18.206 + 0.016 \cdot A_{na}, \quad (17)$$

where A_{na} is the annular area in mm^2 and AP is in mm.

The annular saddle shape has been mathematically defined through paraboloid equations, which are quadric surfaces with one axis of symmetry and no centre of symmetry (Salgo et al., 2002, Stevanella et al., 2009, Park et al., 2019). In Salgo *et al.* (2002), for example, hyperbolic paraboloids were employed (Salgo et al., 2002), while Park *et al.* used hyperbolic paraboloids for the saddle shape definition. In addition, they designed a ring-shaped structure, mathematically described as a curved toroid and with empirical relationships derived below (Park et al., 2019),

$$z = \frac{(x - \alpha_L)^2}{a \cdot \alpha_V} - \frac{(y - \beta_L)^2}{b \cdot \beta_V}, \quad (18)$$

MV component	Geometric variables	Meaning	Ranges	
			Healthy	Diseased
Annulus	AP diameter [mm]	Distance between anterior and posterior annular midpoints	30±6*	38.8±6.4 [†]
	CW [mm]	Annular diameter at the commissures	33.3±3.7 [†]	42.2±5.9 [†]
	AL-PM diameter [mm]	Diameter between anterolateral and posteromedial landmarks	31±5*	39±7*
	Annular circumference [mm]	Total perimeter of the annular edge	106±10 [†]	136±19 [†]
	Anterior/posterior circumferences [mm]	Perimeter of the anterior/posterior annular edges	Anterior: 43.3±8.2* Posterior: 63.01±9.06*	Anterior: 61.3±8* Posterior: 75±11*
	Annular height [mm]	Vertical distance between highest and lowest annular points	7.9±1.9 [†]	5.6±1.6 [†]
	Annular area [mm ²]	Area enclosed by the 2D projection of the annulus	780±270*	1343±392 [†]
	NPA [°]	Angle between anterior and posterior annular midpoints at the commissure	144±11*	157±12*
	IT distance [mm]	Distance between left and right trigones	30±3 [‡]	31±3 [‡]
Leaflets	Anterior/posterior lengths [mm]	Length from anterior/posterior annular midpoints to coaptation	Anterior: 21.2±3.0 [†] Posterior: 9.8±2.0 [†]	Anterior: 26.3±6.1 [†] Posterior: 16±5 [†]
	Anterior/posterior areas [mm ²]	Surface area of anterior/posterior leaflets	Anterior: 530±210* Posterior: 380±130*	Anterior: 760±190* Posterior: 610±230*
	Posterior scallop lengths [mm]	Length from each scallop free margin to annulus	P1: 5-17; P2: 7-20; P3: 7-20 [※]	P1: 16±5; P2: 19±6; P3: 16±4*
	Commissural heights [mm]	Height from each commissural free margin to annulus	AL: 5-13; PM: 4-12 [※]	-----
	Leaflet angles [°]	Angle created by the anterior/posterior leaflets with the annulus line	Anterior: 24.6±7* Posterior: 34.7±9.6*	Anterior: 33.2±8.6* Posterior: 44.4±11.9*
	Tenting height [mm]	Distance from the annulus to coaptation	7.4±1.3 [‡]	9.7±3.2*
	Tenting area [mm ²]	Silhouette delineated by leaflets from annulus to coaptation	118.2±32.6 [‡]	350±50*
Subvalvular apparatus	PM length [mm]	Length from each PM to anterior annular midpoint	ALPM: 28.1±4.1 [†] PMPM: 28.5±4.8 [†]	ALPM: 40.5±6 [†] PMPM: 41.8±5.9 [†]
	Inter-papillary distance [mm]	Distance between PMs	Inner: 14.4±4.8* Outer: 31.1±5.4*	Inner: 26.7±8.4* Outer: 43.1±9.7*
	Inter-papillary angle [°]	Angle between anterior annular midpoint to both PMs	26.2±6.5 [‡]	28.9±6.3 [‡]

Table 1. Geometric variables of the MV and healthy and diseased (significant regurgitation) literature ranges ((Lee et al., 2013, Mihaila, 2013, Machino-Ohtsuka et al., 2016, Obase et al., 2016, Deorsola and Bellone, 2018, Jassar et al., 2014, Calleja et al., 2015, Sonne et al., 2009, Pouch et al., 2014, Jiang et al., 2014, Suri et al., 2009, Owais et al., 2016, Kunzelman et al., 1994, Ranganathan et al., 1970, Delgado et al., 2009, Dudzinski and Hung, 2014, Yamaura, 2008, Kim et al., 2014, Topilsky et al., 2013)). Dimensions obtained at: [‡], early systole; *, mid-systole; [†], end-systole; [‡], averaged over cardiac cycle; [※], *ex vivo*. Notes: AP, antero-posterior; CW, commissural width; AL-PM, anterolateral-posteromedial; NPA, non-planarity angle; IT, inter-trigonal; PM, papillary muscle; P1, posteromedial commissural scallop; P2, posterior middle scallop; P3, anterolateral commissural posterior scallop; AL, anterolateral; PM, posteromedial; ALPM, anterolateral papillary muscle; PMPM, posteromedial papillary muscle.

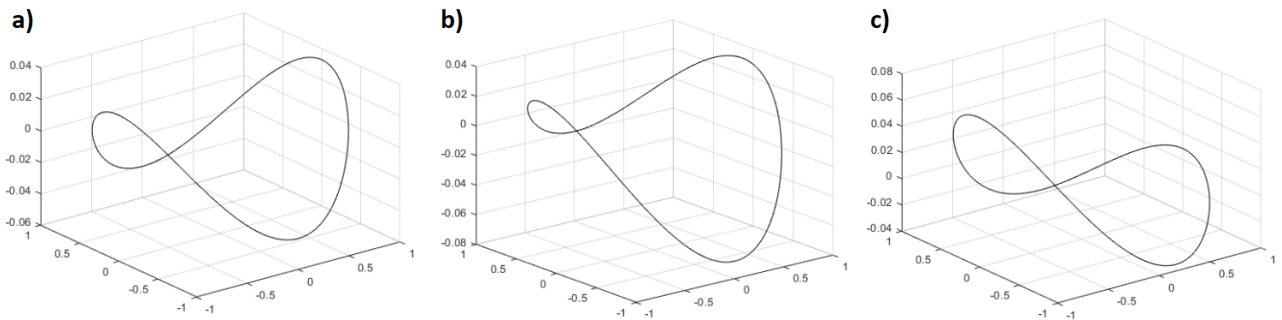
5 where α_L and β_L are transformation parameters in lateral directions in the xy plane that define the
 6 saddle point, α_V is a transformation parameter in the vertical direction in the xz plane and β_V is the
 7 transformation parameter in the vertical direction in the yz plane. These parameters vary between 0
 8 and 1) and a and b are determined by annular dimensions,

$$a = \frac{(\gamma)^2}{4 \cdot AH} \quad (19)$$

$$b = \frac{(AP)^2}{4 \cdot AH} \quad (20)$$

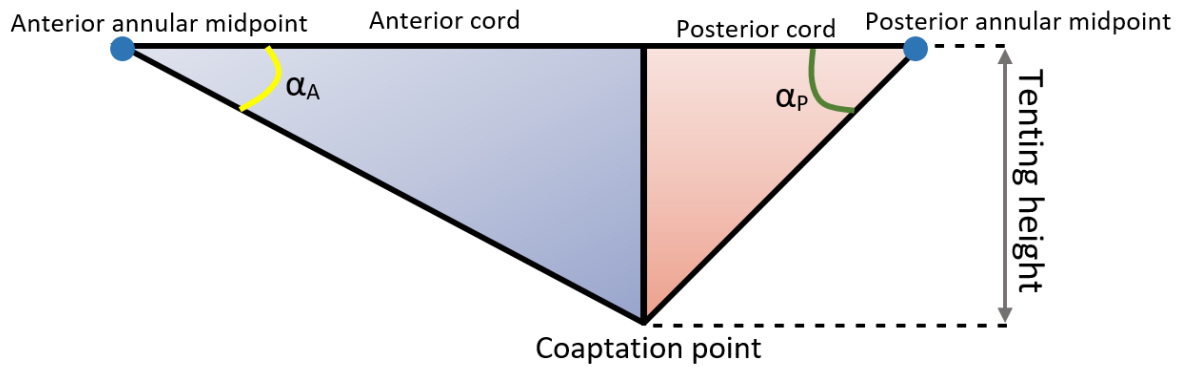
9

10 Equation 18 allows the manipulation of lateral and vertical curve transformations representative of
 11 changes in saddle depth and commissural height, for example (see Figure 6).



12
 13 Figure 6. Hyperboloids representing the MV saddle shape and defined by equation 11 (Park et al., 2019) are displayed,
 14 created upon literature values for CW (33.3 mm), AP diameter (28 mm), AL-PM diameter (31 mm) and AHCWR (0.237).
 15 We can observe different commissural heights (b) and posterior annular depth (c) in comparison with a pure hyperboloid
 16 (a), given by changes in transformation parameters.
 17

18 The NPA is not the only factor influencing annular saddling: the leaflet angles (α_A , and α_P , represented
 19 in Figure 7) and the overall coaptation triangle (2D triangle formed by the AP diameter, anterior and
 20 posterior leaflets when the leaflets coapt), including tenting height and tenting area, also play an
 21 important role in the evaluation of human MV geometry and function (Deorsola and Bellone, 2018,
 22 Delgado et al., 2009, Silbiger, 2011, Ciarka et al., 2010). A schematic of this coaptation triangle is
 23 represented in Figure 7, as well as related linear and angular dimensions. A previous study
 24 hypothesized that the coaptation triangle of healthy valves could be based on the Golden Proportion,
 25 a ratio observed in Nature which derives from sectioning a certain segment in two different parts
 26 (Deorsola and Bellone, 2018). Such ratios yield an irrational number (rounded to 0.618 or 1.618)
 27 known as the Golden Proportion. This study states that the value of 0.618 can be obtained through the
 28 ratio between the anterior cord and the AP diameter, between the posterior and the anterior cords and
 29 between the tenting height and the posterior cord.



30
 31 Figure 7. Coaptation triangle. The tenting height divides the base of the triangle (AP diameter) into two segments – the
 32 anterior and the posterior cords. Notes: α_A , anterior leaflet angle; α_P , posterior leaflet angle.

33

34 Indeed, Deorsola *et al.* found strong correlations between the original coaptation triangle and the
 35 Golden (or mathematical) one at early systole (time point of measurements), showing good positive
 36 linear relationships between the AP diameter and the anterior cord (equation 21, $R^2 = 0.97$, p-value <
 37 0.01) and between anterior and posterior cords (equation 22, $R^2 = 0.82$, p-value < 0.01).

$$A_{\text{cord}} = 1.391 + 0.580 \cdot \text{AP}, \quad (21)$$

38

39 where the AP diameter and A_{cord} (anterior cord) are in mm,

$$P_{\text{cord}} = -1.279 + 0.667 \cdot A_{\text{cord}}, \quad (22)$$

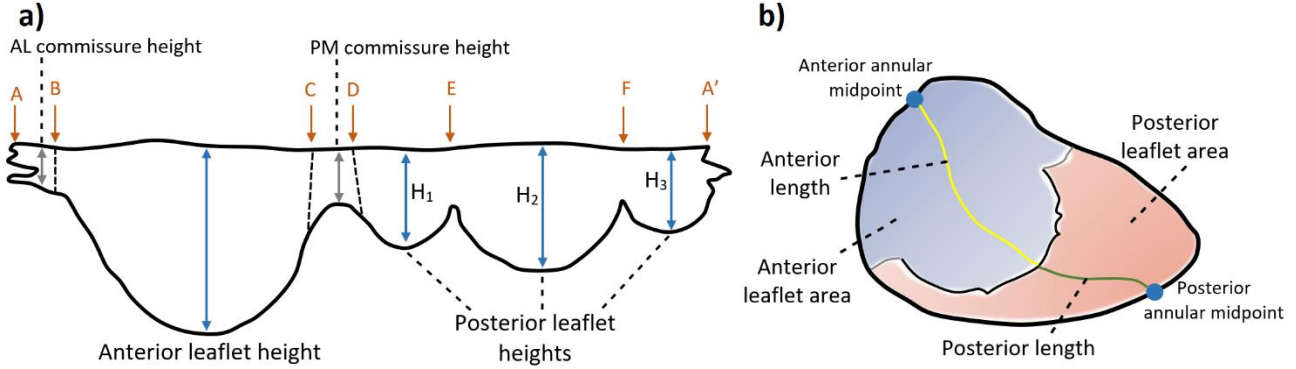
40

41 where the A_{cord} and P_{cord} (posterior cord) are in mm. Unfortunately, Deorsola *et al.* mention that, due
 42 to technical imaging limitations, they were unable to assess the coaptation triangle and repeat
 43 measurements for each frame of the cardiac cycle, determining whether the Golden Proportion or the
 44 correlations found would be maintained both in systole and diastole (Deorsola and Bellone, 2018).
 45 Nonetheless, the anterior and posterior leaflet angles are an important element for the evaluation of
 46 leaflet tethering, with a posterior leaflet angle of 45 degrees or above being an index of severe leaflet
 47 tethering in ischemic mitral regurgitation. In fact, a previous study found that a P3 tethering angle
 48 below 28.8 degrees would predict the improvement of this type of regurgitation after surgery (Bouma
 49 and Gorman, 2019, Sun et al., 2019). From a diagnostic and surgical point of view, this means that
 50 leaflet angles could represent important parameters to identify early anatomical alterations or to
 51 improve surgical strategy and postoperative evaluation, especially when correlated with other MV
 52 dimensions of the coaptation triangle (Deorsola and Bellone, 2018).

53

54 3.3 Leaflet dimensions and shape

55 Figure 8 shows anterior and posterior leaflet heights and lengths, as well as commissural length and
 56 leaflet area for a generic human MV.



57 Figure 8. Parameters of human MV leaflet geometry, with an extended (a) and closed (b) leaflet representation. Notes: A-
 58 B, anterolateral commissure; B-C, anterior leaflet; C-D, posteromedial commissure; D-A', posterior leaflet; D-E,
 59 posteromedial commissural scallop (P1); E-F, middle scallop (P2); F-A', anterolateral commissural scallop (P3).
 60

61 Geometrical associations concerning the anterior leaflet have been determined from *ex vivo* human
 62 data from Duplessis *et al.* (1964). Dependencies between anterior leaflet surface area and other
 63 dimensions of the valve were discovered: correlations are present between this area and the A_C
 64 (equation 23, $R^2 = 0.70$, p-value < 0.01) and A_{AC} (equation 24, $R^2 = 0.81$, p-value < 0.01); and a
 65 moderate correlation between this area and the free edge lengths (equation 25, $R^2 = 0.62$, p-value <
 66 0.01),
 67

$$A_{LA} = 127.300 + 3.549 \cdot A_C, \quad (23)$$

68 where A_{LA} is the anterior leaflet surface area (in mm^2) and the A_C is in mm,
 69

$$A_{LA} = 114.830 + 10.630 \cdot A_{AC}, \quad (24)$$

70 where the A_{AC} is in mm and the A_{LA} is in mm^2 ,
 71

$$\delta = 17.840 + 0.150 \cdot A_{LA}, \quad (25)$$

72 where the A_{LA} is in mm^2 and δ is in mm (Duplessis and Marchand, 1964).
 73

74 Similarly, further human *ex vivo* correlations between the posterior leaflet surface area and other
 75 dimensions of the valve were obtained from Duplessis *et al.* (1964), including: good associations with

76 the A_C (equation 26, $R^2 = 0.85$, p-value < 0.01) and with the P_{AC} (equation 27, $R^2 = 0.82$, p-value $<$
77 0.01) and a moderate association with the free edge length (equation 28, $R^2 = 0.75$, p-value < 0.01),

$$P_{LA} = 65.749 + 4.262 \cdot A_C, \quad (26)$$

78

79 where P_{LA} is the posterior leaflet surface area (in mm^2) and the A_C is in mm,

$$P_{LA} = 113.250 + 5.798 \cdot P_{AC}, \quad (27)$$

80

81 where the P_{AC} is in mm and the P_{LA} is in mm^2 ,

$$\delta = 14.797 + 0.152 \cdot P_{LA}, \quad (28)$$

82

83 where the P_{LA} is in mm^2 and δ is in mm (Duplessis and Marchand, 1964).

84 In addition, a moderate correlation between anterior and posterior leaflet surface areas was also
85 discovered from the data from Duplessis *et al.* (1964) (Duplessis and Marchand, 1964) (equation 29,
86 $R^2 = 0.71$, p-value < 0.01),

$$P_{LA} = 53.285 + 0.914 \cdot A_{LA}, \quad (29)$$

87

88 where the A_{LA} and P_{LA} are in mm^2 (Duplessis and Marchand, 1964).

89 The posterior leaflet has been mathematically characterized as a continuous shape around the annulus,
90 with (Stevanella et al., 2009, Stevanella et al., 2011, Choi et al., 2016) or without (Kunzelman et al.,
91 1993, Cochran and Kunzelman, 1998, Kunzelman et al., 2007, Domenichini and Pedrizzetti, 2015)
92 scallop indentations. The main focus has been given to the mathematical definition of the complete
93 leaflets free margin. This has been generated through mathematical harmonic functions (Stevanella et
94 al., 2009), spline functions (Stevanella et al., 2011) and parametric equations (Domenichini and
95 Pedrizzetti, 2015). However, these frameworks simplify leaflet shape to great extent, resulting in
96 overly idealised geometries.

97 Better leaflet geometrical descriptions are have been recently developed: Khaligi *et al.* (2018) built
98 high quality 3D parametric models of MV leaflet surfaces using *ex vivo* high-resolution images from
99 ovine MV, obtained through micro-computed tomography. They then employed quadric surfaces
100 representing toroidal topology to create parametric large-scale models of the MV and information on
101 the deviation between parameterized models and the original geometries to derive leaflet local
102 thickness (Khalighi et al., 2018). Other study focused on the development of *ex vivo* methods to inform

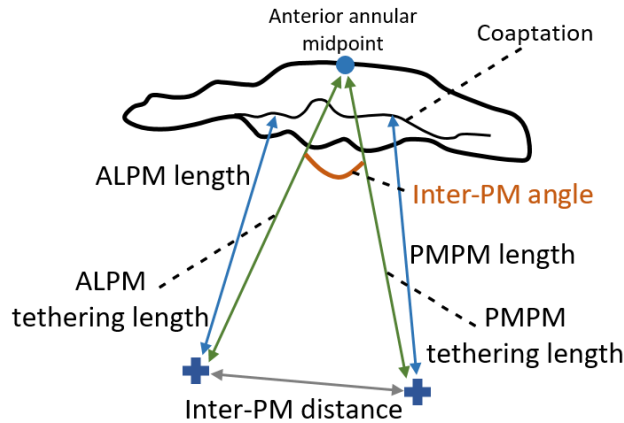
103 on the sensitivity of model performance to the accuracy of the input geometry and to acquire
104 comprehensive data sets to validate computational simulations against (Bloodworth et al., 2017). These
105 works could be potentially employed on high-fidelity MV models concerning healthy, diseased and
106 repair states; however, since it relies on images obtained through an *ex vivo* imaging modality, its
107 translation to the generation of *in vivo* human MV models remains challenging.

108

109 *3.4 Papillary muscle position and chordae insertion*

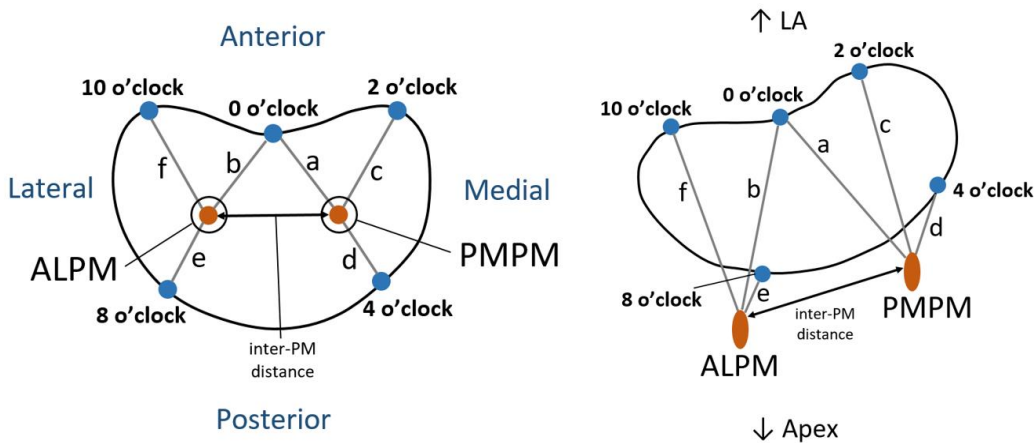
110 The human PMs exhibit great morphological variability (Stevanella et al., 2011, Stevanella et al.,
111 2009). Although two in number (Al-Atabi et al., 2012), there are usually groups of muscles adjoining,
112 reaching a total number as high as five and attaching to the left ventricular wall either at its middle,
113 upper or lower sections (Saha and Roy, 2018). Moreover, their shape is diversified, resembling either
114 a cone (conical shape) or a elliptic paraboloid, having a truncated shape, or being bifurcated or
115 trifurcated (Saha and Roy, 2018). Further, the number of chordae tendineae that attach to the PM, as
116 well as their insertion distribution, is a source of variability. These features contribute to PM
117 morphological heterogeneity, either in shape or attachment site. Therefore, current mathematical
118 representations of the PM as unique points are restrictive and not accurately representative.

119 The PMs spatial position in humans has been mathematically defined, especially taking into account
120 measurements such as their distance to the mitral annulus or to mitral coaptation (Yamaura, 2008,
121 Sakai et al., 1999). Other measures of interest, such as the distance between PM or the inter-PM angle,
122 have also been employed to describe PM morphology (Figure 9). Some studies have provided
123 measurements of the PM to five key annular sites named o'clock points (Figure 10) (Sakai et al., 1999,
124 Yamaura, 2008). Here, each PM is associated with three distances to the annulus, allowing the
125 description of the 3D spatial position of their tips if assumed as a unique 3D point. More recently,
126 another study has employed knowledge on similar measurements to build a high-resolution 3D
127 magnetic resonance imaging apparatus, giving rise to high quality 3D models of the whole human MV
128 structure (Stephens et al., 2017).



129
130 Figure 9. Measurements describing PM morphology. Notes: ALPM, anterolateral PM; PMPM, posteromedial PM.

131

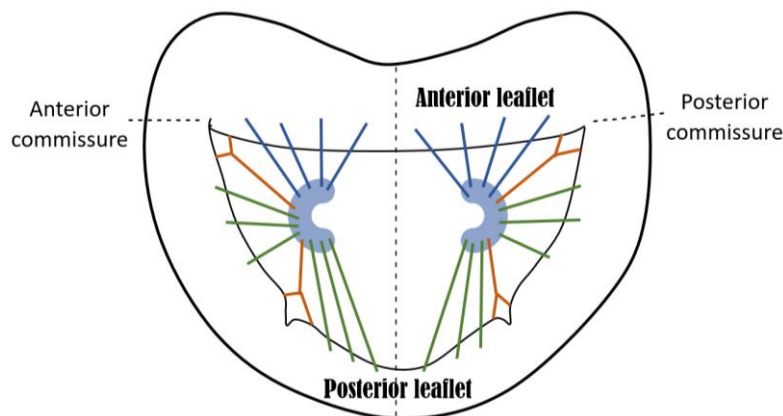


132
133 Figure 10. Distances between PM tips and o'clock points of mitral annulus, in axial (left) and isometric (right) views
134 (adapted from (Sakai et al., 1999, Yamaura, 2008)). Notes: ALPM, anterolateral PM; PMPM, posteromedial PM; 0 o'clock,
135 midpoint of the anterior annular circumference; 2 o'clock, right trigone; 10 o'clock, left trigone; 4 o'clock, separation of
136 posterior and middle scallops of posterior leaflet; 8 o'clock, separation of anterior and middle scallops of posterior leaflet.

137

138 The mathematical description of human chordae tendineae remains challenging, due to the fact that
139 their geometry is of difficult detection through common *in vivo* imaging modalities (Khalighi et al.,
140 2017, Dal-Bianco and Levine, 2013) and meaning that human *ex vivo* studies are the primary sources
141 of knowledge regarding chordal anatomy. Chordae tendineae are distinguished by their morphological
142 diversity in number, insertion points into the leaflets, thickness and branching patterns, as given by
143 previous human *ex vivo* studies (Lam et al., 1970, Gunnal et al., 2015). Regarding human MVs, it is
144 difficult to characterize the exact insertion points of chordae into the leaflets with the current imaging
145 techniques available (Yamaura, 2008), and even the mathematical description of the location of
146 insertion points into the PMs and into the mitral leaflets is based upon assumptions and the expertise
147 of clinicians (Stevanella et al., 2011).

148 In reality, for a human MV model representation, it is common to mathematically simplify the shape
149 of the PMs, as well as chordae insertion patterns: some studies represent the PM tips as unique 3D
150 points where all chordae insert, as previously mentioned (Cochran and Kunzelman, 1998, Stevanella
151 et al., 2009, Prot et al., 2010, Rim et al., 2013); others assume a parabola representing a 2D cut-section
152 of the PM shape, but still where all chordae insert on the tip (Park et al., 2019); and other authors
153 assume them to have a spherical (Stevanella et al., 2011, Wang and Sun, 2013) or C (Choi et al., 2016)
154 shape (schematized in Figure 11) and create different insertion points for the chordae according to their
155 classification.



156
157 Figure 11. Axial view of C-shape representation for the PMs, as present in the literature and suggested by expert surgeons,
158 as well as a simplified depiction of chordae tendineae insertion patterns. Blue, green and orange chordae are those inserting
159 into the anterior leaflet, posterior leaflet and paracommissural zones, respectively.
160

161 Recent studies based on ovine MV have looked into further characterizing chordae tendineae geometry
162 and topology (Khalighi et al., 2017), as well as evaluating how native chordal anatomic characteristics
163 affect valvar performance (Khalighi et al., 2019). Khalighi *et al.* (2017) based their investigation on
164 high-resolution micro-CT derived 3D models, obtaining mathematical descriptions of the chordae such
165 as curve-skeleton characterizations, B-spline parameterizations and Reeb graph representations (see
166 Figure 12). They used the curve-skeleton models to derive bifurcation and non-planarity angles and
167 also analysed the spatial distribution of chordae insertion sites into the leaflets. (Khalighi et al., 2017).
168 Their work yielded valuable information about chordal geometric characterization, including the
169 presence of a non-homogeneous cross-sectional area along each segment (with chordal structure
170 becoming thinner as it gets away from the PM tip); the 2D nature of chordae, which collectively form
171 a 3D load-bearing support structure of the MV leaflets; and the development of analytical statistical
172 models that describe chordae geometry, as well as binary trees, which aid in the prediction of possible
173 shapes for chordal structure (Khalighi et al., 2017). Khalighi *et al.* (2019), on the other hand, found
174 that varying cross-sectional area, branching patterns and PM insertion points at the same origin did not
175 greatly impact in ovine MV performance and described an optimal chordae number range for

176 appropriate function which eliminated over 75% of the native population of chordal insertions
177 (Khalighi et al., 2019). Both studies then shed light on chordae tendineae geometrical characterizations
178 which can possibly be applied to develop human MV models with simplified sub-apparatus structures
179 as a mean to overcome the current issues with in vivo imaging modalities.

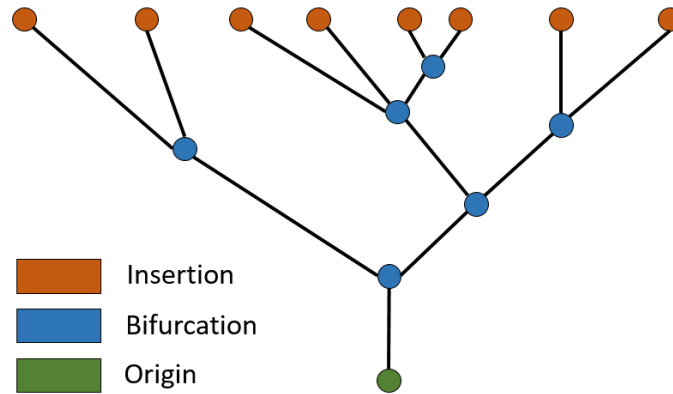


Figure 12. Example of Reeb graph employed to characterize chordae tendineae topology in Khalighi et al. (2017), illustrating the connectivity between branches. Green, blue and orange vertices correspond to chordal origin (at the PM level), bifurcation points and insertion points into the leaflets, respectively.

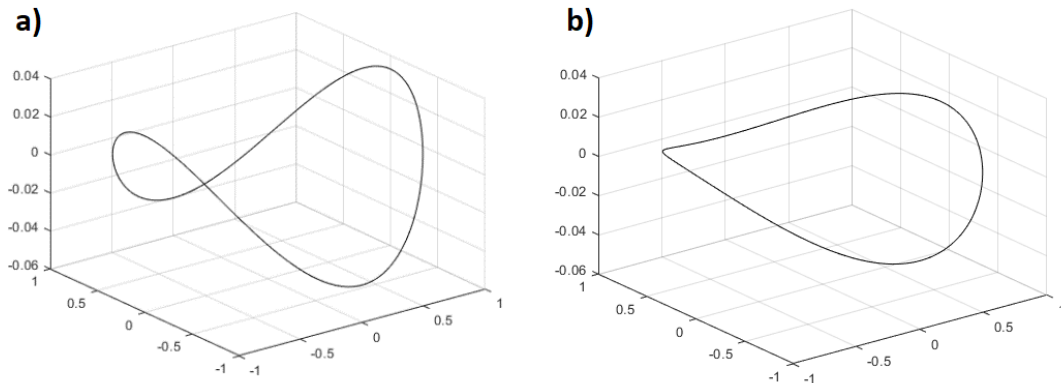
186 4. Changes in mitral valve morphometry: disease

187 4.1 Carpentier's functional classification of MV disease

188 One of the most commonly used classifications of MV disease was designed by Alain Carpentier
189 (Carpentier, 1983), sometimes referred to as the “pathophysiologic triad” (Carpentier et al., 1980). It
190 divides MV dysfunctions in three categories, all of which yield lesions that lead to clinical mitral
191 regurgitation. These categories are based on the position of leaflet margins with respect to the mitral
192 annulus plane: type I refers to normal leaflet motion and is associated with annular dilation and leaflet
193 perforation; type II characterizes excessive leaflet motion, usually derived from elongation or rupture
194 of the chordae tendineae and/or the PM; and type III relates to restricted leaflet motion due to retraction
195 of the subvalvular apparatus (IIIa) or PM displacement and left ventricular dilation, causing apical
196 displacement (tethering) of the PM (IIIb). Further information on this classification and the associated
197 lesions can be found elsewhere (Castillo et al., 2011, Carpentier, 1983, Stone et al., 2015).
198 Mathematical interpretations of this classification were attempted by previous studies, for example
199 representing annular dilation by increasing its diameter or PM displacement by increasing inter-PM
200 distance (Park et al., 2019). Taking this into account and the current literature available, examples of
201 clinical lesions related to MV dysfunctional categories, and their influence in MV geometrical changes,
202 are included in the following sections.

203 4.2 Geometrical changes in the mitral annulus are linked to type I dysfunction

204 In type I dysfunction, the human mitral annulus undergoes structural changes, becoming larger and
 205 flatter and losing its saddle shape (Mihaila, 2013, Lee et al., 2017). A mathematical representation of
 206 this is showed in Figure 13, where the annulus was obtained using dimensions characteristic of annular
 207 dilation, including a lower AHCWR, displayed against a healthy configuration.



208 Figure 13. Hyperboloids representing: a) a mitral annular normal saddle configuration; b) a configuration associated with
 209 type I dysfunction, defined as in Park et al (Park et al., 2019). The first configuration was created with the dimensions
 210 mentioned on Figure 6 and the diseased one upon literature values for CW (42.2 mm), AP diameter (38.8 mm), AL-PM
 211 diameter (39 mm) and AHCWR (0.132).
 212
 213

214 The increase in annular size associated with this type of mitral dysfunction compromises leaflet
 215 coaptation length and therefore prevents proper valve closing (Silbiger, 2011). For example, a previous
 216 *in vitro* study based on porcine MV showed that increasing annular area values (annular dilation) were
 217 associated with a decrease in the pressures needed to cause MV failure (Espino et al., 2007). The
 218 association between the effective regurgitant orifice area (EROA) and MV geometry serves as a
 219 validation of the role played by abnormalities in shape in dysfunctional cases. Concerning the human
 220 MV, increases in this index, linked to greater severity of regurgitation, have been associated with
 221 increasing annular circumference and area at end-systole, although such associations were poorly
 222 correlated ($R^2 = 0.38$, $R^2 = 0.48$, respectively, with p -value < 0.01) (Cong et al., 2018). Lee *et al.*
 223 (2013) have also seen an inverse correlation between EROA and AHCWR at the same time frame,
 224 showing loss of MV saddle shape with increasing regurgitation ($R^2 = 0.44$, p -value < 0.01) (Lee et al.,
 225 2013).

226 Other clinical studies have also correlated an increase in EROA with greater non-coaptation distance
 227 between leaflets (maximal distance between both leaflet edges) at end-systole, as given by equation 30
 228 ($R^2 = 0.68$, p -value < 0.01) (Senechal et al., 2012),

$$\lambda = 0.066 \cdot e^{(0.325 \cdot \mu)}, \quad (30)$$

229 where μ represents the non-coaptation distance (in mm) and λ represents the EROA (in cm^2).

230 *In vivo* human studies show that the flattening in MV shape present in disease is associated with loss
231 of nonplanarity (Silbiger, 2011, Lee et al., 2013), quantified by increased NPAs (Mihaila, 2013), and
232 greater billowing, showed as a correlation between lower AHCWR and higher values of billow volume
233 ($R^2 = 0.66$, p-value < 0.01) obtained at end-systole,

$$234 \quad \text{BV} = 10.000 - 0.792 \cdot \varepsilon + 0.016 \cdot \varepsilon^2, \quad (31)$$

235 where BV represented the billow volume (ml) and ε represents the AHCWR (as a percentage) (Lee et
236 al., 2013).

237 *In vivo* studies have also showed a change in individual measurements describing annular shape in
238 diseased cases: the AP diameter has been shown to increase in regurgitant valves (Lee et al., 2013,
239 Mihaila, 2013), as well as the AL-PM diameter (Mihaila, 2013) and the commissural width (Lee et al.,
240 2013). In addition, greater values of the circularity index are present in cases of regurgitation (Lee et
241 al., 2013), associated with loss of contractility for the MV and a more dominant circular configuration
242 through the cardiac cycle. All these associations show that abnormal human mitral geometry is
243 intrinsically linked to mitral regurgitation (Lee et al., 2013, Mihaila, 2013, Sonne et al., 2009, Dal-
244 Bianco and Levine, 2013).

245 The process of annular dilation differs for anterior and posterior circumferences in the human MV,
246 with the anterior fibrous portion being less prone to dilation (McCarthy et al., 2010). Mathematically,
247 this means that the inter-trigonal distance is not expected to change with mitral annular dilation (Calleja
248 et al., 2015, Suri et al., 2009). The remaining 2/3 of the annulus (posterior annulus) is mainly muscular,
249 dilating more easily (McCarthy et al., 2010). The anterior and posterior leaflet surface areas also
250 increase with mitral regurgitation (Lee et al., 2013, Mihaila, 2013, Dal-Bianco and Levine, 2013,
251 Senechal et al., 2012); however, no apparent trend in dilation concerning anterior vs posterior is present
252 in the literature.

253

254 *4.3 Geometrical changes in the subvalvular apparatus are related to type III dysfunction*

255 Configurational changes of the subvalvular apparatus have a profound impact in MV function. A
256 previous *in vitro* study using porcine specimens assessed the effect of different annulo-papillary
257 lengths in MV coaptation, with different lengths leading to different MV states: not only increased

258 values are associated with damage to the valve, but a shortening in annulo-papillary lengths also
259 induces diseased states (leaflet prolapse) (Espino et al., 2007). An optimum annulo-papillary length is
260 therefore needed for proper MV coaptation. In fact, type III dysfunctions of the MV have been
261 associated with geometrical alterations of the subvalvular apparatus. Clinical studies have shown that
262 the PM suffer displacement in an attempt to attenuate the regurgitation effects (Lee et al., 2013,
263 Silbiger, 2011): this is translated into increased inter-PM distance (Obase et al., 2016, Kim et al., 2014),
264 which has been well correlated with increased regurgitant volume in patients with severe functional
265 ischemic mitral regurgitation, as mathematically described by the equation below for end-systolic data
266 ($R^2 = 0.84$, p-value < 0.01),

$$RV = -36.440 + 1.434 \cdot v, \quad (32)$$

267

268 where RV represents the regurgitant volume (in ml) and v represents the inter-PM distance (in mm)
269 (Jensen et al., 2010).

270 Type III dysfunction is also associated with increased left ventricular dimensions, which cause apical
271 displacement of the PM. This leads to increased annulo-papillary lengths and chordae tendineae
272 elongation (Obase et al., 2016). Previous clinical studies have connected PM displacement with the
273 severity of mitral regurgitation: increased apical displacement of the posteromedial PM (PMPM) was
274 associated with greater regurgitant volume (Jensen et al., 2010) and augmented tethering distance,
275 characteristic of PM displacement, was correlated with increasing mitral regurgitation fraction at mid-
276 systole (equation 33, R^2 stated as 0.64, p-value < 0.01) (Uemura et al., 2005).

$$M_{RF} = -60.990 + 3.583 \cdot TD, \quad (33)$$

277

278 where TD represents the PMPM tethering distance (in mm/m²) and M_{RF} represents the mitral
279 regurgitation fraction (as a percentage).

280 Another clinical study found independent associations between apical displacement of the PMPM and
281 posterior displacement of the AL-PM with increasing tenting area, related to loss of systolic annular
282 function and regurgitation (Yiu et al., 2000). However, the obtained data was too disperse to yield
283 strong correlations amongst these parameters.

284

285

286 **5. Future directions and recommendations for the use of morphometric information in mitral**
287 **valve clinical analysis**

288 This review paper focuses on grouping and briefly outlining the current best knowledge regarding MV
289 morphometry by obtaining data from a range of different sources, including *in vitro*, *in vivo* and *in*
290 *silico* studies. Quantitative data available has been analysed to derive further empirical mathematical
291 relationships between dimensions. These can prove valuable to describe a healthy status of the MV, or
292 can show the association between an abnormal valve shape and cases of dysfunction. It remains
293 challenging to combine the morphometric information available in the literature to produce a coherent
294 morphometric model of the human MV, based on mathematical correlations. Empirical relationships
295 derived from direct correlations between dimensions and any relationships predicted analytically (or
296 mathematically derived shapes) present with inherent differences. In addition, such correlations are
297 derived from a specific imaging time frame, proving difficult to generalize these findings to the entire
298 cardiac cycle.

299 Moreover, the use of different imaging modalities to obtain quantitative measurements, or the
300 employment of different reference points, coordinate systems and anatomical landmarks, may lead to
301 differing ranges for the same dimensions across studies. On the other hand, several imaging modalities
302 present with lack of spatial resolution, therefore becoming difficult to accurately measure valvar
303 dimensions. It also remains challenging to rigorously represent the subvalvular apparatus, as current
304 *in vivo* imaging modalities are unable to properly capture the chordae and PM. These are the motivation
305 behind the use of *ex vivo* data in computational models, as well as complete *ex vivo* animal geometries,
306 which, in combination with micro CT imaging, allow for high resolution detail of all MV components
307 (Khalighi et al., 2017, Khalighi et al., 2018, Bloodworth et al., 2017).

308 Computational modelling has been directed towards the study of MV function: while some studies
309 have focused on normal physiological valve functioning (Domenichini and Pedrizzetti, 2015, Gao et
310 al., 2017a, Votta et al., 2008, Wang and Sun, 2013), others have devoted towards diseased cases (Choi
311 et al., 2016, Rim et al., 2013, Wenk et al., 2010) and surgical procedures (Ge et al., 2014, Rim et al.,
312 2015, Rausch et al., 2017). The first geometrical models were based on idealized shapes of the MV,
313 derived from literature data (Kunzelman et al., 1993, Salgo et al., 2002). However, since the accuracy
314 of MV models is highly sensitive to valve geometry, patient-specific approaches have been preferred,
315 with the MV apparatus being derived from medical images (Rim et al., 2013, Ge et al., 2014).
316 Moreover, studies have devoted towards less invasive methodologies for the determination of mitral
317 tissue properties *in vivo*, including leaflet strains (Rego et al., 2018). Faster and more efficient methods

318 to study MV function are becoming a reality; for example, a recent study has employed a complete
319 human heart model (Baillargeon et al., 2014) to study ventricular dilation, its impact on the MV
320 structure and its repair through annuloplasty (Rausch et al., 2017). This demonstrates the great
321 potential of computational simulations to optimize medical intervention, develop tailored device
322 designs and aid in treatment management. The use of a more complete set of morphometric information
323 on the MV, such as the one described in this paper, may aid in this endeavour, which can then be useful
324 to study the biomechanics associated with specific valvar shapes, in healthy and diseased ranges.

325

326 **Declarations of interest:** none

327

328 **Ethics**

329 The data obtained by the authors belongs to healthy volunteers recruited under the ethically approved
330 research study “Exercise Capacity in Adults” with REC reference 13/NS/0034 and IRAS ID 127501.

331

332 **Financial support**

333 The creation of the database employed on our study was sponsored by the University of Aberdeen,
334 under the research study “Exercise Capacity in Adults”.

335

336 **Authors’ contributions**

337 All authors were involved in the design of the study and have critically revised the manuscript.
338 Individual contributions are as below:

339 Miss Diana Oliveira: Initial draft of the manuscript; gathering of morphometric mitral valve
340 information from the current literature, for healthy and diseased cases; statistical analysis with
341 published data; acquisition of mitral valve anatomic data and respective data analysis.

342 Dr Janaki Srinivasan: Acquisition of mitral valve anatomic data.

343 Dr Dana Dawson: Clinical guidance; recommendation of the clinical database to employ and decision
344 on the sample to use.

345 Dr Keith Buchan: Surgical guidance; determination of relevant morphometric aspects of the mitral
346 valve, including anatomic arrangements from the surgical point of view; advice on image sketches for
347 the manuscript.

348 Dr Daniel Espino: Guidance on organization and presentation of information and data.

349 Prof Duncan Shepherd: Guidance on organization and presentation of information and data.

350

351 **References**

352 AL-ATABI, M., ESPINO, D. M., HUKINS, D. W. & BUCHAN, K. G. 2012. Biomechanical
353 assessment of surgical repair of the mitral valve. *Proc Inst Mech Eng H*, 226, 275-87.

354 BAILLARGEON, B., REBELO, N., FOX, D. D., TAYLOR, R. L. & KUHL, E. 2014. The Living
355 Heart Project: A robust and integrative simulator for human heart function. *Eur J Mech A*
356 *Solids*, 48, 38-47.

357 BLOODWORTH, C. H. T., PIERCE, E. L., EASLEY, T. F., DRACH, A., KHALIGHI, A. H., TOMA,
358 M., JENSEN, M. O., SACKS, M. S. & YOGANATHAN, A. P. 2017. Ex Vivo Methods for
359 Informing Computational Models of the Mitral Valve. *Ann Biomed Eng*, 45, 496-507.

360 BOUMA, W. & GORMAN, R. C. 2019. Commentary: Three-dimensional P3 tethering angle at the
361 heart of future surgical decision making in ischemic mitral regurgitation. *Journal of Thoracic*
362 *and Cardiovascular Surgery*, 157, 1806-1807.

363 CALLEJA, A., POULIN, F., WOO, A., MEINER, M., JEDRZKIEWICZ, S., VANNAN, M. A.,
364 RAKOWSKI, H., DAVID, T., TSANG, W. & THAVENDIRANATHAN, P. 2015.
365 Quantitative Modeling of the Mitral Valve by Three-Dimensional Transesophageal
366 Echocardiography in Patients Undergoing Mitral Valve Repair: Correlation with Intraoperative
367 Surgical Technique. *J Am Soc Echocardiogr*, 28, 1083-92.

368 CARPENTIER, A. 1983. Cardiac valve surgery--the "French correction". *J Thorac Cardiovasc Surg*,
369 86, 323-37.

370 CARPENTIER, A., CHAUVAUD, S., FABIANI, J. N., DELOCHE, A., RELAND, J., LESSANA,
371 A., D'ALLAINES, C., BLONDEAU, P., PIWNICA, A. & DUBOST, C. 1980. Reconstructive
372 surgery of mitral valve incompetence: ten-year appraisal. *J Thorac Cardiovasc Surg*, 79, 338-
373 48.

374 CARPENTIER, A. F., LESSANA, A., RELAND, J. Y., BELLI, E., MIHAILEANU, S., BERREBI,
375 A. J., PALSKEY, E. & LOULMET, D. F. 1995. The "physio-ring": an advanced concept in
376 mitral valve annuloplasty. *Ann Thorac Surg*, 60, 1177-85; discussion 1185-6.

377 CASTILLO, J. G., SOLIS, J., GONZALEZ-PINTO, A. & ADAMS, D. H. 2011. [Surgical
378 echocardiography of the mitral valve]. *Rev Esp Cardiol*, 64, 1169-81.

379 CHOI, A., MCPHERSON, D. D. & KIM, H. 2016. Biomechanical evaluation of the pathophysiologic
380 developmental mechanisms of mitral valve prolapse: effect of valvular morphologic alteration.
381 *Med Biol Eng Comput*, 54, 799-809.

382 CIARKA, A., BRAUN, J., DELGADO, V., VERSTEEGH, M., BOERSMA, E., KLAUTZ, R., DION,
383 R., BAX, J. J. & VAN DE VEIRE, N. 2010. Predictors of mitral regurgitation recurrence in
384 patients with heart failure undergoing mitral valve annuloplasty. *Am J Cardiol*, 106, 395-401.

385 COCHRAN, R. P. & KUNZELMAN, K. S. 1998. Effect of papillary muscle position on mitral valve
386 function: relationship to homografts. *Ann Thorac Surg*, 66, S155-61.

387 CONG, T., GU, J., LEE, A. P., SHANG, Z., SUN, Y., SUN, Q., WEI, H., CHEN, N., SUN, S. & FU,
388 T. 2018. Quantitative analysis of mitral valve morphology in atrial functional mitral

389 regurgitation using real-time 3-dimensional echocardiography atrial functional mitral
390 regurgitation. *Cardiovasc Ultrasound*, 16, 13.

391 DAL-BIANCO, J. P. & LEVINE, R. A. 2013. Anatomy of the mitral valve apparatus: role of 2D and
392 3D echocardiography. *Cardiol Clin*, 31, 151-64.

393 DELGADO, V., TOPS, L. F., SCHUIJF, J. D., DE ROOS, A., BRUGADA, J., SCHALIJ, M. J.,
394 THOMAS, J. D. & BAX, J. J. 2009. Assessment of mitral valve anatomy and geometry with
395 multislice computed tomography. *JACC Cardiovasc Imaging*, 2, 556-65.

396 DEORSOLA, L. & BELLONE, A. 2018. Coaptation Triangle and Golden Proportion in mitral valve
397 anatomy. Does nature play with geometry? *Echocardiography*, 35, 30-38.

398 DOMENICHINI, F. & PEDRIZZETTI, G. 2015. Asymptotic Model of Fluid-Tissue Interaction for
399 Mitral Valve Dynamics. *Cardiovasc Eng Technol*, 6, 95-104.

400 DUDZINSKI, D. M. & HUNG, J. 2014. Echocardiographic assessment of ischemic mitral
401 regurgitation. *Cardiovasc Ultrasound*, 12, 46.

402 DUPLESSIS, L. A. & MARCHAND, P. 1964. The Anatomy of the Mitral Valve and Its Associated
403 Structures. *Thorax*, 19, 221-7.

404 ECKERT, C. E., ZUBIATE, B., VERGNAT, M., GORMAN, J. H., 3RD, GORMAN, R. C. & SACKS,
405 M. S. 2009. In vivo dynamic deformation of the mitral valve annulus. *Ann Biomed Eng*, 37,
406 1757-71.

407 ESPINO, D. M., SHEPHERD, D. E. & BUCHAN, K. G. 2007. Effect of mitral valve geometry on
408 valve competence. *Heart Vessels*, 22, 109-15.

409 ESPINO, D. M., SHEPHERD, D. E., HUKINS, D. W. & BUCHAN, K. G. 2005. The role of Chordae
410 tendineae in mitral valve competence. *J Heart Valve Dis*, 14, 603-9.

411 GAO, H., FENG, L., QI, N., BERRY, C., GRIFFITH, B. E. & LUO, X. 2017a. A coupled mitral valve-
412 left ventricle model with fluid-structure interaction. *Med Eng Phys*, 47, 128-136.

413 GAO, H., QI, N., FENG, L., MA, X., DANTON, M., BERRY, C. & LUO, X. 2017b. Modelling mitral
414 valvular dynamics-current trend and future directions. *Int J Numer Method Biomed Eng*, 33.

415 GARBI, M. & MONAGHAN, M. J. 2015. Quantitative mitral valve anatomy and pathology. *Echo Res
416 Pract*, 2, R63-72.

417 GE, L., MORREL, W. G., WARD, A., MISHRA, R., ZHANG, Z., GUCCIONE, J. M., GROSSI, E.
418 A. & RATCLIFFE, M. B. 2014. Measurement of mitral leaflet and annular geometry and stress
419 after repair of posterior leaflet prolapse: virtual repair using a patient-specific finite element
420 simulation. *Ann Thorac Surg*, 97, 1496-503.

421 GRBIC, S., EASLEY, T. F., MANSI, T., BLOODWORTH, C. H., PIERCE, E. L., VOIGT, I.,
422 NEUMANN, D., KREBS, J., YUH, D. D., JENSEN, M. O., COMANICIU, D. &
423 YOGANATHAN, A. P. 2017. Personalized mitral valve closure computation and uncertainty
424 analysis from 3D echocardiography. *Med Image Anal*, 35, 238-249.

425 GUNNAL, S. A., WABALE, R. N. & FAROOQUI, M. S. 2015. Morphological study of chordae
426 tendinae in human cadaveric hearts. *Heart Views*, 16, 1-12.

427 HIRAKAWA, S., SASAYAMA, S., TOMOIKE, H., CROZATIER, B., FRANKLIN, D., MCKOWN,
428 D. & ROSS, J., JR. 1977. In situ measurement of papillary muscle dynamics in the dog left
429 ventricle. *Am J Physiol*, 233, H384-91.

430 IONASEC, R. I., VOIGT, I., GEORGESCU, B., WANG, Y., HOULE, H., VEGA-HIGUERA, F.,
431 NAVAB, N. & COMANICIU, D. 2010. Patient-specific modeling and quantification of the
432 aortic and mitral valves from 4-D cardiac CT and TEE. *IEEE Trans Med Imaging*, 29, 1636-
433 51.

434 JASSAR, A. S., VERGNAT, M., JACKSON, B. M., MCGARVEY, J. R., CHEUNG, A. T.,
435 FERRARI, G., WOO, Y. J., ACKER, M. A., GORMAN, R. C. & GORMAN, J. H. 2014.
436 Regional Annular Geometry in Patients With Mitral Regurgitation: Implications for
437 Annuloplasty Ring Selection. *Annals of Thoracic Surgery*, 97, 64-70.

438 JENSEN, H., JENSEN, M. O., SMERUP, M. H., RINGGAARD, S., SORENSEN, T. S., ANDERSEN,
439 N. T., WIERUP, P., HASENKAM, J. M. & NIELSEN, S. L. 2010. Three-dimensional
440 assessment of papillary muscle displacement in a porcine model of ischemic mitral
441 regurgitation. *J Thorac Cardiovasc Surg*, 140, 1312-8.

442 JIANG, L., OWAIS, K., MATYAL, R., KHABBAZ, K. R., LIU, D. C., MONTEALEGRE-
443 GALLEGOS, M., HESS, P. E. & MAHMOOD, F. 2014. Dynamism of the mitral annulus: a
444 spatial and temporal analysis. *J Cardiothorac Vasc Anesth*, 28, 1191-7.

445 JIMENEZ, J. H., LIU, S. W., PADALA, M., HE, Z., SACKS, M., GORMAN, R. C., GORMAN, J.
446 H., 3RD & YOGANATHAN, A. P. 2007. A saddle-shaped annulus reduces systolic strain on
447 the central region of the mitral valve anterior leaflet. *J Thorac Cardiovasc Surg*, 134, 1562-8.

448 JOLLEY, M. A., GHELANI, S. J., ADAR, A. & HARRILD, D. M. 2017. Three-Dimensional Mitral
449 Valve Morphology and Age-Related Trends in Children and Young Adults with Structurally
450 Normal Hearts Using Transthoracic Echocardiography. *J Am Soc Echocardiogr*, 30, 561-571.

451 KAISER, A. D., MCQUEEN, D. M. & PESKIN, C. S. 2019. Modeling the mitral valve. *Int J Numer*
452 *Method Biomed Eng*, e3240.

453 KHALIGHI, A. H., DRACH, A., BLOODWORTH, C. H. T., PIERCE, E. L., YOGANATHAN, A.
454 P., GORMAN, R. C., GORMAN, J. H., 3RD & SACKS, M. S. 2017. Mitral Valve Chordae
455 Tendineae: Topological and Geometrical Characterization. *Ann Biomed Eng*, 45, 378-393.

456 KHALIGHI, A. H., DRACH, A., GORMAN, R. C., GORMAN, J. H., 3RD & SACKS, M. S. 2018.
457 Multi-resolution geometric modeling of the mitral heart valve leaflets. *Biomech Model*
458 *Mechanobiol*, 17, 351-366.

459 KHALIGHI, A. H., REGO, B. V., DRACH, A., GORMAN, R. C., GORMAN, J. H., 3RD & SACKS,
460 M. S. 2019. Development of a Functionally Equivalent Model of the Mitral Valve Chordae
461 Tendineae Through Topology Optimization. *Ann Biomed Eng*, 47, 60-74.

462 KIM, K., KAJI, S., AN, Y., NISHINO, T., TANI, T., KITAI, T. & FURUKAWA, Y. 2014.
463 Interpapillary muscle distance independently affects severity of functional mitral regurgitation
464 in patients with systolic left ventricular dysfunction. *J Thorac Cardiovasc Surg*, 148, 434-40
465 e1.

466 KUNZELMAN, K. S., COCHRAN, R. P., CHUONG, C., RING, W. S., VERRIER, E. D. &
467 EBERHART, R. D. 1993. Finite element analysis of the mitral valve. *J Heart Valve Dis*, 2,
468 326-40.

469 KUNZELMAN, K. S., COCHRAN, R. P., VERRIER, E. D. & EBERHART, R. C. 1994. Anatomic
470 basis for mitral valve modelling. *J Heart Valve Dis*, 3, 491-6.

471 KUNZELMAN, K. S., EINSTEIN, D. R. & COCHRAN, R. P. 2007. Fluid-structure interaction
472 models of the mitral valve: function in normal and pathological states. *Philos Trans R Soc Lond*
473 *B Biol Sci*, 362, 1393-406.

474 LAM, J. H., RANGANATHAN, N., WIGLE, E. D. & SILVER, M. D. 1970. Morphology of the human
475 mitral valve. I. Chordae tendineae: a new classification. *Circulation*, 41, 449-58.

476 LEE, A. P., HSIUNG, M. C., SALGO, I. S., FANG, F., XIE, J. M., ZHANG, Y. C., LIN, Q. S., LOOI,
477 J. L., WAN, S., WONG, R. H., UNDERWOOD, M. J., SUN, J. P., YIN, W. H., WEI, J., TSAI,
478 S. K. & YU, C. M. 2013. Quantitative analysis of mitral valve morphology in mitral valve
479 prolapse with real-time 3-dimensional echocardiography: importance of annular saddle shape
480 in the pathogenesis of mitral regurgitation. *Circulation*, 127, 832-41.

481 LEE, A. P., JIN, C. N., FAN, Y., WONG, R. H. L., UNDERWOOD, M. J. & WAN, S. 2017.
482 Functional Implication of Mitral Annular Disjunction in Mitral Valve Prolapse: A Quantitative
483 Dynamic 3D Echocardiographic Study. *JACC Cardiovasc Imaging*, 10, 1424-1433.

484 LEVACK, M. M., JASSAR, A. S., SHANG, E. K., VERGNAT, M., WOO, Y. J., ACKER, M. A.,
485 JACKSON, B. M., GORMAN, J. H., 3RD & GORMAN, R. C. 2012. Three-dimensional
486 echocardiographic analysis of mitral annular dynamics: implication for annuloplasty selection.
487 *Circulation*, 126, S183-8.

488 LOMHOLT, M., NIELSEN, S. L., HANSEN, S. B., ANDERSEN, N. T. & HASENKAM, J. M. 2002.
489 Differential tension between secondary and primary mitral chordae in an acute in-vivo porcine
490 model. *Journal of Heart Valve Disease*, 11, 337-345.

491 MACHINO-OHTSUKA, T., SEO, Y., ISHIZU, T., SATO, K., SUGANO, A., YAMAMOTO, M.,
492 HAMADA-HARIMURA, Y. & AONUMA, K. 2016. Novel Mechanistic Insights Into Atrial
493 Functional Mitral Regurgitation-3-Dimensional Echocardiographic Study. *Circulation*
494 *Journal*, 80, 2240-2248.

495 MANSI, T., VOIGT, I., GEORGESCU, B., ZHENG, X., MENGUE, E. A., HACKL, M., IONASEC,
496 R. I., NOACK, T., SEEBURGER, J. & COMANICIU, D. 2012. An integrated framework for
497 finite-element modeling of mitral valve biomechanics from medical images: application to
498 MitralClip intervention planning. *Med Image Anal*, 16, 1330-46.

499 MARZILLI, M., SABBAH, H. N., LEE, T. & STEIN, P. D. 1980. Role of the papillary muscle in
500 opening and closure of the mitral valve. *Am J Physiol*, 238, H348-54.

501 MCCARTHY, K. P., RING, L. & RANA, B. S. 2010. Anatomy of the mitral valve: understanding the
502 mitral valve complex in mitral regurgitation. *Eur J Echocardiogr*, 11, i3-9.

503 MIHAILA, S., MURARU, D., CASABLANA, S., PELUSO, D., CUCCHINI, U., DEL BIANCO, L.,
504 VINERANU, D., ILICETO, S., BADANO, L. 2013. Three-dimensional changes in mitral
505 valve annulus geometry in organic and functional mitral regurgitation: insights for mitral valve
506 repair. *Eur. Heart J.*, 34, 4751.

507 NIELSEN, S. L., TIMEK, T. A., GREEN, G. R., DAGUM, P., DAUGHTERS, G. T., HASENKAM,
508 J. M., BOLGER, A. F., INGELS, N. B. & MILLER, D. C. 2003. Influence of anterior mitral
509 leaflet second-order chordae tendineae on left ventricular systolic function. *Circulation*, 108,
510 486-491.

511 OBASE, K., WEINERT, L., HOLLATZ, A., FAROOQUI, F., ROBERTS, J. D., MINHAI, M. M.,
512 TUNG, A., CHANEY, M., OTA, T., JEEVANANDAM, V., YOSHIDA, K., MOR-AVI, V. &
513 LANG, R. M. 2016. Elongation of chordae tendineae as an adaptive process to reduce mitral
514 regurgitation in functional mitral regurgitation. *Eur Heart J Cardiovasc Imaging*, 17, 500-9.

515 OKAMOTO, H., ITOH, Y. & NARA, Y. 2007. Geometric analysis of the anterior mitral leaflet and
516 mitral valve orifice in cadaveric hearts. *Circ J*, 71, 1794-9.

517 OWAIS, K., MONTEALEGRE-GALLEGOS, M., JEGANATHAN, J., MATYAL, R., KHABBAZ,
518 K. R. & MAHMOOD, F. 2016. Dynamic changes in the ischemic mitral annulus: Implications
519 for ring sizing. *Ann Card Anaesth*, 19, 15-9.

520 PADALA, M., SACKS, M. S., LIOU, S. W., BALACHANDRAN, K., HE, Z. & YOGANATHAN,
521 A. P. 2010. Mechanics of the mitral valve strut chordae insertion region. *J Biomech Eng*, 132,
522 081004.

523 PARK, J., GEIRSSON, A. & BONDE, P. N. 2019. Mathematical Blueprint of a Mitral Valve. *Semin*
524 *Thorac Cardiovasc Surg*.

525 POUCH, A. M., VERGNAT, M., MCGARVEY, J. R., FERRARI, G., JACKSON, B. M., SEHGAL,
526 C. M., YUSHKEVICH, P. A., GORMAN, R. C. & GORMAN, J. H. 2014. Statistical
527 Assessment of Normal Mitral Annular Geometry Using Automated Three-Dimensional
528 Echocardiographic Analysis. *Annals of Thoracic Surgery*, 97, 71-77.

529 PROT, V., SKALLERUD, B., SOMMER, G. & HOLZAPFEL, G. A. 2010. On modelling and analysis
530 of healthy and pathological human mitral valves: two case studies. *J Mech Behav Biomed*
531 *Mater*, 3, 167-77.

532 RANGANATHAN, N., LAM, J. H., WIGLE, E. D. & SILVER, M. D. 1970. Morphology of the human
533 mitral valve. II. The valve leaflets. *Circulation*, 41, 459-67.

534 RAUSCH, M. K., BOTHE, W., KVVITTING, J. P., SWANSON, J. C., INGELS, N. B., JR., MILLER,
535 D. C. & KUHL, E. 2011. Characterization of mitral valve annular dynamics in the beating
536 heart. *Ann Biomed Eng*, 39, 1690-702.

537 RAUSCH, M. K., ZOLLNER, A. M., GENET, M., BAILLARGEON, B., BOTHE, W. & KUHL, E.
538 2017. A virtual sizing tool for mitral valve annuloplasty. *Int J Numer Method Biomed Eng*, 33.
539 REGO, B. V., KHALIGHI, A. H., DRACH, A., LAI, E. K., POUCH, A. M., GORMAN, R. C.,
540 GORMAN, J. H., 3RD & SACKS, M. S. 2018. A noninvasive method for the determination of
541 in vivo mitral valve leaflet strains. *Int J Numer Method Biomed Eng*, 34, e3142.
542 RIM, Y., CHOI, A., MCPHERSON, D. D. & KIM, H. 2015. Personalized Computational Modeling
543 of Mitral Valve Prolapse: Virtual Leaflet Resection. *PLoS One*, 10, e0130906.
544 RIM, Y., MCPHERSON, D. D., CHANDRAN, K. B. & KIM, H. 2013. The effect of patient-specific
545 annular motion on dynamic simulation of mitral valve function. *J Biomech*, 46, 1104-12.
546 SAHA, A. & ROY, S. 2018. Papillary muscles of left ventricle-Morphological variations and its
547 clinical relevance. *Indian Heart J*, 70, 894-900.
548 SAKAI, T., OKITA, Y., UEDA, Y., TAHATA, T., OGINO, H., MATSUYAMA, K. & MIKI, S. 1999.
549 Distance between mitral anulus and papillary muscles: anatomic study in normal human hearts.
550 *J Thorac Cardiovasc Surg*, 118, 636-41.
551 SALGO, I. S., GORMAN, J. H., 3RD, GORMAN, R. C., JACKSON, B. M., BOWEN, F. W.,
552 PLAPPERT, T., ST JOHN SUTTON, M. G. & EDMUNDS, L. H., JR. 2002. Effect of annular
553 shape on leaflet curvature in reducing mitral leaflet stress. *Circulation*, 106, 711-7.
554 SEDRANSK, K. L., GRANDE-ALLEN, K. J. & VESELY, I. 2002. Failure mechanics of mitral valve
555 chordae tendineae. *J Heart Valve Dis*, 11, 644-50.
556 SENECHAL, M., MICHAUD, N., MACHAALANY, J., BERNIER, M., DUBOIS, M., MAGNE, J.,
557 COUTURE, C., MATHIEU, P., BERTRAND, O. F. & VOISINE, P. 2012. Relation of mitral
558 valve morphology and motion to mitral regurgitation severity in patients with mitral valve
559 prolapse. *Cardiovasc Ultrasound*, 10, 3.
560 SHEN, X., WANG, T., CAO, X. & CAI, L. 2017. The geometric model of the human mitral valve.
561 *PLoS One*, 12, e0183362.
562 SILBIGER, J. J. 2011. Mechanistic insights into ischemic mitral regurgitation: echocardiographic and
563 surgical implications. *J Am Soc Echocardiogr*, 24, 707-19.
564 SONNE, C., SUGENG, L., WATANABE, N., WEINERT, L., SAITO, K., TSUKIJI, M., YOSHIDA,
565 K., TAKEUCHI, M., MOR-AVI, V. & LANG, R. M. 2009. Age and body surface area
566 dependency of mitral valve and papillary apparatus parameters: assessment by real-time three-
567 dimensional echocardiography. *Eur J Echocardiogr*, 10, 287-94.
568 STEPHENS, S. E., LIACHENKO, S., INGELS, N. B., WENK, J. F. & JENSEN, M. O. 2017. High
569 resolution imaging of the mitral valve in the natural state with 7 Tesla MRI. *Plos One*, 12.
570 STEVANELLA, M., MAFFESSANTI, F., CONTI, C. A., VOTTA, E., ARNOLDI, A., LOMBARDI,
571 M., PARODI, O., CAIANI, E. G. & REDAELLI, A. 2011. Mitral Valve Patient-Specific Finite
572 Element Modeling from Cardiac MRI: Application to an Annuloplasty Procedure.
573 *Cardiovascular Engineering and Technology*, 2, 66-76.
574 STEVANELLA, M., VOTTA, E. & REDAELLI, A. 2009. Mitral valve finite element modeling:
575 implications of tissues' nonlinear response and annular motion. *J Biomech Eng*, 131, 121010.
576 STONE, G. W., VAHANIAN, A. S., ADAMS, D. H., ABRAHAM, W. T., BORER, J. S., BAX, J. J.,
577 SCHOFER, J., CUTLIP, D. E., KRUCOFF, M. W., BLACKSTONE, E. H., GENEREUX, P.,
578 MACK, M. J., SIEGEL, R. J., GRAYBURN, P. A., ENRIQUEZ-SARANO, M.,
579 LANCELLOTTI, P., FILIPPATOS, G., KAPPETEIN, A. P. & MITRAL VALVE
580 ACADEMIC RESEARCH, C. 2015. Clinical Trial Design Principles and Endpoint Definitions
581 for Transcatheter Mitral Valve Repair and Replacement: Part 1: Clinical Trial Design
582 Principles: A Consensus Document From the Mitral Valve Academic Research Consortium. *J*
583 *Am Coll Cardiol*, 66, 278-307.
584 SUN, X., JIANG, Y., HUANG, G., HUANG, J., SHI, M., PANG, L. & WANG, Y. 2019. Three-
585 dimensional mitral valve structure in predicting moderate ischemic mitral regurgitation

586 improvement after coronary artery bypass grafting. *J Thorac Cardiovasc Surg*, 157, 1795-1803
587 e2.

588 SURI, R. M., GREWAL, J., MANKAD, S., ENRIQUEZ-SARANO, M., MILLER, F. A., JR. &
589 SCHAFF, H. V. 2009. Is the anterior intertrigonal distance increased in patients with mitral
590 regurgitation due to leaflet prolapse? *Ann Thorac Surg*, 88, 1202-8.

591 TANG, Z., FAN, Y. T., WANG, Y., JIN, C. N., KWOK, K. W. & LEE, A. P. 2019. Mitral Annular
592 and Left Ventricular Dynamics in Atrial Functional Mitral Regurgitation: A Three-
593 Dimensional and Speckle-Tracking Echocardiographic Study. *J Am Soc Echocardiogr*, 32,
594 503-513.

595 TIMEK, T. A., NIELSEN, S. L., GREEN, G. R., DAGUM, P., BOLGER, A. F., DAUGHTERS, G.
596 T., HASENKAM, J. M., INGELS, N. B. & MILLER, D. C. 2001. Influence of anterior mitral
597 leaflet second-order chordae on leaflet dynamics and valve competence. *Annals of Thoracic
598 Surgery*, 72, 535-540.

599 TOPILSKY, Y., VATURI, O., WATANABE, N., BICHARA, V., NKOMO, V. T., MICHELENA,
600 H., LE TOURNEAU, T., MANKAD, S. V., PARK, S., CAPPS, M. A., SURI, R., PISLARU,
601 S. V., MAALOUF, J., YOSHIDA, K. & ENRIQUEZ-SARANO, M. 2013. Real-time 3-
602 dimensional dynamics of functional mitral regurgitation: a prospective quantitative and
603 mechanistic study. *J Am Heart Assoc*, 2, e000039.

604 UEMURA, T., OTSUJI, Y., NAKASHIKI, K., YOSHIFUKU, S., MAKI, Y., YU, B., MIZUKAMI,
605 N., KUWAHARA, E., HAMASAKI, S., BIRO, S., KISANUKI, A., MINAGOE, S., LEVINE,
606 R. A. & TEI, C. 2005. Papillary muscle dysfunction attenuates ischemic mitral regurgitation in
607 patients with localized basal inferior left ventricular remodeling: insights from tissue Doppler
608 strain imaging. *J Am Coll Cardiol*, 46, 113-9.

609 VERONESI, F., CORSI, C., SUGENG, L., MOR-AVI, V., CAIANI, E. G., WEINERT, L.,
610 LAMBERTI, C. & LANG, R. M. 2009. A study of functional anatomy of aortic-mitral valve
611 coupling using 3D matrix transesophageal echocardiography. *Circ Cardiovasc Imaging*, 2, 24-
612 31.

613 VOTTA, E., CAIANI, E., VERONESI, F., SONCINI, M., MONTEVECCHI, F. M. & REDAELLI,
614 A. 2008. Mitral valve finite-element modelling from ultrasound data: a pilot study for a new
615 approach to understand mitral function and clinical scenarios. *Philos Trans A Math Phys Eng
616 Sci*, 366, 3411-34.

617 WANG, Q. & SUN, W. 2013. Finite element modeling of mitral valve dynamic deformation using
618 patient-specific multi-slices computed tomography scans. *Ann Biomed Eng*, 41, 142-53.

619 WARRAICH, H. J., CHAUDARY, B., MASLOW, A., PANZICA, P. J., PUGSLEY, J. &
620 MAHMOOD, F. 2012. Mitral annular nonplanarity: correlation between annular
621 height/commissural width ratio and the nonplanarity angle. *J Cardiothorac Vasc Anesth*, 26,
622 186-90.

623 WENK, J. F., ZHANG, Z., CHENG, G., MALHOTRA, D., ACEVEDO-BOLTON, G., BURGER, M.,
624 SUZUKI, T., SALONER, D. A., WALLACE, A. W., GUCCIONE, J. M. & RATCLIFFE, M.
625 B. 2010. First finite element model of the left ventricle with mitral valve: insights into ischemic
626 mitral regurgitation. *Ann Thorac Surg*, 89, 1546-53.

627 WILCOX, A. G., BUCHAN, K. G. & ESPINO, D. M. 2014. Frequency and diameter dependent
628 viscoelastic properties of mitral valve chordae tendineae. *J Mech Behav Biomed Mater*, 30,
629 186-95.

630 YAMAURA, Y., ET AL. 2008. Three-Dimensional Echocardiographic Measurements of Distance
631 Between Papillary Muscles and Mitral Annulus: Assessment With Three-Dimensional
632 Quantification Software System. *J Echocardiogr*, 6, 67-73.

633 YIU, S. F., ENRIQUEZ-SARANO, M., TRIBOUILLOY, C., SEWARD, J. B. & TAJIK, A. J. 2000.
634 Determinants of the degree of functional mitral regurgitation in patients with systolic left
635 ventricular dysfunction: A quantitative clinical study. *Circulation*, 102, 1400-6.

636 ZHANG, F., KANIK, J., MANSI, T., VOIGT, I., SHARMA, P., IONASEC, R. I.,
637 SUBRAHMANYAN, L., LIN, B. A., SUGENG, L., YUH, D., COMANICIU, D. & DUNCAN,
638 J. 2017. Towards patient-specific modeling of mitral valve repair: 3D transesophageal
639 echocardiography-derived parameter estimation. *Med Image Anal*, 35, 599-609.

640

641

642

643

644

645

646

647

648

649

650

651

652

653

654

655

656

657

658

659

660

661

662

663

664

665

666

667

668 **Supplementary Information:**

669

670 *1. Complete list of abbreviations and symbols used in equations*

671

672 Table A

Abbreviation	Meaning
MV	Mitral valve
PM	Papillary muscle
3D	Three-dimensional
2D	Two-dimensional
AP	Antero-posterior
AL-PM	Anterolateral-posteromedial
A_C	Total annular circumference
A_{AC}	Anterior annular circumference
P_{AC}	Posterior annular circumference
AH	Annular height
IT	Inter-trigonal distance
AHCWR	Annular height to commissural width ratio
CI	Circularity index
CW	Commissural width
NPA	Non-planarity angle
A_{na}	2D annular area
A_{cord}	Anterior cord
P_{cord}	Posterior cord
A_{LA}	Anterior leaflet surface area
P_{LA}	Posterior leaflet surface area
EROA	Effective regurgitant orifice area
BV	Billow volume
RV	Regurgitant volume
M_{FR}	Mitral regurgitant fraction
TD	Tethering distance

673

674 Table B

Symbol	Mitral valve variable
γ	AL-PM distance
δ	Free edge length
ϵ	AHCWR
σ	AH to the AL-PM ratio
τ	AH to the AP ratio
λ	EROA
μ	Non-coaptation distance
υ	Inter-PM distance

2. Methodology employed for derivation of prediction equations for mitral valve morphometry

675
676

677 Aim: To perform linear and nonlinear regression analyses with published and obtained human
678 anatomical data in order to generate prediction equations for several mitral valve geometrical
679 parameters.

680

681 Steps taken:

682 Minitab 19 was employed for all regression analysis. Least-squares estimation was used to find
683 equations describing the relationship between two valve parameters at the time, with each data point
684 representing the value associated with one patient. This involved fitting different regression models to
685 the data, using the order presented in Table C (C_1 , C_2 and C_3 are generic equation coefficients), and
686 evaluating the correlation coefficient R^2 . This fitting process continued until the next fitting model did
687 not significantly increase the R^2 . $R^2 < 0.5$ was associated with a poor correlation, $0.5 < R^2 < 0.8$ was
688 associated with a moderate correlation and $R^2 > 0.8$ was associated with a good correlation.

689

690 Table C

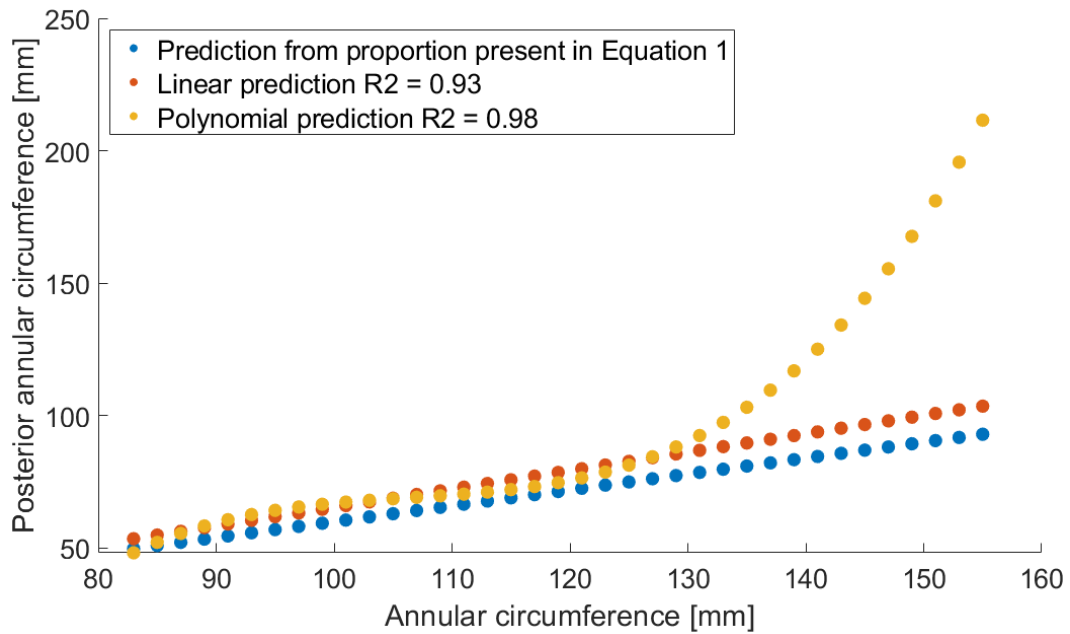
Regression model	Equation form
Linear	$y = C_1 + C_2x$
Logarithmic	$y = C_1 + C_2 \ln x$
Exponential	$y = C_1 e^{C_2x}$
Polynomial	$y = C_1 + C_2x + C_3x^2$

691

692 An analysis of variance to select an equation from the generated set was performed. This was not only
693 based on quality of fit, but also on the physical meaning of the prediction equations. This meant that
694 the values generated by each equation were compared to the clinical range and the standard-deviation
695 from literature data for validity. Therefore, high values of R^2 associated with a P-value < 0.01 , together
696 with sensible 95% prediction intervals and consistent with the clinical ranges, indicated the equation
697 with best-fitting that could provide the best approximation to the data. When R^2 proved similar
698 amongst predictions, the simplest fit was chosen.

699 An example of the analysis of the physical meaning of prediction equations is explained below for
700 Equation 4 (P_{AC} predicted from A_C). During the generation of this equation, two models of best fit
701 were had into account: the linear regression ($R^2 = 0.93$, p-value < 0.01) and a 3rd degree polynomial
702 ($R^2 = 0.98$, p-value < 0.01). Both equations were tested with randomly generated values for the A_C

703 based on the standard-deviation from literature data and compared against the values obtained from
704 the proportion found in the literature and present in Equation 1 of this manuscript (Figure A1).



705
706 Figure A1. Linear ($R^2 = 0.93$, p -value < 0.01) and non-linear ($R^2 = 0.98$, p -value < 0.01) regression analysis performed on
707 dimensions A_C and P_{AC} plotted against the prediction values obtained from Equation 1.

708
709 Despite having a higher R^2 than the linear equation, a 3rd degree polynomial equation greatly
710 overestimates the P_{AC} for A_C values above 130 mm (when the annulus dilates), yielding non-
711 physiological dimensions. Therefore, in this case, the linear prediction equation yields more sensible
712 P_{AC} values.

713
714
715
716
717
718
719
720
721
722
723

724 3. Prediction equations for mitral valve morphometry derived from literature and obtained
 725 clinical data

726

727 Table D represents the prediction equations found for mitral valve morphometry, numbered as through
 728 the main text, and together with statistical analysis. x and y variables represent tested mitral valve
 729 dimensions. $p < 0.05$ indicates that the regression analysis was significant.

730

731 Table D

Equation number	Regression model	x	y	C ₁	C ₂	C ₃	R ²	P-value
3	Linear	A _C [mm]	A _{AC} [mm]	4.137	0.305		0.72	< 0.01
4	Linear	A _C [mm]	P _{AC} [mm]	-4.137	0.695		0.93	< 0.01
5	Linear	γ [cm]	A _{AC} [cm]	2.500	0.420		0.66	< 0.01
6	Linear	γ [cm]	P _{AC} [cm]	4.400	1.200		0.91	< 0.01
10	Linear	A _C [mm]	δ [mm]	18.824	0.704		0.76	< 0.01
11	Linear	P _{AC} [mm]	δ [mm]	26.301	0.964		0.74	< 0.01
13	Linear	σ	NPA [°]	179.600	-163.900		0.70	< 0.01
14	Linear	σ	τ	0.027	0.970		0.78	< 0.01
15	Exponential	γ [mm]	IT [mm]	19.280	0.017		0.65	< 0.01
16	Linear	τ	NPA [°]	177.580	-142.880		0.64	< 0.01
17	Linear	A _{na} [mm ²]	AP [mm]	18.206	0.016		0.65	< 0.01
21	Linear	AP [mm]	A _{cord} [mm]	1.391	0.580		0.97	< 0.01
22	Linear	A _{cord} [mm]	P _{cord} [mm]	-1.279	0.667		0.82	< 0.01
23	Linear	A _C [mm]	A _{LA} [mm ²]	127.300	3.549		0.70	< 0.01
24	Linear	A _{AC} [mm]	A _{LA} [mm ²]	114.830	10.630		0.81	< 0.01
25	Linear	δ [mm]	A _{LA} [mm ²]	17.840	0.150		0.62	< 0.01
26	Linear	A _C [mm]	P _{LA} [mm ²]	65.749	4.262		0.85	< 0.01
27	Linear	P _{AC} [mm]	P _{LA} [mm ²]	113.250	5.798		0.82	< 0.01
28	Linear	P _{LA} [mm ²]	δ [mm]	14.797	0.152		0.75	< 0.01
29	Linear	A _{LA} [mm ²]	P _{LA} [mm ²]	53.285	0.914		0.71	< 0.01
30	Exponential	μ [mm]	λ [cm ²]	0.066	0.325		0.68	< 0.01
31	Polynomial	ε [%]	BV [ml]	10.000	-0.792	0.016	0.66	< 0.01
32	Linear	υ [mm]	RV [ml]	-36.440	1.434		0.84	< 0.01
33	Linear	TD [mm/m ²]	M _{RF} [%]	-60.990	3.583		0.58	< 0.01

732

733

734

735

736

737 4. *Example of regression analysis performed on data obtained from our 2D echocardiographic*
738 *study*
739

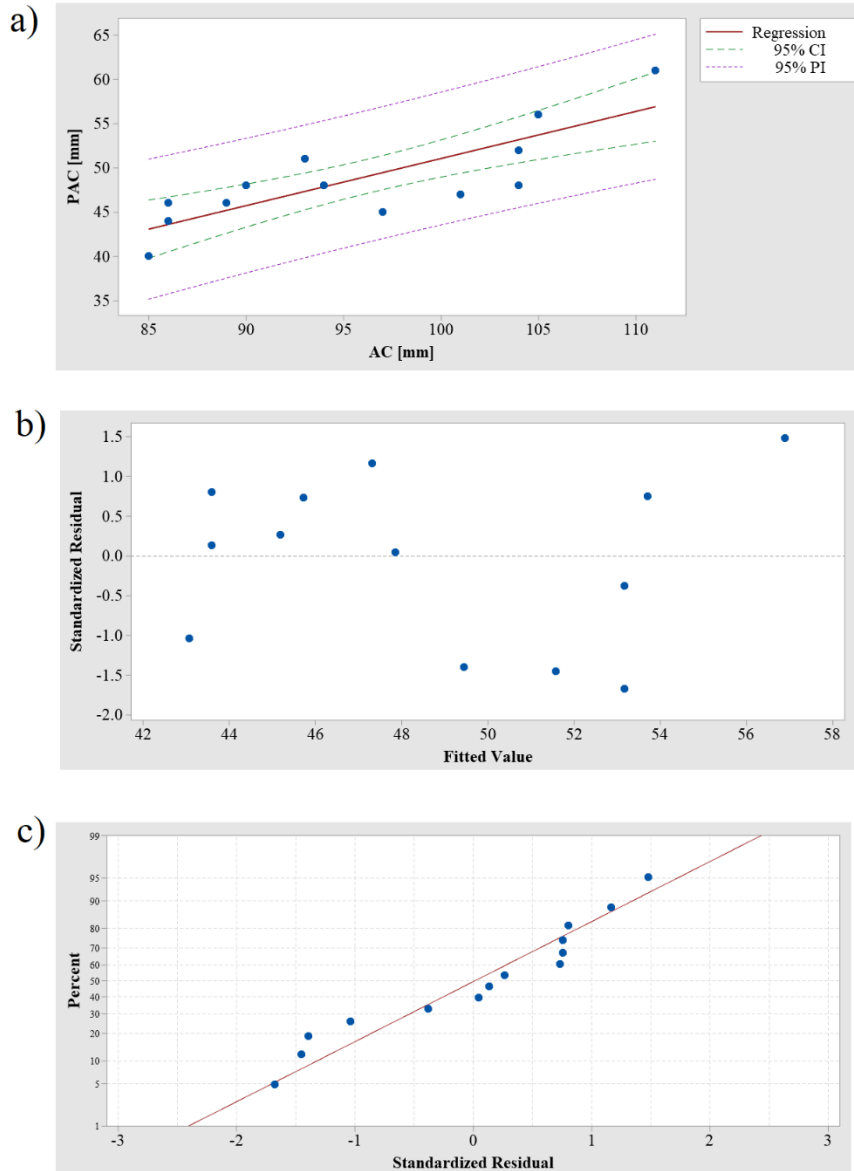
740 Below is the regression analysis performed on data that we obtained from the database collected under
741 the research study “Exercise Capacity in Adults” and from which prediction equations 5 (Figure A2)
742 and 15 (Figure A3) were derived. Although the R^2 values for these equations are neither the highest
743 nor the lowest, we chose them as an example of our regression analysis, because they derive from
744 patient data collected by us, and not present in the literature.

745 On Figures A2 and A3 (a), the 95% confidence intervals shows us the two confidence boundaries
746 where we can be 95% confident that that the true best-fit regression line is enclosed, while the 95%
747 prediction intervals is the area in which 95% of all data points fall. On the other hand, each residual
748 plot (Figures A2 and A3 (b)) shows how much the regression line vertically misses a data point,
749 therefore displaying the difference between real and predicted response values. These residuals are
750 randomly scattered above and below, showing that the assumptions of regression have been met. The
751 standardized residuals are further away from zero for prediction equation 15 in comparison with
752 equation 5, which shows that equation 5 better represents the real data and that equation 15 may
753 generate outliers.

754 An additional normality test on the residuals was performed to verify the regression assumption that
755 their distribution follows a Gaussian (or normal) distribution (Figures A2 and A3 (c)). We can observe
756 that the residuals follow the ideal straight line. To further test for normality of data, an Anderson-
757 Darling test was performed on the residuals, yielding p-values of 0.159 and 0.608 for equations 5 and
758 15, respectively. These show that there is not enough evidence for deviation of residuals from
759 normality and therefore we can assume that the residuals follow a normal distribution.

760

761



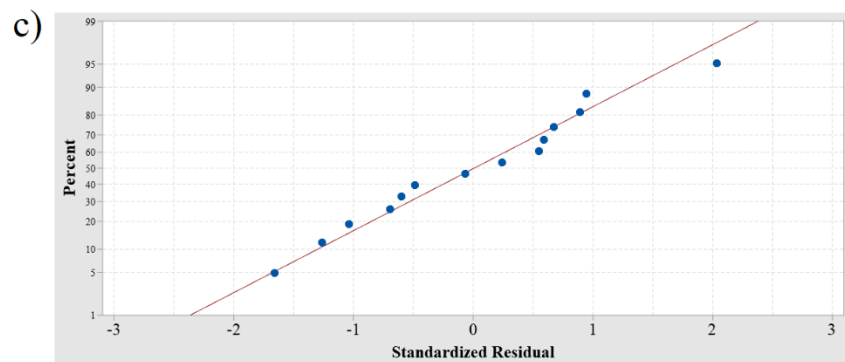
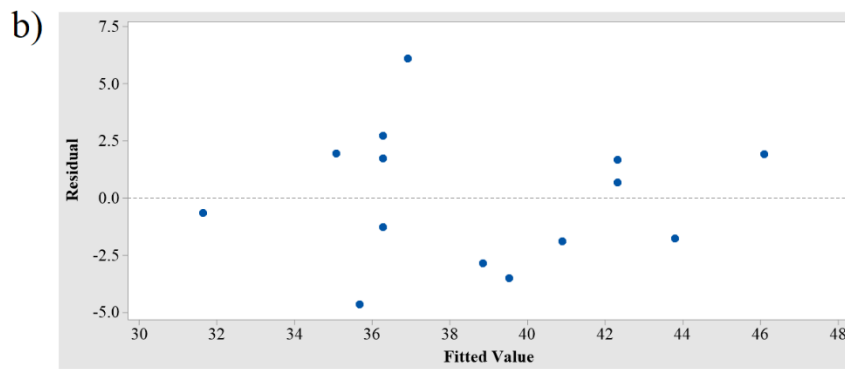
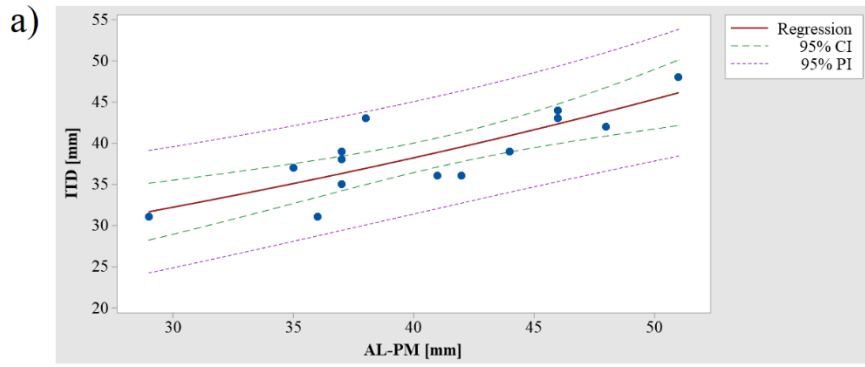
762

763 Figure A2. Regression analysis performed on dimensions A_C and P_{AC} (equation 5). a) Each blue marker represents data
 764 from each patient and linear regression (red line; $R^2 = 0.67$, p -value < 0.01) is presented, with 95% confidence (green, CI)
 765 and prediction (purple, PI) intervals; b) Residual plot, showing standardized residuals against fitted values; c) Normal
 766 probability plot of residuals, showing standardized residuals (x) identified with the percentiles (y) to which they correspond
 767 and displayed together with the ideal normal line (p -value = 0.159).

768

769

770



771

772 Figure A3. Regression analysis performed on dimensions AL-PM and inter-trigonal distance (ITD) (equation 15). a) Each
 773 blue marker represents data from each patient and exponential regression (red line; $R^2 = 0.66$, p -value < 0.01) is presented,
 774 with 95% confidence (green, CI) and prediction (purple, PI) intervals; b) Residual plot, showing standardized residuals
 775 against fitted values; c) Normal probability plot of residuals, showing standardized residuals (x) identified with the
 776 percentiles (y) to which they correspond and displayed together with the ideal normal line (p -value = 0.608).

777

778

779

780

781

782

783

784 **Table legends**

785 **Table 1.** Geometric variables of the MV and healthy and diseased (significant regurgitation) literature
786 ranges ((Lee et al., 2013, Mihaila, 2013, Machino-Ohtsuka et al., 2016, Obase et al., 2016, Deorsola
787 and Bellone, 2018, Jassar et al., 2014, Calleja et al., 2015, Sonne et al., 2009, Pouch et al., 2014, Jiang
788 et al., 2014, Suri et al., 2009, Owais et al., 2016, Kunzelman et al., 1994, Ranganathan et al., 1970,
789 Delgado et al., 2009, Dudzinski and Hung, 2014, Yamaura, 2008, Kim et al., 2014, Topilsky et al.,
790 2013)). Dimensions obtained at: ‡, early systole; *, mid-systole; †, end-systole; ‡, averaged over
791 cardiac cycle; *, ex vivo. Notes: AP, antero-posterior; CW, commissural width; AL-PM, anterolateral-
792 posteromedial; NPA, non-planarity angle; IT, inter-trigonal; PM, papillary muscle; P1, posteromedial
793 commissural scallop; P2, posterior middle scallop; P3, anterolateral commissural posterior scallop;
794 AL, anterolateral; PM, posteromedial; ALPM, anterolateral papillary muscle; PMPM, posteromedial
795 papillary muscle.

796

797 **Figure legends**

798 **Figure 1.** Porcine mitral valve apparatus: a) displays the anterior leaflet and chordae tendineae and b)
799 focuses on the subvalvular apparatus, where chordae arise from both the PM and insert into the rough
800 region of the posterior leaflet.

801 **Figure 2.** Human MV leaflet tissue areas. Notes: C, clear zone; R, rough zone; B, basal zone.

802 **Figure 3.** Atrial and lateral views of a mitral valve schematic model based upon nine landmarks. The
803 annulus, anterior and posterior leaflets and papillary muscle tips can be observed.

804 **Figure 4.** Atrial (a) and lateral (b) views of important mitral annular dimensions. Notes: AV, aortic
805 valve; LT, left trigone; RT, right trigone; P1, P2, P3, posterior leaflet scallops; AL-PM diameter,
806 anterolateral-posteromedial diameter; AP, antero-posterior distance; CW, commissural width; IT,
807 inter-trigonal distance.

808 **Figure 5.** Circle representing the annulus, according to Okamoto et al. (2007), with relevant
809 dimensions highlighted. Notes: LT, left trigone; RT, right trigone; AL-PM diameter, anterolateral-
810 posteromedial diameter; CW, commissural width; IT distance, inter-trigonal distance; θ_{Tg} , trigonal
811 angle; θ_{Com} , commissural angle.

812 **Figure 6.** Hyperboloids representing the mitral valve saddle shape and defined by equation 11 (Park
813 et al., 2019) are displayed, created upon literature values for CW (33.3 mm), AP diameter (28 mm),
814 AL-PM diameter (31 mm) and AHCWR (0.237). We can observe different commissural heights (b)
815 and posterior annular depth (c) in comparison with a pure hyperboloid (a), given by changes in
816 transformation parameters.

817 **Figure 7.** Coaptation triangle. The tenting height divides the base of the triangle (AP diameter) into
818 two segments – the anterior and the posterior cords. Notes: α_A , anterior leaflet angle; α_P , posterior
819 leaflet angle.

820 **Figure 8.** Parameters of human MV leaflet geometry, with an extended (a) and closed (b) leaflet
821 representation. Notes: A-B, anterolateral commissure; B-C, anterior leaflet; C-D, posteromedial

822 commissure; D-A', posterior leaflet; D-E, posteromedial commissural scallop (P1); E-F, middle
823 scallop (P2); F-A', anterolateral commissural scallop (P3).

824 **Figure 9.** Measurements describing PM morphology. Notes: ALPM, anterolateral PM; PMPM,
825 posteromedial PM.

826 **Figure 10.** Distances between PM tips and o'clock points of mitral annulus, in axial (left) and isometric
827 (right) views (adapted from (Sakai et al., 1999, Yamaura, 2008)). Notes: ALPM, anterolateral PM;
828 PMPM, posteromedial PM; 0 o'clock, midpoint of the anterior annular circumference; 2 o'clock, right
829 trigone; 10 o'clock, left trigone; 4 o'clock, separation of posterior and middle scallops of posterior
830 leaflet; 8 o'clock, separation of anterior and middle scallops of posterior leaflet.

831 **Figure 11.** Axial view of C-shape representation for the PMs, as present in the literature and suggested
832 by expert surgeons, as well as a simplified depiction of chordae tendineae insertion patterns. Blue,
833 green and orange chordae are those inserting into the anterior leaflet, posterior leaflet and
834 paracommissural zones, respectively.

835
836 **Figure 12.** Example of Reeb graph employed to characterize chordae tendineae topology in Khalighi
837 et al. (2017), illustrating the connectivity between branches. Green, blue and orange vertices
838 correspond to chordal origin (at the PM level), bifurcation points and insertion points into the leaflets,
839 respectively.

840
841 **Figure 13.** Hyperboloids representing: a) a mitral annular normal saddle configuration; b) a
842 configuration associated with type I dysfunction, defined as in Park et al (Park et al., 2019). The first
843 configuration was created with the dimensions mentioned on Figure 6 and the diseased one upon
844 literature values for CW (42.2 mm), AP diameter (38.8 mm), AL-PM diameter (39 mm) and AHCWR
845 (0.132).

846
847 **Figure A1.** Linear ($R^2 = 0.93$, p -value < 0.01) and non-linear ($R^2 = 0.98$, p -value < 0.01) regression
848 analysis performed on dimensions AC and PAC plotted against the prediction values obtained from
849 Equation 1.

850
851 **Figure A2.** Regression analysis performed on dimensions AC and PAC. a) Each blue marker
852 represents data from each patient and linear regression (red line; $R^2 = 0.67$, p -value < 0.01) is
853 presented, with 95% confidence (green, CI) and prediction (purple, PI) intervals; b) Residual plot,
854 showing standardized residuals against fitted values; c) Normal probability plot of residuals, showing
855 standardized residuals (x) identified with the percentiles (y) to which they correspond and displayed
856 together with the ideal normal line (p -value = 0.159).

857
858 **Figure A3.** Regression analysis performed on dimensions AL-PM and inter-trigonal distance (ITD).
859 a) Each blue marker represents data from each patient and exponential regression (red line; $R^2 = 0.66$,
860 p -value < 0.01) is presented, with 95% confidence (green, CI) and prediction (purple, PI) intervals; b)
861 Residual plot, showing standardized residuals against fitted values; c) Normal probability plot of
862 residuals, showing standardized residuals (x) identified with the percentiles (y) to which they
863 correspond and displayed together with the ideal normal line (p -value = 0.608).

864