

## Transoral tongue base mucosectomy for the identification of the primary site in the work-up of cancers of unknown origin

Farooq, Saadia ; Khandavilli, Sunil ; Dretzke, Janine; Moore, David; Nankivell, Paul; Sharma, Neil; de Almeida, John R. ; Winter, Stuart; Simon, Christian; Paleri, Vinidh; De, Mrganke ; Siddiq, Somiah ; Holsinger, Christopher ; Ferris, Robert L. ; Mehanna, Hisham

DOI:

[10.1016/j.oraloncology.2019.02.018](https://doi.org/10.1016/j.oraloncology.2019.02.018)

License:

Creative Commons: Attribution-NonCommercial-NoDerivs (CC BY-NC-ND)

*Document Version*

Publisher's PDF, also known as Version of record

*Citation for published version (Harvard):*

Farooq, S, Khandavilli, S, Dretzke, J, Moore, D, Nankivell, P, Sharma, N, de Almeida, JR, Winter, S, Simon, C, Paleri, V, De, M, Siddiq, S, Holsinger, C, Ferris, RL & Mehanna, H 2019, 'Transoral tongue base mucosectomy for the identification of the primary site in the work-up of cancers of unknown origin: systematic review and metaanalysis', *Oral Oncology*, vol. 91, pp. 97-106. <https://doi.org/10.1016/j.oraloncology.2019.02.018>

[Link to publication on Research at Birmingham portal](#)

### General rights

Unless a licence is specified above, all rights (including copyright and moral rights) in this document are retained by the authors and/or the copyright holders. The express permission of the copyright holder must be obtained for any use of this material other than for purposes permitted by law.

- Users may freely distribute the URL that is used to identify this publication.
- Users may download and/or print one copy of the publication from the University of Birmingham research portal for the purpose of private study or non-commercial research.
- User may use extracts from the document in line with the concept of 'fair dealing' under the Copyright, Designs and Patents Act 1988 (?)
- Users may not further distribute the material nor use it for the purposes of commercial gain.

Where a licence is displayed above, please note the terms and conditions of the licence govern your use of this document.

When citing, please reference the published version.

### Take down policy

While the University of Birmingham exercises care and attention in making items available there are rare occasions when an item has been uploaded in error or has been deemed to be commercially or otherwise sensitive.

If you believe that this is the case for this document, please contact [UBIRA@lists.bham.ac.uk](mailto:UBIRA@lists.bham.ac.uk) providing details and we will remove access to the work immediately and investigate.



## Review

## Transoral tongue base mucosectomy for the identification of the primary site in the work-up of cancers of unknown origin: Systematic review and meta-analysis



Saadia Farooq<sup>a</sup>, Sunil Khandavilli<sup>a</sup>, Janine Dretzke<sup>b,c</sup>, David Moore<sup>b,c</sup>, Paul C. Nankivell<sup>a,b,c</sup>, Neil Sharma<sup>a,b,c</sup>, John R. de Almeida<sup>d</sup>, Stuart C. Winter<sup>e</sup>, Christian Simon<sup>f</sup>, Vinidh Paleri<sup>g</sup>, Mrganke De<sup>a,b</sup>, Somiah Siddiq<sup>a,b</sup>, Christopher Holsinger<sup>h</sup>, Robert L. Ferris<sup>i</sup>, Hisham Mehanna<sup>a,b,c,\*</sup>

<sup>a</sup> Department of Otolaryngology, Head and Neck Surgery, University Hospitals Birmingham NHS Foundation Trust, Birmingham, UK

<sup>b</sup> Institute of Head and Neck Studies and Education, University of Birmingham, UK

<sup>c</sup> Institute of Cancer and Genomic Sciences, University of Birmingham, UK

<sup>d</sup> Department of Otolaryngology- Head and Neck Surgery, Princess Margaret Cancer Center/University Health Network, Toronto, Canada

<sup>e</sup> Nuffield Department of Surgical Sciences, University of Oxford. Churchill Hospital, Oxford University Hospitals NHS Foundation Trust, UK

<sup>f</sup> Department of Otolaryngology - Head and Neck Surgery, CHUV, UNIL, Lausanne, Switzerland

<sup>g</sup> Department of Otolaryngology, Head and Neck Surgery, Royal Marsden Hospital, Royal Marsden NHS Foundation Trust, UK

<sup>h</sup> Department of Otolaryngology, Head and Neck Surgery, Stanford University Medical Center, U.S.A

<sup>i</sup> Department of Otolaryngology, Head and Neck Surgery, University of Pittsburgh Medical Center, Eye and Ear Institute, Pittsburgh, Pennsylvania, U.S.A

## ARTICLE INFO

## Keywords:

Unknown primary  
Trans oral robotic surgery  
Trans oral LASER  
Microsurgery  
Tongue base mucosectomy  
Cancer of unknown origin  
Head and neck cancer

## ABSTRACT

**Background:** The use of transoral robotic surgery (TORS) and laser microsurgery (TLM) in the diagnosis and identification of the site of the unknown primary has become increasingly common. This systematic review and meta-analysis aims to assess the use and efficacy of TORS and TLM for this indication.

**Method:** Systematic review and meta-analysis of studies employing TORS or TLM in diagnosis of the unknown primary tumor site in patients with cervical nodal metastases of squamous cell origin. MEDLINE, EMBASE and CINHAL were searched from inception to July 2018 for all studies that used TORS and or TLM in identifying the unknown primary.

**Results:** 251 studies were identified, of which 21 were eligible for inclusion. The primary tumour was identified by TORS/TLM in 78% of patients (433 out of 556). Tongue base mucosectomy (TBM) identified the primary in 222 of 427 cases (53%). In patients with negative physical examination, diagnostic imaging and PETCT, TBM identified the primary in 64% (95% CI 50, 79) cases. In patients who had negative CT/MRI imaging, negative PETCT and negative EUA and tonsillectomy, TBM identified a tongue base primary in 78% (95% CI 41, 92) cases. Haemorrhage, the commonest complication, was reported in 4.9% cases. Mean length of stay varied between 1.4 and 6.3 days.

**Conclusion:** Tongue base mucosectomy, performed by TORS or TLM, is highly efficacious in identifying the unknown primary in the head and neck region.

## Introduction

Metastatic cervical lymphadenopathy from an unknown primary tumour accounts for 2% to 5% of head and neck squamous cell carcinomas (HNSCC) [1,2]. The importance of identifying the primary site lies in minimizing the potential morbidity from treatment by reducing the radiation field [3]. Although not conclusive, some evidence suggests that patients with an identified primary may also enjoy better oncologic

outcomes than those with unidentified primaries [4].

The outpatient workup of these patients traditionally involves taking a thorough history and examination (including flexible nasolaryngopharyngoscopy) followed by conventional imaging (Computerised Tomography - CT scan, Magnetic Resonance Imaging - MRI), and/or Positron Emission Tomography - PETCT). If imaging fails to identify the site of the primary tumour, then panendoscopy, (+/- biopsies of the nasopharynx, hypopharynx) tonsillectomy and targeted

\* Corresponding author.

E-mail address: [h.mehanna@bham.ac.uk](mailto:h.mehanna@bham.ac.uk) (H. Mehanna).

<https://doi.org/10.1016/j.oraloncology.2019.02.018>

Received 19 September 2018; Received in revised form 17 February 2019; Accepted 20 February 2019

1368-8375/ © 2019 The Authors. Published by Elsevier Ltd. This is an open access article under the CC BY-NC-ND license (<http://creativecommons.org/licenses/by-nc-nd/4.0/>).

biopsies of the tongue base are usually performed [5]. Despite this, studies report that the primary tumour still might not be identified in up to 43% of cases [6].

Transoral Laser Microsurgery (TLM) and Transoral Robotic Surgery (TORS) of the base of tongue are two modalities that are being increasingly utilised to help identify the site of the primary tumour, especially in those patients where the site was not identified by conventional and PET CT imaging and/or examination under anesthetic. In the literature, this is variably described as either lingual tonsillectomy or tongue base mucosectomy (TBM). Both procedures involve removing the lymphatic tissue from the base of the tongue and preserving the underlying musculature. For the purposes of the review, the authors have considered both terms to be synonymous, but will use TBM within this paper. The procedure can be performed either as a unilateral or more commonly as a bilateral procedure.

A systematic review of a small cohort (139 cases) reported success rates ranging between 84 and 94% using TLM [7,8] and 72–90% using TORS [5,9–13]. However, it also concluded that the studies were small, of variable quality and utilised different diagnostic pathways [14]. Since then, several new studies have been published. Our systematic review incorporates the recent evidence, and therefore includes a much larger cohort of patients than previously published. We also aim to explore the efficacy of TBM when used at various points within the diagnostic pathway following different combinations of diagnostic modalities.

## Methods

### Search strategy

The protocol for this systematic review was registered with PROSPERO (CRD4201707920). Bibliographic databases (MEDLINE, CINAHL and Embase) were searched with no language restrictions from inception to July 2018. Text and index terms relating to the “unknown primary” and “TORS or TLM” were combined (see [Supplementary Table 1](#) for MEDLINE full search strategy). Reference lists of included studies were checked. In addition, conference abstracts from the American Head and Neck Society and European Head and Neck Society annual meetings for the past 5 years were examined for relevant studies.

### Inclusion and exclusion criteria

Primary studies of any study design (case studies, case series and cross sectional studies) were eligible for inclusion. Studies had to report on the transoral approach (TORS or TLM) used in identifying the primary site of head and neck cancers of unknown origin. Human studies of any language were included. If a case series had been updated, the most recent version was included. Studies were excluded if they were animal studies, did not use TORS or TLM or did not report on the location of the primary tumour in the head and neck region.

### Study selection

All retrieved titles and abstracts were screened by two reviewers (SF/SK) independently, with disagreements resolved by discussion with the senior author (HM). Where necessary, full texts were screened. The study selection process was documented using a PRISMA flow diagram and reasons for exclusion were noted.

### Data extraction

Data extraction was undertaken by two reviewers (SF/SK) using a piloted data extraction form. Discrepancies were resolved by discussion with the senior author. Data was extracted on: patient demographics, study design, pre-operative investigations, identification rate of the primary site using TORS and/or TLM, post-operative adverse events and length of stay. All data collected was collated on a Microsoft Excel® spreadsheet.

### Risk of bias assessment

Evaluation of the risk of bias was undertaken by one reviewer (SF) and checked by a second (SK). Criteria were adapted from the Joanna Briggs Institute checklists for case reports and case series [15]. These included items relating to sample selection and description, outcome selection and reporting and completeness of results.

### Synthesis and analysis

All results were tabulated and described narratively. The main outcome of interest was the proportion of primary tumours identified. Proportions were presented separately according to type of operation performed (lingual or palatine tonsillectomy) and the surgical technique used (TORS or TLM). As studies were deemed to have reasonably similar patient and study characteristics, the proportions identified were pooled together, and then separately for TORS and TLM, using a random effects model in STATA (version 13). Proportions were also pooled within sub-groups of patients with positive or negative findings upon preceding investigations. Data in the studies was not reported according to human papillomavirus status, however we examined proportions in the subgroup of studies with a reported HPV proportion of 90% or above. Adverse events and mean length of stay were also reported. Reporting of results was undertaken according to PRISMA guidelines [16].

## Results

### Study selection and characteristics

251 records were identified and screened, of which 21 studies, including a total of 556 cases, met the inclusion criteria. The main reasons for exclusion are detailed in [Fig. 1](#). On full manuscript review, a further two studies were excluded as three studies were from the same institution by the same author; and so the most recent of the three studies was included.

[Table 1](#) summarizes the main study and patient characteristics of the 21 included studies. The studies were published between 2011 and 2017. The majority (19 of 21) were case series, while two were case reports. There were no prospective studies. Three studies were multi-institutional [5,17,25], 16 were from single institutions [7–12,14,18,19,21–24,27,29] and two studies did not clearly state their provenance [26,28]

### Quality assessments of included studies

All but two studies [9,10] had clear inclusion and exclusion criteria ([Supplementary Table 1](#)). All studies demonstrated evidence of using valid diagnostic methods of assessing the patient for an unknown primary prior to the use of TORS or TLM. In all studies, patient selection was consecutive and based on hospital records. In terms of patient demographics, there was some significant variation in reporting amongst the studies. Three studies provided no information on patient demographics [24,27,28], nine studies provided some information on age range or gender [8,23] and the remaining provided details on both. Five of 21 studies did not collect adverse event data [7,23,26,28,29]. Eight studies reported on some complications, but not all the ones considered to be relevant [5,10,11,19,20,25,27]. Reporting of findings was based on the complete patient sample in all studies. There was significant heterogeneity between studies with an  $I^2$  statistic of 70.45%, ( $p < 0.01$ ).

### Patient characteristics

Of the 556 included patients 464 (83%) underwent TORS and 92 (17%) underwent TLM. Based on the 16 studies where relevant information was reported, the majority of subjects were male (88%) and

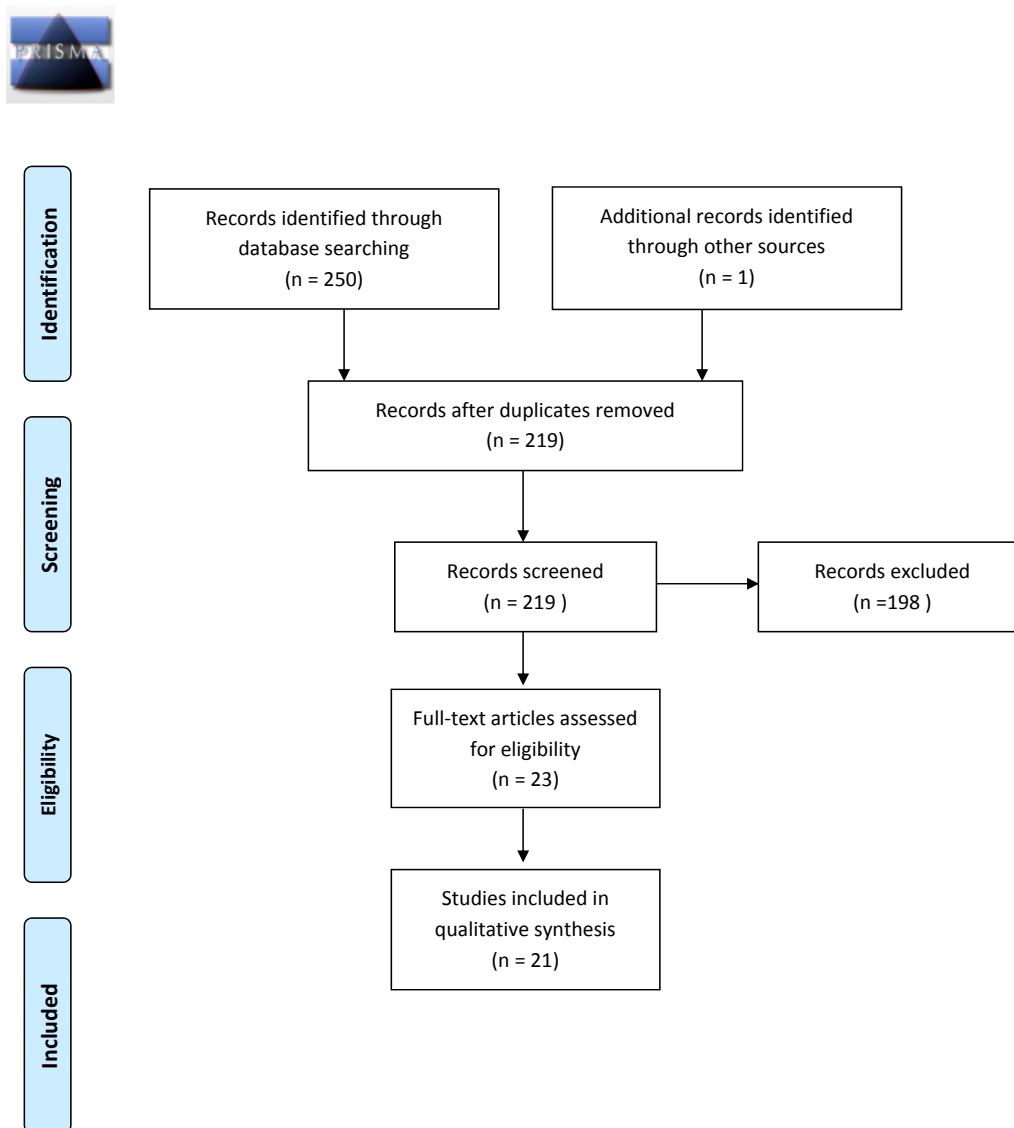


Fig. 1. PRISMA Flow Diagram.

the mean age was 56.6 years. 392 (70.5%) cases were positive for the Human papillomavirus (HPV). Seventeen studies reported on HPV status, of which 8 used p16 Immunohistochemistry [8,17,19–21,24,28,29], 7 studies did not provide any detail of how the HPV status was reached [5,9,12,18,22,25,26] one study used in-situ hybridization [11] and another used PCR [14]. Nodal status (according to the AJCC/UICC TNM 7th edition) was described for 453 patients in 16 studies, and was as follows: N1 = 108 (24%) N2 = 31 (7%), N2a = 110 (24%) N2b = 149 (33%) N2c = 22 (5%) and 33 (7%) were N3 [5,7,9–12,14,18–22,24–26,29]

#### Pre-operative workup

The preoperative work up of patients was described in all but one of the included studies and is summarised in Table 2. Clinical examination was a feature of all 21 studies. Panendoscopy and biopsy was performed in 18 studies [5,7–12,14,17–22,24,25,27,29], and conventional diagnostic imaging in the form of CT, MRI or both was undertaken in 9 studies [5,7,9,17,19,20,21,25]. PETCT was used as part of the initial workup in 18 studies [5,7,9–12,14,17–22,24–29]. There was significant heterogeneity in the incidence and timing of palatine tonsillectomy prior to TBM. 11 studies undertook palatine tonsillectomy at the time of TBM procedure [7–9,11,18–20,22,23,25,29], three before TBM [12,14,16], three sometimes before and sometimes with the TBM

[5,21,24], and four did not give information [10,26–28].

#### Identification of the unknown primary

Overall, regardless of timing within the diagnostic pathway, the proportion of primary tumours identified in the lingual or palatine tonsil, using either TORS or TLM, was 78% (95% CI 72–84), and ranged from 57–89% (Table 2 and 3). The pooled proportion identified by TORS, based on 15 case-series, was 74% (95% CI, 68%, 79%), and by TLM (based on three studies) was 91% (95% CI 85%, 98%) (see Fig. 2). The primary tumour site was identified in the tonsil in 31% (16%–45%) cases (Table 3).

#### Efficacy of tongue base mucosectomy

The primary tumour site was identified in the lingual tonsil by TBM in 53% (95% CI 43%, 63%) reported cases, (see Fig. 3). This varied by the type of diagnostic tests that had taken place before TBM in the diagnostic pathway. In patients with negative physical examination, diagnostic imaging and PETCT, the tumour site was still identified by palatine tonsillectomy and/or TBM in 73% of patients. TBM identified the primary in 64% (95% CI 50, 79) of such cases. In patients who had negative CT/MRI imaging, negative PETCT and negative EUA and biopsies [1], TBM identified a tongue base primary in 62% (95% CI 40,

**Table 1**  
Characteristics of studies included in the systematic review.

Study	No. of Patients (male/female)	Age	HPV status	Nodal status	Clinical examination	Panendoscopy EUA with biopsy	Diagnostic imaging	PET CT	Tonsillectomy
<i>Case series</i>									
Mehta 2013, University of Pittsburgh, USA	10 (9 M/1F)	55 (mean)	80% HPV + 10% HPV- 10% unknown	N1 = 1 N2a = 7 N3 = 2	✓	✓	✓	✓	✓
Channir 2015, Copenhagen Head and neck department, Rigshosp, pitalet	13 (9 M/4F)	60 (median 50–79)	54% HPV + ve 46% HPV -ve	N1 = 8 N2a = 3 N2b = 2	✓	✓	X	✓	✓
Patel 2013 University of Texas University of Alabama, University of Texas, John Hopkins hospital, Oregon Health sciences University of Washington medical centre	47 (42 M/5F)	57.3 (mean)	55% HPV + ve 17% HPV -ve 28% HPV unknown	N1 = 11 N2a = 9 N2b = 20 N3 = 3	✓	✓	✓	✓	✓
Winter 2017 Oxford university hospital, Newcastle upon tyne hospital, St Georges Hospital.	32 (27 M/5F)	57 (median 41–74)	72% HPV + ve 25% HPV-ve 3% HPV unknown	N/S	✓	✓	✓	✓	✓
Karni 2011 Washington university school of Medicine	18 (15 M/3F)	57	N/S	N1 = 5 N2 = 4 N3 = 4	✓	✓	✓	✓	✓
Durmus 2013 Ohio state University, wexner medical centre	22 (19 M/3F)	56.6 (median 36–71)	73% HPV + ve 18% HPV -ve 9% HPV unknown	N1 = 2 N2 = 16 N3 = 4	✓	✓	X	✓	✓
Nagel 2014 Mayo clinic Arizona	36 Gender N/S	59 (median 40–90)	86% HPV + ve 14% HPV -ve	N/S	✓	✓	N/A	N/A	✓
Geltzeiler 2017 University of Pittsburgh medical centre	50 (43 M/7F)	56.5 (mean SD 9.84)	92% HPV + ve 8% HPV-ve	N1 = 18 N2a = 13 N2b = 14 N2c = 2 N-stage unknown 3	✓	✓	X	✓	✓
Hatten 2017 University of Pennsylvania	60 (55 M/5F)	55.5 (mean)	92% HPV + ve 8% HPV -ve	N1 = 8 N2a = 25 N2b = 20 N2c = 4 N3 = 3	✓	✓	✓	✓	✓
Graboyes 2015 Washington University school of medicine	65 (56 M/9F)	53.5 (mean)	100% HPV + ve	N1 = 16 N2a = 19 N2b = 22 N2c = 3 N3 = 5	✓	✓	✓	✓	✓
Byrd 2014 University of Pittsburgh	22 (19 M/3F)	55.1 (mean)	90% HPV + ve 5% HPV -ve 5% HPV unknown	N1 = 9 N2 = 11 N2c = 2	✓	✓	✓	✓	✓
Khan and Kass 2016 Boston University	21 (20 M/1F)	56 (Mean)	100% HPV + ve	N1 = 3 N2a = 5 N2b = 11 N2c = 1 N3 = 1	✓	✓	X	✓	✓
Blanco 2013 Greater Baltimore medical centre	4 Gender N/S	52.36 (mean 18–80)	N/S	N/S	✓	N/A	N/A	N/A	✓

(continued on next page)

Table 1 (continued)

Study	No. of Patients (male/female)	Age	HPV status	Nodal status	Clinical examination	Panendoscopy EUA with biopsy	Diagnostic imaging	PET CT	Tonsillectomy
Krishnan 2016 Royal Adelaide Hospital South Australia	7 Gender N/S	NS	86% HPV + ve 14% HPV -ve	N1 = 3 N2a = 1 N2b = 4 N2c = 1	✓	✓	X	✓	✓
Patel 2017 University of Washington and University of Texas	35 (33 M/2F)	57.7(mean)	51.4% HPV + ve 17.1% HPV -ve 31% HPV unknown	N1 = 8 N2a = 5 N2b = 16 N2c = 3 N3 = 3	✓	✓	✓	✓	✓
Khan 2017 United States	64 (58 M/6F)	56.16 (41–72)	84.4% HPV + ve 3.1% HPV -ve 12.5% HPV unknown	N1 = 13 N2a = 14 N2b = 29 N2c = 3 N3 = 5	✓	X	N/A	✓	N/A
Wolford 2011 Loma Linda University Newman 2013 United states	9 Gender N/S 12 Gender N/S	N/S N/S	N/S 83 %HPV + ve 17% HPV -ve	N/S N/S	✓ N/A	✓ N/A	X N/A	✓ N/A	N/A N/A
Kuta 2017 QE II Health Centre Halifax, Canada	27 Gender N/S	59.6 (mean)	93% HPV + ve 7% HPV-ve	N1 = 3 N2a = 7 N2b = 11 N2c = 3 N3 = 3	✓	✓	N/A	✓	✓
<i>Case reports</i>									
Abuzeid 2016 University of Michigan	1 Male	57	100% HPV + ve	N2a = 1	✓	✓	✓	✓	✓
Mourad 2013 Albert Einstein College of Medicine, New York	1 Male	58	N/S	N2a = 1	✓	✓	X	✓	✓

**Table 2**  
Proportion of tumours identified by TORS/TLM overall, by lingual tonsillectomy and by palatine tonsillectomy.

Author	Proportion identified by TORS/TLM		Proportion identified by lingual tonsillectomy		Proportion identified by palatine tonsillectomy	
	TORS	TLM	TORS	TLM	TORS	TLM
<i>Case-series</i>						
Mehta	9/10 (90%)		9/10 (90%)		-	
Channir	7/13 (54%)		7/13 (54%)		-	
Patel	34/47 (72%)		21/41 (51%)		13/47 (28%)	
Winter	17/32 (53%)		17/32 (53%)		-	
Karni	-	17/18 (94%)		11/18 (61%)		6/18(33%)
Durmus	17/22 (77%)		4/14 (28.5%)		13/17 (76.5%)	
Nagel	-	31/36 (86%)		13/19 (68%)		
Geltzeiler	37/50 (74%)		32/50 (64%)		5/50 (10%)	
Hatten	48/60 (80%)		28/60 (47%)		18/60 (30%)	
Graboyes	No differentiation made by authors between TLM and TORS		61/65 (94%)	27/65	34/65	
Byrd	19/22 (86%)		16/22 (73%)		3/22 (13.6%)	
Khan/Kass	16/21 (76.1%)		-		-	
Blanco	1/4 (25%)		0/4		1/4 (25%)	
Krishnan	5/7 (71%)		5/7 (71%)			
Patel	26/35 (74%)		15 /35(42.9%)		13/35 (37%)	
			(2 cases with both lingual and palatine tonsils + 1 case glossotonsillar sulcus)		(2 cases with both lingual and palatine tonsils)	
Khan	48/64 (75%)	-	-		-	
Wolford	4/9 (44%)		4/9 (44%)		-	
Newman	10/12 (83%)				-	
Kuta		25/27 (93%)		12/27(44%)		13/27 (48%)
<i>Case-reports</i>						
Abuzeid	1/1 (100%)		1/1 (100%)		-	
Mourad	0/1				-	
Total pooled rate (95% CI)	74% (0.68%, 0.79%)	91% (85%, 97%)	53% (43%, 63%)	57% (43%, 72%)	31% (16%, 45%)	42% (28%, 56%)

\* based on case-series only and excluding Graboyes (as unclear if TORS or TLM).

84) cases. (Table 3 in the nine studies (case report excluded) that did TBM at the same time as palatine tonsillectomy and reported their data, TBM identified the primary site in 64.2% (95%CI 42, 63) cases. In the three studies which did palatine tonsillectomy before TBM, the primary site was identified in the tongue base in 78% (95% CI 41, 92) of cases.

*Site of primary tumour identified*

Tumours were ipsilateral in 419 (97%) of the cases reporting laterality. They were found in the contralateral tongue base in 8 (1.85%) cases [8,12,21,17,18] and in the contralateral palatine tonsil in one case (0.23%) case [21]. Bilateral tongue base tumours were identified in 1 (0.23%) case [11], and bilateral palatine tonsil primaries were identified in 3 (0.69%) cases [11,20].

*Effect of timing of TBM in the diagnostic pathway*

Table 3 shows the identification rate by any transoral surgery (palatine and/or TBM) overall, and also by TBM specifically, when used at various stages of the diagnostic pathway. These are reported according to whether the preceding investigations were negative or showed suspicious findings. Not all studies undertook the same number or type of investigations, and not all studies fully reported whether patients had suspicious/non-suspicious findings on one or more different investigations. Some identification rates are therefore based on only a small number of studies/patients, particularly for patients with suspicious findings.

Pooled identification rates in patients with no suspicious findings on different types of investigations ranged from 69–82% for TORS/TLM; and 59% to 64% for TBM. The identification rate by transoral surgery

**Table 3**  
Tumour site identification rates by TORS/TLM and by lingual tonsillectomy following different diagnostic techniques.

Preliminary investigation	Cases with no suspicious findings on preliminary investigations				Cases with Suspicious findings on preliminary investigations			
	Identification by TORS/TLM		Identification by lingual tonsillectomy		Identification by TORS/TLM		Identification by lingual tonsillectomy	
	N cases (n studies)	Pooled % (95% CI)	N cases (n studies)	Pooled % (95% CI)	N cases (n studies)	Pooled % (95% CI)	N cases (n studies)	Pooled % (95% CI)
Physical exam	321/416 (14 studies)	79 (73, 85)	168/297 (12 studies)	59 (49, 68)	1/105 (6 studies)	100% (1 patient)	1/105 (6 studies)	100% (1patient)
Conventional imaging (CT/MRI)	258/320 (10 studies)	82 (76, 89)	131/233 (8 studies)	59 (47, 71)	5/9 (1 study)	55.6% (5/9 patients)	0/42 (3 studies)	N/A
PET/CT	221/294 (12 studies)	75 (66, 84)	95/157 (7 studies)	61 (54–69)	50/61 (6 studies)	92 (75, 100)	6/6 (2 studies)	100 (70–100)
PE/DI/PET-CT	62/85 (4 studies)	73 (64, 83)	45/72 (3 studies)	64 (50, 79)	32/41 (3 studies)	84 (63, 98)	17/29 (2 studies)	61 (41, 80)
EUA with biopsy	53/80 (6 studies)	69 (57, 82)	52/97 (4 studies)	62 (40, 84)	12/14 patients (2 studies)	0.89 (63,100)	2/3 (1 study)	67% (2/3 patients)

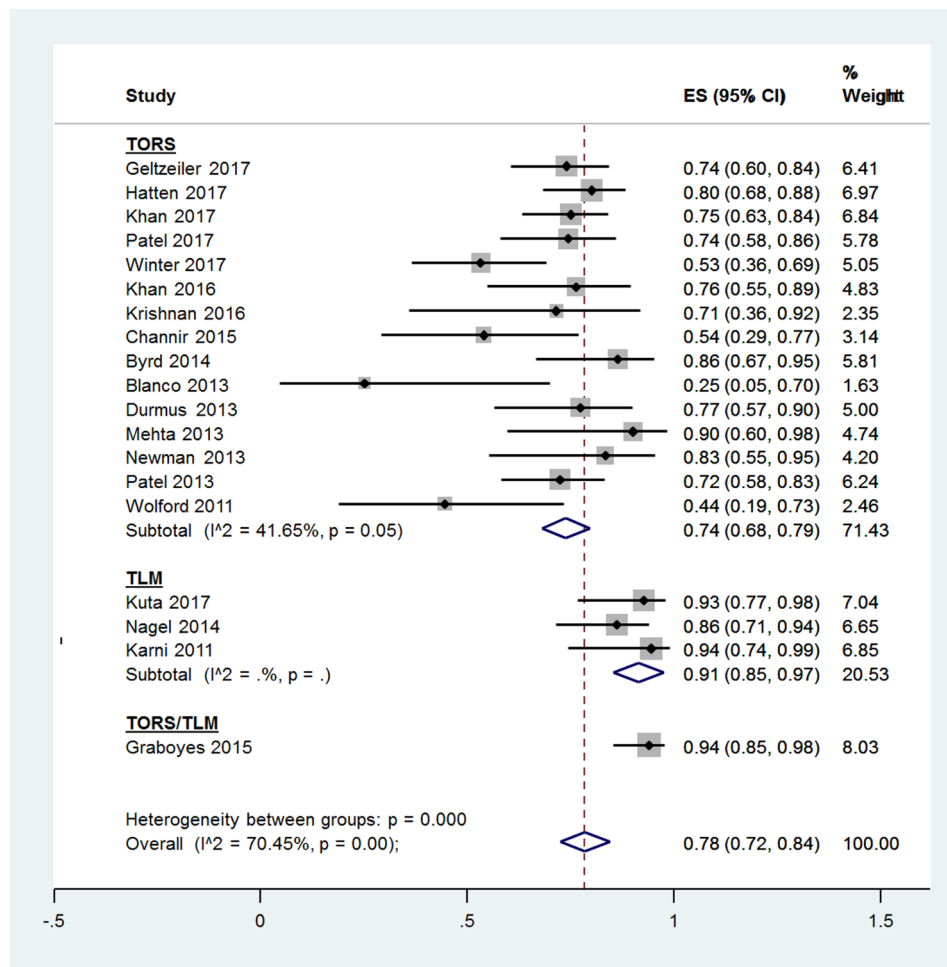


Fig. 2. Pooled rates of identification rates by transoral surgery overall and by TORS and TLM separately.

(by either palatine or lingual tonsillectomy) in cases with a negative physical examination was 79% (95% CI 73–85%). In these cases, TBM identified the primary site in 59% (95%CI 49–68%). In patients with negative physical examination and negative conventional diagnostic imaging, the primary was identified by transoral surgery in 82% (95% CI 76, 89%) of cases, with TBM also identifying 59% (95% CI 47, 71%) of cases. In patients with a negative PETCT scan, transoral surgery identified the primary in 75% (95% CI 66, 84%) cases; in these cases, TBM identified the primary in 61% (95% CI 54, 69%) of cases. Identification rates after negative examination, conventional and PETCT imaging, and then after panendoscopy TBM identified the primary site in 62% of cases (Table 4).

#### Effect of Human papillomavirus causation

There were 5 studies where HPV cases comprised 90% or more of the cases. In these the a primary was identified in the tongue base in 53% (95% CI = 42–65%) of cases, and in the palatine tonsils in 30% (95%CI = 19–48%)cases. However, heterogeneity between studies was high (I<sub>2</sub> = 67% and 90% respectively, limiting interpretation).

#### Utility of frozen section

Frozen section was utilised in 9 studies only. One study used frozen section and excluded patients with positive findings on frozen section from the reported results [18]. Eight studies used frozen section to direct margin control if positive and/or resection of the opposite side of the tongue base if negative [7,8,11,20,21,23,29,25]. In the eight studies utilizing frozen section, the rate of identification in the tongue base was 61% (95% CI 36, 61).

#### Adverse events and length of stay

Adverse events described in the studies are shown in Table 4. In total, 8 studies reported all expected adverse events and a total of 8 reported on selected adverse events. Mortality rates were most comprehensively reported: in 15 studies, there was only one death reported occurring post procedure secondary to a cardiopulmonary event. Haemorrhage was reported by 13 studies, with 19/387 (4.9%) patients experiencing bleeding as a complication of the procedure [5,8,9,12,14,17–21,24,25,27]. Thirteen studies reported on tracheostomy rates; no tracheostomies were placed in 220 patients [8–12,14,17,18,21,22,24,25,27]. Two patients out of 300 (0.7%) required a gastrostomy [12,18] Other complications, each occurring in a single patient, were: Tongue sensitivity, tongue swelling, chest infection, pulmonary embolus, readmission due to pain and dehydration and odynophagia secondary to candida [5,14,17,21,24] Only four studies described the mean length of stay, which varied between 1.4 and 6.3 days [21–24].

#### Discussion

Overall, in this meta-analysis, the proportion of primary tumours identified in the lingual or palatine tonsils, using TORS or TLM, ranged from 44–94%, with a pooled proportion of 78%, in those patients where the primary was not identified by previous investigations. Identification of a base of tongue primary by TBM occurred in 53% of reported cases, whilst identification of a tonsil primary occurred in 31% of cases. In those cases where TBM was performed following negative diagnostic



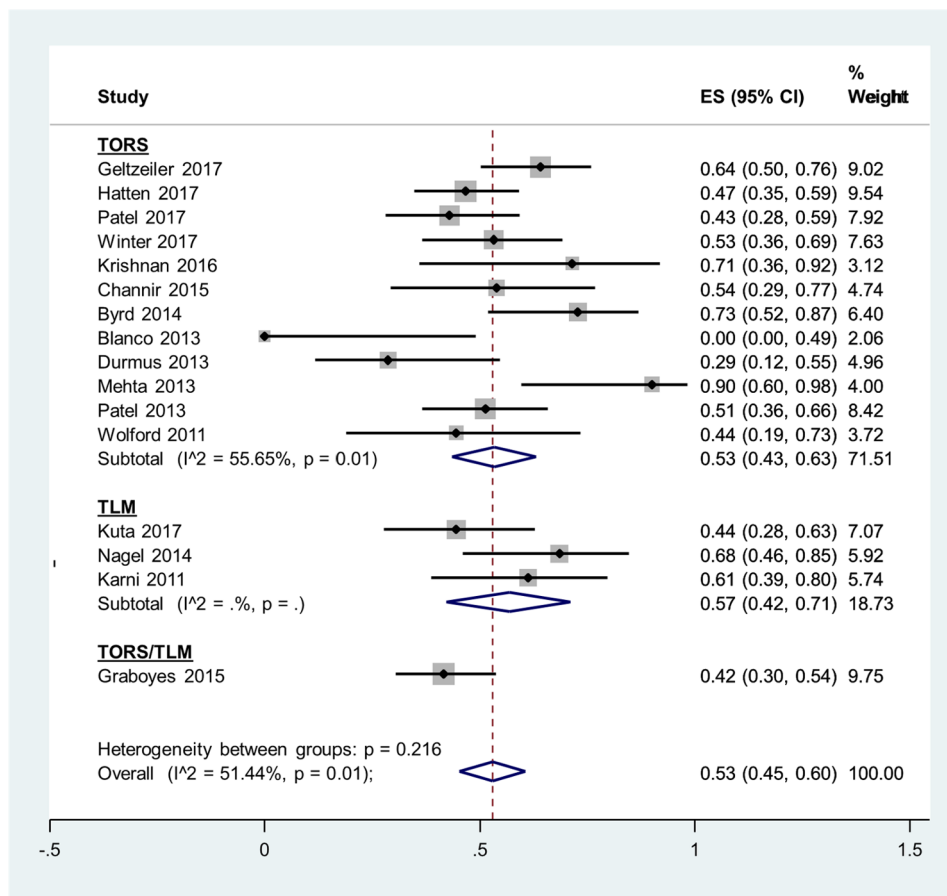


Fig. 3. Pooled rates of identification by TORS and TLM for lingual tonsillectomy.

Table 4

Table of adverse events following TORS and TLM.

Author	Tracheostomy	Haemorrhage	Gastrostomy	Other	Deaths	Length of stay	Total no. of complications
Mehta	0	0	1	0	0	NR	1 (10%)
Channir	0	1	0	1-Tongue sensitivity	0	NR	3 (23%)
Patel	NR	4	0	1- P.E.	0	NR	5 (10.6%)
Winter	0	2	0	1- chest infection	0	NR	3 (9.3%)
Karni	NR	NR	NR	0	0	NR	NR
Durmus	0	NR	0	0	0	NR	0
Nagel	0	1	0	0	0	NR	1 (2.7%)
Geltzeiler	0	2	1	0	0	NR	3 (6%)
Hatten	NR	3	0	0	1-Cardiopulmonary event post-procedure	NR	3 (5%)
Graboyes	NR	6	NR	0	0	NR	6 (9.2%)
Byrd	0	0	0	1-Pain and dehydration	0	1.4 days (mean)	1 (4.5%)
Khan/Kass	0	NR	NR	0	0	1.7 days (mean range 1–3)	0
Abuzeid	0	0	0	0	0	NR	0
Mourad	0	NR	NR	0	0	NR	0
Blanco	NR	NR	NR	0	NR	2.5 days (mean)	0
Krishnan	0	0	0	1-Candida - odynophagia	NR	6.3 days (mean) –four had neck dissection on same admission lengthening overall time of stay	1 (3.7%)
Patel	0	0	0	NR	0	NR	NR
Khan	NR	NR	NR	NR	NR	NR	NR
Wolford	0	0	0	NR	NR	NR	0
Newman	NR	NR	NR	NR	0	NR	NR
Kuta	NR	NR	NR	NR	NR	NR	NR

investigations (conventional imaging, PETCT, EUA and palatine tonsillectomy), the detection rate of the primary in the tongue base was even higher, with a pooled identification rate of 78%, demonstrating the considerable additional benefit of TBM in the diagnostic work up of cases of unknown primary of the head and neck. It should be noted however that these patients have already been highly selected by the fact that previous conventional and PET imaging, and in some cases examination under anaesthetic, have not identified the tumours.

Our review also highlights that there is still large variation in the diagnostic workup of occult primaries e.g. 43% performed a CT, 40% requested an MRI, 81% undertook a PETCT, and 5% performed an USS. Only 12.2% had palatine tonsillectomy prior to TBM by TORS. Whilst MRI and CT scans provide an abundance of information, its uses can be limited when the primary is small [30,31]. PETCT may be useful in these situations; however, it still fails to detect tumours less than 8 to 10 mm in diameter [32]. The detection rate of the unknown primary using PETCT has been reported as 44% with a sensitivity and specificity of 97% and 68% respectively [31,33]. A false positive rate of between 20 and 40% has been described in the literature for PETCT in the identification of the unknown primary [34]. Our meta-analysis found that in cases where the PETCT scan was negative, palatine and lingual tonsillectomy identified a primary site in a further 75% of cases. This demonstrates the additional benefit of palatine and lingual tonsillectomy following negative PETCT scans for this indication.

The efficacy of TBM varied with the timing of its application within the diagnostic pathway. TBM yielded the highest findings when applied at the end of the diagnostic pathway, after conventional imaging, PETCT, EUA and tonsillectomy were negative. The improvement in efficacy and detection rate should be weighed against the cost of an additional operative procedure, separate to the preceding EUA and tonsillectomy, and the potential delay in definitive treatment. A small study demonstrated that using TBM at the end of the pathway as a separate procedure when tonsillectomy was negative, was the most cost-effective scenario [19]. This requires further corroboration.

Our study found that the identification rates between TORS and TLM differed, 74% and 91% respectively. Whilst this suggests that TLM may be more effective at identifying the primary tumour, the underpinning evidence is limited, with only three studies reporting on a total of only 81 patients. The higher detection rate may therefore reflect selection bias in the reporting of TLM studies and the more limited availability of centres with TORS expertise compared to TLM.

Results were not reported in studies by HPV status. The rates of detection of the primary in series almost completely comprised of HPV + cases were similar to that the overall pooled cohort. However the heterogeneity between the limited number of studies was very high, limiting interpretation and conclusions.

The use of frozen section at the time of the procedure to confirm the primary site, and guide the procedure, does not appear to improve yield considerably. However, there was lack of clarity regarding the reporting of this in studies, and the utility of frozen section needs further study.

The most common surgical complication described by both the TORS and TLM studies was haemorrhage post surgery. Since, two studies out of three reporting on TLM failed to describe their complications; a direct comparison of this complication between the two methods was not possible. Gastrostomy-dependency is often quoted as one of the major drawbacks of chemoradiotherapy Durmus et al described a rate of 45% requiring a gastrostomy temporarily following TORS, with 1 patient remaining gastrostomy dependent [35]. Our systematic review found that the gastrostomy rate was 0.18% following TORS or TLM for this indication, and the tracheostomy rate was 0%.

A few studies have reported on the functional quality of life following TORS and TLM for the occult primary. This is an important factor when considering transoral surgery as a potential tool in the diagnosis pathway. One study considered four domains: Speech, eating, aesthetics and social disruption. Overall they found that low scores and

deterioration were detected in all four domains in the first three months. However, all domains except eating returned to pre-operative levels by 12 months [35]. A further study reported difficulties with eating and social disruption at 12 months whilst problems with speech and aesthetics returned to pre-operative levels [36].

The main strengths of this study lie in it being the largest reported meta-analysis, with a total of 556 cases from 21 studies. The previous systematic review by Fu et al in 2016 looked at 8 studies and a total of 139 patients. In addition, our study looked at the role of mucosectomy in different workup pathways and with different combinations of diagnostic techniques, including physical examination and conventional radiological and PETCT workup.

The main limitation of this study was that the underlying data was reported in case reports and case series. As a result, there was significant variability in diagnostic work-up, and there is likely to be considerable variation in surgical technique. It is also highly likely that there is bias in case selection. There is currently a prospective trial recruiting in Toronto assessing the efficacy of TORS in identifying small oropharyngeal carcinomas. Larger, prospective multicentre, and possibly multi-national, studies are needed. These must ensure better standardisation of techniques both diagnostically and in terms of treatment. Another limitation is that five studies did not report complication rates and 8 did not state the incidence of some of the potential complications. Therefore, it is possible that there is an underreporting of the complication rates.

Identification of the primary mucosal lesion in cases of cervical metastases of unknown origin can play an important role in the management of the patient's disease. Detection of the primary may potentially completely obviate the need for radiotherapy resulting in single modality treatment. Alternatively, it may result in the reduction of the dose of radiotherapy given to the contralateral uninvolved tonsil and neck, which may lead to reduced toxicity. Furthermore in some studies, patients whose site has been identified demonstrated significantly better survival outcomes compared to those patients where no primary site has been identified [7,37,38,39].

Finally, there are still several unanswered questions regarding the timing, techniques and cost-effectiveness of TBM. Furthermore, the effect of HPV status on the efficacy of TBM should be examined and reported, as this may have an implication for the cost-effectiveness of the procedure. Additionally, no studies to date have looked at the psychological impact on patients when a series of investigations are performed, only to conclude that this is an unknown primary. Prospective, and especially randomised, trials examining the use, quality of life outcomes and cost effectiveness of TBM by transoral surgery in this setting are much needed.

## Conclusion

Overall, this systematic review confirms the high efficacy of TBM by TORS and TLM in identifying the site of the primary in cases of head and neck cancer, especially in cases where the primary site has not been identified by other diagnostic methods. Data remains mainly from case series, and prospective randomised data on cost effectiveness and quality of life outcomes is much needed.

## Conflict of interest statement

The authors declare that there are no conflicts of interest to report.

## Appendix A. Supplementary material

Supplementary data to this article can be found online at <https://doi.org/10.1016/j.oraloncology.2019.02.018>.

## References

- [1] Grau C, Johansen LV, Jakobsen J, Geertsen P, Andersen E, Jensen BB. Cervical lymph node metastases from unknown primary tumours. Results from a national survey by the danish society for head and neck oncology. *Radiother Oncol*. 2000;55(2):121–9.
- [2] Schmalbach CE, Miller FR. Occult Primary head and neck carcinoma. *Curr Oncol Rep* 2007;9(2):139–46.
- [3] Hosni A, Dixon PR, Rishi A, Au M, Song Y, Goldstein Chepeha DB, et al. Radiotherapy characteristics and outcomes for head and neck carcinoma of unknown primary vs T1 base-of-tongue carcinoma. *JAMA Otolaryngol Head Neck Surg* 2016;142(12):1208–15.
- [4] Haas I, Hoffman TK, Engers R, Ganzer U. Diagnostic strategies in cervical carcinoma of an unknown primary. *Eur Arch Otolaryngol* 2002;259(6):325–33.
- [5] Patel SA, Magnuson JS, Holsinger FC, Karni RJ, Richmon JD, Gross ND, et al. Robotic surgery for primary head and neck squamous cell carcinoma of unknown site. *JAMA Otolaryngol Head Neck Surg* 2013;139(11):1203–11.
- [6] Pattani KM, Goodier M, Lilien D, Kupferman T, Caldito G, Nathan CO. Utility of Panendoscopy for the detection of the unknown primary head cancer in patients with a negative PET/CT scan. *Ear Nose Throat J* 2011;90(8):16–20.
- [7] Karni RJ, Rich JT, Sinha P, Haughey BH. Transoral laser microsurgery: a new approach for unknown primaries of the head and neck. *Laryngoscope* 2011 Jun;121(6):1194–201.
- [8] Nagel TH, Hinni ML, Hayden RE, Lott DG. Transoral laser microsurgery for the unknown primary: role for lingual tonsillectomy. *Head Neck* 2014 Jul;36(7):942–6.
- [9] Abuzeid WM, Bradford CR, Divi V. Transoral robotic biopsy of the tongue base: a novel paradigm in the evaluation of unknown primary tumors of the head and neck. *Head Neck* 2013;35(4):E126–30.
- [10] Mourad WF, Dukagjin MB, Rafi K, Young R, Rania S, Glanzman J, Patel S, Yaparpalvi R, Kalnicki S, Garg MK. Lack of adjuvant radiotherapy may increase risk of retropharyngeal node recurrence in patients with squamous cell carcinoma of the head and neck after transrobotic surgery. *Case reports in oncological medicine*; 2013; vol. 2013 p. 727904.
- [11] Durmus K, Rangarajan SV, Old MO, Agrawal A, Teknos TN, Ozer E. Transoral robotic approach to carcinoma of unknown primary. *Head Neck* 2014;36(7):848–52.
- [12] Mehta V, Johnson P, Tassler A, et al. A new paradigm for the diagnosis of and management of unknown primary tumours of the head and neck. A role for transoral robotic surgery. *Laryngoscope* 2013;123(1):146–51.
- [13] Fu TS, Foreman A, Goldstein DP, de Almeida JR. The role of transoral robotic surgery, transoral microsurgery, and lingual tonsillectomy in the identification of head and neck squamous cell carcinoma of unknown primary origin: a systematic review. *J Otolaryngol Head Neck Surg* 2016;45:28.
- [14] Channir HI, Rubek N, Nielsen HU, Kiss K, Charabi BW, Lajer CB, et al. Transoral robotic surgery for the management of head and neck squamous cell carcinoma of unknown primary. *Acta Otolaryngol* 2015;135(10):1051–7.
- [15] University of Adelaide. Joanna Briggs institute. JBI 2017. Accessed December 2017. <http://joannabriggs.org/research/critical-appraisal-tools.html>.
- [16] Moher D, Liberati A, Teziff J, Altman DG. The PRISMA group, preferred reporting items for systematic reviews and Meta- Analyses: The PRISMA statement. *International Journal of* . <http://doi.org/10.1016/j.ijvsu.2010.02.007>.
- [17] Winter SC, Ofo E, Meikle D, Silva P, Fraser L, O'Hara J, et al. Paleri V. Transoral robotic assisted tongue base mucosectomy for investigation of cancer of unknown primary in the head and neck region. The UK experience. *Clin Otolaryngol* 2017;42(6):1247–51.
- [18] Geltzeiler M, Doerfler S, Turner M, Albergotti WG, Kubik M, Kim S, et al. Transoral robotic surgery for management of cervical unknown primary squamous cell carcinoma: updates on efficacy, surgical technique and margin status. *Oral Oncol* 2017;66:9–13.
- [19] Hatten KM, O'Malley BW, Bur AM, Patel MR, Rassekh CH, Newman JG, et al. Transoral robotic surgery assisted endoscopy with primary site detection and treatment in occult mucosal primaries. *JAMA otolaryngol Head Neck Surg* 2017;143(3):267–73.
- [20] Graboyes EM, Sinha P, Thorstad WL, Rich JT, Haughey BH. Management of human papilloma-related unknown primaries of the head and neck with a transoral surgical approach. *Head Neck* 2015;37(11):1603–11.
- [21] Byrd JK, Smith KJ, de Almeida JR, Albergotti WG, Davis KS, Kim SW, et al. Transoral robotic surgery and the unknown primary: a cost effectiveness analysis. *Otolaryngol Head Neck Surg* 2014;150(6):976–82.
- [22] Khan N, Kass M, Miles B, Genden E. Transoral robotic assisted resection approach for identifying unknown primaries of the head and neck. *Int J Radiat Oncol Biol Phys* 2016;94(4):P893.
- [23] Blanco RG, Fakhry C, Ha PK, Ryniak K, Messing B, Califano JA, et al. Transoral robotic surgery experience in 44 cases. *J Laparoendoscopic Adv Surg Techniq Part A* 2013;23(11):900–7.
- [24] Krishnan S, Connell J, Ofo E. Transoral robotic surgery base of tongue mucosectomy for head and neck cancer of unknown primary. *ANZ J Surg* 2017;87(12):E281–4.
- [25] Patel SA, Parvathaneni A, Parvathaneni U, Houlton JJ, Karni RJ, Liao JJ, et al. Post-operative radiotherapy following transoral robotic surgery for unknown primary cancers of the head and neck. *Oral Oncol* 2017 Sep;72:150–6.
- [26] Khan M, Chouke RJ, Mendez E, Futran ND, Teng MS, Genden EM, et al. Transoral Robotic surgery- identifying unknown primaries of the head and neck. *Otolaryngol Head Neck Surg* 2017;157(1).
- [27] Wolford B, Lee S, Simental A, Stewart C, Kim P. Tongue base resection in the workup of unknown primary head and neck cancer. *Otolaryngol- Head Neck Surg* 2011;145:184–5.
- [28] Newman JG, O'Malley BW, Rassekh CH, Lin A, Chalian AA, Lajud SA, et al. Management of the unknown primary in the era of HPV and robotics. *Otolaryngol-Head Neck Surg* 2013;149(2).
- [29] Kuta V, Williams B, Rigby M, Hart R, Trites J, Mackay C, et al. Management of head and neck primary unknown squamous cell carcinoma using combined positron emission tomography - computed tomography and transoral laser microsurgery. *Laryngoscope* 2017.
- [30] Pavlidis N, Fizazi K. Carcinoma of unknown primary. *Crit Review Oncol Hematol* 2009;69(3):271–8.
- [31] Kwee T, Basu S, Cheng G, Alavi A. FDG PET/CT in carcinoma unknown primary. *Eur J Nucl Med Mol Imaging* 2010 Mar;37(3):635–44.
- [32] Rumboldt Z, Gordon L, Gordon L, Bonsall R, Ackermann S. Imaging in head and neck cancer. *Curr Treat Options Oncol* 2006 Jan;7(1):23–34.
- [33] Zhu L, Wang N. 18F-fluorodeoxyglucose positron emission tomography-computed tomography as a diagnostic tool in patients with cervical node metastases of unknown primary site: a meta-analysis. *Surg Oncol* 2013;22(3):190–4.
- [34] Greven KM, Keyes Jr JW, Williams III DW, McGuirt WF, Joyce III WT. Occult primary tumours of the head and neck: lack of benefit from positron emission tomography imaging with 2-(F-18) fluoro-2-deoxy-D-glucose. *Cancer* 1999;86:114–8.
- [35] Durmus K, Patwa HS, Gokazan HN, Kucur C, Teknos TN, Agrawal A, et al. Functional and Quality of life outcomes of transoral robotic surgery for carcinoma of unknown primary. *Laryngoscope* 2014;124(9):2089–95.
- [36] Ozbay I, Yumusakhuylu AC, Sethia R, Wei L, Old M, Agrawal A, et al. One- year quality of life and functional outcomes of transoral robotic surgery for carcinomas of unknown primary. *Head Neck* 2017;39(8):1596–602.
- [37] Strojjan P, Ferlito A, Medina JE, Woolgar JA, Rinaldo A, Robbins KT, et al. Hinni ML, Mondin V, Shaha AR, Barnes L. Contemporary management of the lymph node metastases from an unknown primary to the neck: 1. A review of diagnostic approaches. *Head Neck* 2013;35:123–32.
- [38] Strojjan P, Ferlito A, Laendijk JA, Corry J, Woolgar JA, Rinaldo A, et al. Contemporary management of lymph node metastases from an unknown primary to the neck II. A review of therapeutic options. *Head Neck* 2013;35:286–93.
- [39] Cianchetti M, Mancuso AA, Amdur RJ, Werning JW, Kiwan J, Morris CG, et al. Diagnostic evaluation of squamous cell carcinoma metastatic to cervical lymph nodes from an unknown head and neck primary site. *Laryngoscope* 2009;119(12):2348–54.