

# Using three-dimensional average facial meshes to determine nasolabial soft tissue deformity in adult UCLP patients

Wong, Ka Wai Frank; Keeling, Andrew; Achal, Kulraj; Khambay, Balvinder

DOI:

[10.1016/j.surge.2018.04.006](https://doi.org/10.1016/j.surge.2018.04.006)

License:

Creative Commons: Attribution-NonCommercial-NoDerivs (CC BY-NC-ND)

*Document Version*

Peer reviewed version

*Citation for published version (Harvard):*

Wong, KWF, Keeling, A, Achal, K & Khambay, B 2018, 'Using three-dimensional average facial meshes to determine nasolabial soft tissue deformity in adult UCLP patients', *Surgeon*.  
<https://doi.org/10.1016/j.surge.2018.04.006>

[Link to publication on Research at Birmingham portal](#)

**Publisher Rights Statement:**

Published in The Surgeon on 04/06/2018

**General rights**

Unless a licence is specified above, all rights (including copyright and moral rights) in this document are retained by the authors and/or the copyright holders. The express permission of the copyright holder must be obtained for any use of this material other than for purposes permitted by law.

- Users may freely distribute the URL that is used to identify this publication.
- Users may download and/or print one copy of the publication from the University of Birmingham research portal for the purpose of private study or non-commercial research.
- User may use extracts from the document in line with the concept of 'fair dealing' under the Copyright, Designs and Patents Act 1988 (?)
- Users may not further distribute the material nor use it for the purposes of commercial gain.

Where a licence is displayed above, please note the terms and conditions of the licence govern your use of this document.

When citing, please reference the published version.

**Take down policy**

While the University of Birmingham exercises care and attention in making items available there are rare occasions when an item has been uploaded in error or has been deemed to be commercially or otherwise sensitive.

If you believe that this is the case for this document, please contact [UBIRA@lists.bham.ac.uk](mailto:UBIRA@lists.bham.ac.uk) providing details and we will remove access to the work immediately and investigate.

# **Using three-dimensional average facial meshes to determine nasolabial soft tissue deformity in adult UCLP patients**

Ka Wai Frank Wong

Paediatric Dentistry and Orthodontics, Faculty of Dentistry, The University of Hong Kong, 34 Hospital Road, Sai Ying Pun, Hong Kong.

Andrew Keeling

School of Dentistry, University of Leeds, Worsley Building, Leeds LS2 9NL

Kulraj Achal

School of Dentistry, University of Leeds, Worsley Building, Leeds LS2 9NL

Balvinder Khambay

Paediatric Dentistry and Orthodontics, Faculty of Dentistry, The University of Hong Kong, 34 Hospital Road, Sai Ying Pun, Hong Kong.

## **Address for correspondence**

Professor Balvinder S Khambay,  
Institute of Clinical Sciences,  
College of Medical and Dental Sciences,  
The School of Dentistry,  
University of Birmingham,  
5 Mill Pool Way,

Edgbaston, Birmingham, B5 7EG, UK.

Email: [b.s.khambay.1@bham.ac.uk](mailto:b.s.khambay.1@bham.ac.uk)

**Short running title:** Residual nasolabial soft tissue deformity in adult UCLP patients' prior to orthognathic surgery.

**Ethical Approval:** Approval was granted from the Institutional Review Board of the University of Hong Kong /Hospital Authority Hong Kong West Cluster (HKU/HA HKW IRB), UW 14-159 Version 1.1.

**\*Highlights (for review)**

Please provide 3 – 5 bullet-point highlights of the manuscript – see guide for authors

# **Using three-dimensional average facial meshes to determine nasolabial soft tissue deformity in adult UCLP patients**

## **Abstract**

*Background and purpose:* There is limited literature discussing the residual nasolabial deformity of adult patients prior to undergoing orthognathic surgery. The purpose of this study is to determine the site and severity of the residual nasolabial soft tissue deformity between adult unilateral cleft lip and palatal (UCLP) patients and a non-cleft reference group, prior to orthognathic surgery.

*Material and methods:* Sixteen adult male UCLP patients, who all received primary lip and palate surgery according to a standardised Hong Kong protocol were recruited for this study. Facial images of each individual were captured using three-dimensional (3D) stereophotogrammetry and compared to a previous published Hong Kong non-cleft reference group of 48 male adults. Using two-sample *t*-tests differences in linear and angular measurements and asymmetry scores were evaluated between the two groups. In addition a “conformed” average UCLP facial template was superimposed and compared to conformed average non-cleft reference group facial template.

Reproducibility of the measurements were assessed using Students paired *t*-tests and coefficients of reliability.

*Main findings:* Significant differences in linear and angular measurements and asymmetry scores were observed between the two groups ( $p < 0.05$ ). Adult UCLP patients showed significantly narrower nostril floor widths, longer columella length on the unaffected side, a wider nose, shorter cutaneous lip height, shorter upper lip length and shorter philtrum length. Prior to orthognathic surgery adult UCLP patients showed significantly more facial asymmetry. Superimposition of the average facial meshes clearly showed the site and severity of the deficiency in the x, y and z-directions.

*Conclusions:* Many of the nasolabial characteristics reported to be present in children following primary UCLP repair continue into adulthood. The detrimental soft tissue effects of orthognathic surgery for UCLP patients maybe different to non-cleft individuals; and as such the site and severity of the residual deformity should be assessed prior to surgery.

**Keywords:** UCLP; Stereophotogrammetry; average faces; three-dimensional

## **Introduction**

The incidence of cleft lip, cleft palate, and cleft lip and palate has been reported as 1.62 and between 1.45 to 4.04 clefts per 1000 individuals in Hong Kong and Chinese populations respectively.<sup>1,2</sup> Adult patients with CLP often show maxillary hypoplasia and secondary deformities in the nasolabial region. One of the final surgical interventions in adulthood for cleft lip and palate (CLP) patients is to consider orthognathic surgery to improve their facial aesthetics and function. This will require a second phase of treatment involving combined surgical and orthodontic treatment, as well as lip and nose revision.<sup>3</sup> The aetiology of the residual deformity is partly due to failure in facial development but also due to iatrogenic causes, i.e. surgical intervention and scarring.<sup>4,5</sup>

Over the last two decades, several non-invasive three-dimensional (3D) imaging modalities have been reported which provide a more objective measure of severity and outcome of facial appearance. These images combined with novel methods of assessment have increased the abundance of data available for analysis. The use of “average facial meshes” and dense correspondence in qualifying residual deformity has been previously reported in a group of 8-12 year old children with CLP compared to gender and age-matched controls.<sup>6</sup> At present only one previous study, based on non-invasive 3D imaging, indirectly quantified the residual deformity of repaired UCLP in adult patients, compared to a non-cleft control group.<sup>7</sup> The study was based on a Malay population and used “craniofacial proportion indices” derived from the combination of 18 linear measurements as an outcome measure. In total only 21 anthropometric soft tissue landmarks were used to describe the entire craniofacial complex.



Alternative methods that move away from assessing individual landmarks and use the entire facial mesh surface are based on “average facial templates”. These are produced by spatially aligning a given number of 3D facial mesh images mathematically to produce an average 3D facial template representative of the original group. Previous studies have reported on the use of 3D average faces to discriminate between males and females<sup>8</sup> and cleft and non-cleft children.<sup>9</sup> This method of analysis uses thousands of points or “corresponding landmarks” for comparison and provides a comprehensive anatomical description between two 3D facial surfaces.

Therefore the aim of this study was to determine the severity of the residual nasolabial soft tissue deformity of a group of adult unilateral cleft lip and palatal (UCLP) patients in Hong Kong prior to orthognathic surgery. The primary outcome measure was the difference in the alar base width between the UCLP group and a non-cleft reference group. The null hypothesis was there was no difference in the alar base width between the UCLP group and the non-cleft reference group. Secondary outcome measures included additional conventional linear and angular measurements and total facial asymmetry scores. In addition distance colour maps, based on anatomical correspondence in the x, y and z directions between the average faces were produced.

## **Materials and methods**

Approval was granted from the Institutional Review Board of the University of Hong Kong / Hospital Authority Hong Kong West Cluster (HKU/HA HKW IRB), UW 14-159  
Version 1.1.

### *Sample size calculation*

Based on the primary outcome measure, previous studies based on a Chinese racial group have reported a standard deviation of 2.92mm in alar base width in a group of UCLP patients.<sup>10</sup> With a significance level of 0.05 and power of 0.8 a minimum of 16 individuals would be required in each group to detect a difference of 3mm which was reported to be clinically significant.<sup>11</sup>

### *Cleft group selection*

The cleft sample consisted of 16 male UCLP Southern Chinese patients aged 18 years and over who were seen at the Faculty of Dentistry, University of Hong Kong between September 2013 and September 2014. All patients had previously attended a multi-disciplinary dentofacial-planning clinic where a treatment plan involving a combined orthodontic and surgical treatment was confirmed based on a clinical and radiological examination. Inclusion criteria included: patients were over 18 years of age, UCLP patients had previously been treated using a Tennison lip repair around 3 months of age, and soft and hard palate repair between the ages 18 and 24 months, using a two flap palatoplasty functional repair according to Perko. Either a plastic or an oral maxillofacial surgeon performed the operations. All patients had received an alveolar bone grafting (ABG) with no pre-surgical arch expansion and no previous orthognathic surgery. This was in-line with the protocol used in Hong Kong.<sup>12</sup>

### *Reference group*

The 3D facial images of a reference group had been previously collected and saved as Wavefront Object files (.OBJ) using the 3dMDface System (3dMD LLC, Atlanta,

GA).<sup>13</sup> For this study 48 male reference group images were used. In summary these individuals were of Southern Chinese ethnicity, 16 to 40 years of age, normal balanced facial profile, class I incisors, normal upper incisor show, no obvious facial asymmetry, no acquired or inherited dentofacial deformities, e.g., cleft, craniofacial syndrome, or posttraumatic deformity and no previous plastic, maxillofacial, orthognathic, or reconstructive surgery.

#### *Imaging technique*

All patients in the cleft group were imaged using the Di3D stereophotogrammetry system (Di4D, Dimensional Imaging Ltd, Hillington, Glasgow, UK) in a standardised manner. This involved the patient removing any glasses or facial jewellery and sitting upright at the correct distance from the camera system. The patients were all imaged in natural head position and with their lips in repose. Prior to capture the system was calibrated according to the manufactures instructions and all images were saved in .OBJ format.

#### *Nasolabial linear and angular measurements and total facial asymmetry scores*

As the UCLP group consisted of patients with either left or right-sided clefts; all the right-sided cleft images were flipped horizontally using MeshLab software (STI-CNR, Rome, Italy; <http://meshlab.sourceforge.net/>) to convert them into left UCLP. This resulted in a homogenous cleft type, all left UCLP for the ease of measurement and evaluation. Each image in turn, 16 UCLP and 48 reference images were imported into DiView (Dimensional Imaging Ltd) and 42 landmarks placed by a single operator (KFWF) to produce a landmark configuration, Table 1 and Figure 1. Based on the landmarks 17 linear and 2 angular measurements were generated by DiView

software. An asymmetry score were recorded based on previously published methodology,<sup>14</sup>. In summary this involved taking each 3D landmark configuration, duplicating the configuration, reflecting it around an arbitrary plane and using Procrustes alignment to produce the best-fit of the two configurations. Following this a new mean landmark configuration was produced and the root mean square distance between the corresponding 42 landmarks calculated. The closer to zero the score, the more symmetrical the face, Table 2 and Figure 2.

#### *Average facial template construction*

Each 3D facial image was imported into DiView together with a generic mesh. Twenty four landmarks were place on the 3D facial image and the corresponding landmarks were placed on the generic mesh, constructed of 3072 vertices. Using the “shape transfer function” in DiView the generic mesh was conformed to the 3D facial image to produce a “conformed mesh”, this procedure is described briefly below and in greater detail elsewhere.<sup>15</sup> All the conformed UCLP meshes and conformed reference images were saved in .OBJ format. Using MorphAnalysr software (<http://cherry.dcs.aber.ac.uk/morphanalyser>) an individualised average facial was produced for the UCLP group and the reference group. This involved generalised Procrustes superimposition with translation, rotation and scaling using all the points in the conformed mesh as a 3D landmark configuration.<sup>6</sup> Using in-house developed software the x, y and z distances between the same points on each mesh (anatomical correspondence after conformation) were depicted as a distance colour map.

## **Analysis**

### *Reproducibility study*

Twenty-five percent of all images in the UCLP and reference groups were randomly selected. Each image was landmarked twice by the same operator (KFWF), 2 weeks apart, and the differences in x, y and z landmark coordinates between the first and second digitisation were used for analysis. Systematic error was assessed using paired *t*-tests and random error assessed by coefficients of reliability.

### *Nasolabial linear and angular measurements*

In total 17 linear and 2 angular measurements were used in this study. The data was found to be normally distributed following a Shapiro-Wilk test. A two-sample *t*-test was used to determine if there were any statistically significant differences in the 19 measurements between the reference group and the UCLP group and the non-cleft reference group.

### *Facial asymmetry scores*

A two-sample *t*-test was used to determine if there were any statistically significant differences in the mean asymmetry score between the reference group and the UCLP group and the reference group ( $p < 0.05$ ).

## **Results**

In total 16 UCLP patients were included, 5 with RUCLP and 11 with LUCLP (mean age  $19.3 \pm 2.5$  years). The reference group consisted of 48 subjects (mean age  $24.2 \pm 0.4$  years).

### *Reproducibility study*

No systematic errors were observed. All coefficients of reliability were above 90%. All landmarks were digitised to within  $\pm 0.5$  mm.

### *Nasolabial linear and angular measurements*

Compared with the reference group, UCLP (left side) subjects showed a significantly narrower right and left nostril floor width, wider nasal base width, longer columella length on the right side, shorter cutaneous lip height, shorter left and right upper lip long length, shorter left and right upper short length and shorter right philtrum length, Table 3. With the exception of nostril floor width these differences are likely to be clinically significant as the 95% confidence intervals are 3.0mm and above.

### *Facial asymmetry scores*

There was a significant difference in the mean asymmetry scores between the reference group and the UCLP group ( $p=0.001$ ). The UCLP subjects showed significantly more facial asymmetry than the reference group, Table 4.

## **Distance colour maps**

### *Comparison between the normal average face and the left UCLP group*

Figure 3 shows superimposition of the 3D facial images and the pronounced differences in the UCLP group. Assessment horizontal or transverse (x-axis) shows the increase anatomical width of the nose together with the displacement of the right ala to the unaffected side (blue), and depression of the left alar rim (yellow). There was also paranasal deficiency and accompanying flatness of the left (cleft side) infra-orbital and malar region again indicated by the yellow colour.

In the vertical direction (y-axis) the cleft group had a decreased upper lip length in the philtrum upper left lip region of around 3 mm. The cheek region on the cleft side was more superiorly positioned in the vertical direction.

Assessment in the antero-posterior (AP) direction (z-axis) showed a significant soft tissue defect in the middle third of the upper lip and upper lip cutaneous region. The defect was more pronounced in the left philtrum and lip region which would be site of the repaired cleft lip. The AP defect was greater than 6mm (blue) with the maximum soft tissue deficiency located in the latter region. The rest of the upper lip showed an AP soft tissue deficiency in comparison to the normal average Hong Kong Chinese face. Moreover the left nostril was depressed posteriorly by over 6mm. There also appeared to be reduction in the length of the columella (over 6mm). Overall the nasal tip had a reduced projection of around 3mm (light blue). These findings show significant soft tissue deficiency in the nasal and upper lip region that is asymmetric and skewed towards the unaffected side.

## **Discussion**

This study utilised a clinically acceptable and validated method of 3D technology i.e. stereophotogrammetry, to capture the topological features of the face.<sup>16</sup> Alternative technologies are available i.e. laser scanning, which are equally acceptable.<sup>17</sup> The cleft cohort in the present study could be regarded as “historical“ as their primary surgery was approximately 17 years earlier. The surgical technique at the time, and currently, is based on a standardised protocol to which all patients were treated and surgeons trained too, this resulted in a homogeneous pre-surgical cleft group.

To date the majority of studies involving the assessment of the aesthetic outcome of residual facial deformities in cleft lip and palate patients have focused on the relatively short term effects of surgical repair; concentrating on the outcome of primary repair of the nasolabial complex in children.<sup>6,18,19</sup> Even though cleft care begins at birth treatment extends well into adult life with several major surgical interventions, the last of which is generally orthognathic surgery. The aim of which is to correct the underlying dentoskeletal deformity to improve both function and aesthetics. The comparison of adult Asian cleft individuals to a contemporaneous noncleft adult group and the use of 3D average facial meshes in adult cleft patients is unique and provides novel information quantifying the site and severity of the dentofacial disharmony immediately prior to orthognathic surgery which may have surgical implications. It is noteworthy that the 3D images taken using two different stereophotogrammetry systems. However both systems have been shown to reliable and accurate to around 0.2mm.<sup>20,21</sup>

Several methods have been described to assess the morphology of the nasolabial region between cleft groups and control groups.<sup>22</sup> The use of conformed meshes and anatomical correspondence allows a more detailed analysis of the morphological difference between facial surfaces. This overcomes the shortcomings of using landmark based analysis or a combination of landmark-based and shape analysis.<sup>18,23</sup> This is because the 3D mesh creates a surface topography that will allow for accurate assessment of disparities in areas that might otherwise be difficult to detect with 2D measurements.<sup>24,25</sup> The results of the present study are similar to previous studies fully acknowledging the different age groups and ethnic backgrounds. Interestingly even taking these into account there are still commonality



across studies; with UCLP patients presenting with wider noses which were asymmetric and deviated to the unaffected side. This has been reported in 3 and 10 years old White children, 4 year old Japanese patients and has now also been found in 19 year old Hong Kong adult patients.<sup>6,9,18,26</sup>

Retro-positioning of the nasal tip in UCLP patients has been reported in some studies<sup>9</sup> but not in others.<sup>27</sup> This difference may be an accurate reflection of the clinical situation but could be due to the method of analysis. Studies have used either linear measurements i.e. columella to pronasale or subnasale to pronasale or distance colour maps to report differences in nasal projection. Clinicians should be aware that the distances used to generate the colour maps are not based on anatomical distances i.e. pronasale on the cleft image to pronasale on the control image. Instead the software uses pronasale on one image and the nearest point the second image, which may not be anatomical pronasale with its position being highly dependent on the degree of nasal asymmetry (Figure 4).<sup>28,29</sup> Therefore questioning the validity of previous findings using this method. This was not the case for the present study as both linear measurements and the distance map in the z-direction, based on the conformed meshes and anatomical correspondence, confirmed nasal retro-position in the UCLP group of around 1mm, which was not statistically, and is probably not clinically, significant. The posterior positioning of the nasal tip has also been reported in adults Malaysians following UCLP repair.

The nasolabial angle in the present study was not statistically different between the UCLP and reference group. The posterior positioned upper lip should have increased the nasolabial angle, however it was also accompanied by a more

posterior and inferiorly positioned nasal tip which resulted in a “normal” nasolabial angle. The superimposition of the UCLP and average facial meshes clearly shows that in the UCLP group the upper lip is flatter or more posteriorly positioned. This is a similar finding of both previous studies on pre-surgical orthognathic adult UCLP patients. This method of analysis and depiction shows that the scar is the site of the largest discrepancy in the anterior-posterior (AP) direction (z-direction) and the deficiency extends laterally effecting the majority if the upper lip. This is accompanied by flatness in the cheek and zygoma area, which is in agreement with the study based on 10 year old white children. The mid-face hypoplasia often associated with the Asian population may contribute to these findings. It would also seem that the deficiency present at childhood progresses into adulthood.<sup>30</sup> These findings would not have previously been quantifiable as previous landmarks have been confined close to the midline only.

Increased nostril width on the cleft side was not a finding of the present study which is surprising given it is commonly reported in children. The differences in nasal morphology between Asians and Whites together with continued nasal growth may provide possible explanations. The superimposition of the average meshes of these two groups again shows the left sided (cleft side) alar rim is in a favourable position laterally (x-direction) but posteriorly positioned (z-direction) whilst the right side (non-cleft) is displaced further laterally but in a favourable AP position. This gives the impression that the nose is “buckled; being displaced inwards on the cleft side and flared laterally on the noncleft side. This is similar to previously reported findings in the 3 year old Scottish children UCLP group. The superimpositions show that despite alveolar bone grafting there is still reduced support for the alar base and the nasal

sill. This is seen on both sides but is more evident on the cleft side. The nasal sill on the cleft side has less lateral support (x-direction), is more inferior (y-direction) and positioned further posteriorly (z-direction).

Previous studies have indicated that asymmetry in the midface, detracts from self-perceived facial appearance and perception by others.<sup>31</sup> As in previous studies the present study found that the normal reference group were not symmetrical and that there was an increased global asymmetry in the UCLP.<sup>18,32</sup> The distance colour map clearly shows the largest defect in an AP direction (z-direction) to be localised to the philtrum, with lateral involvement of the rest of the upper lip, cheeks and zygoma. These findings were similar to those found in 10 year old white children in the UK.<sup>9</sup>

The findings of this study have important clinical implications regarding the surgical correction of the underlying skeletal position.<sup>33</sup> Following cleft surgery and repair it is common for patients to develop a marked class III skeletal pattern mainly due to maxillary hypoplasia. Correction will inevitably require a maxillary advancement procedure possibly with mandibular surgery. Given the pre-existing soft tissue deficiencies highlighted in the present study careful consideration at the time of surgical prediction planning is essential. For instance skeletal maxillary advancement is associated with some detrimental soft tissue changes for this group of individuals including further widening of the anatomical nose width and the potential for further lateral displacement of the non-cleft side alar cartilage. Upper lip advancement will also be more difficult to predict due to the scarring and as shown in this study the smaller lateral dimensions of the mouth. A recent study providing a comprehensive description of the 3D facial changes following Le Fort I osteotomies

has shown changes in the upper lip and wider surrounding area.<sup>34</sup> This may have implications for correcting the retro-positioned lip since this is a well demarcated deficiency, correcting this problem may cause over-advancement in regions on the face that are acceptable in UCLP adults i.e. the paranasal region. The 3D changes associated with these regions are AP and lateral expansion following Le Fort I osteotomies. A possible solution is to modify the surgical procedure, for instance a conventional Le Fort I osteotomy on the non-cleft side together with a high level osteotomy on the cleft side. This would help address the depressed left paranasal region. Taking into account the detrimental nasal changes associated with maxillary advancement required to reposition the retrusive maxilla adjunctive procedures may be required. Either reducing the magnitude of maxillary advancement by performing a bimaxillary procedure and / or adjunctive surgical procedures for correction of the nasal deformities i.e. open rhinoplasty.

In conclusion, prior to orthognathic surgery UCLP patients had more facial asymmetry than the reference group. UCLP patients had wider noses and reduced facial dimensions in terms of cutaneous lip height, upper lip length and philtrum length compared to the reference group. The use of conformed average facial meshes is a clinically representative visual method of describing the site and severity of UCLP residual deformities. This information provides the surgical team with a novel method of visualisation for diagnosing areas of the face which are within “normal” limits and those that require correction. Given the existing knowledge of surgical effects, this can be used to manage patient expectations and aid in planning the surgical correction. The conventional use of angular and linear measurements based on two-dimensional images does not provide this level of detail.

**Declarations**

**Funding:** None

**Competing Interests:** None

**Patient Consent:** N/A

## References

1. Stevenson AC, Johnston HA, Stewart MI, Golding DR. Congenital malformations. A report of a study of series of consecutive births in 24 centres. *Bull World Health Organ* 1966;**34** Suppl:9-127.
2. Vanderas AP: Incidence of cleft lip, cleft palate, and cleft lip and palate among races: a review. *Cleft Palate J* 1987;**24**:216-25.
3. Chigurupati R: Orthognathic surgery for secondary cleft and craniofacial deformities. *Oral Maxillofac Surg Clin North Am* 2005;**17**:503-17.
4. Capelozza Filho L, Normando AD, daSilva Filho OG: Isolated influences of lip and palate surgery on facial growth: comparison of operated and unoperated male adults with UCLP. *Cleft Palate Craniofac J* 1996;**33**:51-6.
5. Liao YF, Mars M: Long-term effects of palate repair on craniofacial morphology in patients with unilateral cleft lip and palate. *Cleft Palate Craniofac J* 2005;**42**:594-600.
6. Bugaighis I, Mattick CR, Tiddeman B, Hobson R: 3D facial morphometry in children with oral clefts. *Cleft Palate Craniofac J* 2014;**51**:452-61.
7. Othman SA, Ahmad R, Asi SM, Ismail NH, Rahman ZA: Three-dimensional quantitative evaluation of facial morphology in adults with unilateral cleft lip and palate, and patients without clefts. *Br J Oral Maxillofac Surg* 2014;**52**:208-13.
8. Bugaighis I, Mattick CR, Tiddeman B, Hobson R: Three-dimensional gender differences in facial form of children in the North East of England. *Eur J Orthod* 2013;**35**:295-304.
9. Bugaighis I, Tiddeman B, Mattick CR, Hobson R: 3D comparison of average faces in subjects with oral clefts. *Eur J Orthod* 2014;**36**:365-72.

10. Zreaqat M, Hassan R, Halim AS. Facial dimensions of Malay children with repaired unilateral cleft lip and palate: a three dimensional analysis. *Int J Oral Maxillofac Surg* 2012;**41**:783-8.
11. Othman SA, Aidil Koay NA. Three-dimensional facial analysis of Chinese children with repaired unilateral cleft lip and palate. **Sci Rep.** 2016;**6**:31335.
12. Lam FSV, Bendeus M, Wong RWK: A multidisciplinary team approach on cleft lip and palate management. *Hong Kong Dent J* 2004;**4**:38-45.
13. Cheung LK, Chan YM, Jayaratne YS, Lo J: Three-dimensional cephalometric norms of Chinese adults in Hong Kong with balanced facial profile. *Oral Surg Oral Med Oral Pathol Oral Radiol Endod*; 2011;**112**:e56-73.
14. Bock, MT and Bowman AW: On the measurement and analysis of asymmetry with applications to facial modelling. *Journal of the Royal Statistical Society: Series C (Applied Statistics)* 2006;**55**:77-91.
15. Cheung MY, Almukhtar A, Keeling A, Hsung TC, Ju X, McDonald J, Ayoub A, Khambay BS: The Accuracy of Conformation of a Generic Surface Mesh for the Analysis of Facial Soft Tissue Changes. *PLoS One* 2016;**11**:e0152381.
16. Khambay B, Nairn N, Bell A, Miller J, Bowman A, Ayoub AF. Validation and reproducibility of a high-resolution three-dimensional facial imaging system. *Br J Oral Maxillofac Surg* 2008;**46**:27-32.
17. Kook MS, Jung S, Park HJ, Oh HK, Ryu SY, Cho JH, Lee JS, Yoon SJ, Kim MS, Shin HK. A comparison study of different facial soft tissue analysis methods. *J Craniomaxillofac Surg* 2014;**42**:648-56.

18. Bell A, Lo TW, Brown D, Bowman AW, Siebert JP, Simmons DR, Millett DT, Ayoub AF: Three-dimensional assessment of facial appearance following surgical repair of unilateral cleft lip and palate. *Cleft Palate Craniofac J* 2014; **51**:462-71.
19. Duffy S, Noar JH, Evans RD, Sanders R: Three-dimensional analysis of the child cleft face. *Cleft Palate Craniofac J* 2000;**37**:137-44.
20. Lubbers HT, Medinger L, Kruse A, Gratz KW, Matthews F: Precision and accuracy of the 3dMD photogrammetric system in craniomaxillofacial application *J Craniofac Surg* 2010;**21**:763-7.
21. Khambay B, Nairn N, Bell A, Miller J, Bowman A, Ayoub AF: Validation and reproducibility of a high-resolution three-dimensional facial imaging system *Br J Oral Maxillofac Surg* 2008;**46**:27-32.
22. Kuijpers MA, Chiu YT, Nada RM, Carels CE, Fudalej PS: Three-dimensional imaging methods for quantitative analysis of facial soft tissues and skeletal morphology in patients with orofacial clefts: a systematic review. *PLoS One* 2014;**9**:e93442.
23. Ghoddousi H, Edler R, Haers P, Wertheim D, Greenhill D: Comparison of three methods of facial measurement. *Int J Oral Maxillofac Surg*; 2007;**36**:250-8.
24. Verhoeven TJ, Coppens C, Barkhuysen R, Bronkhorst EM, Merckx MA, Bergé SJ, Maal TJ: Three dimensional evaluation of facial asymmetry after mandibular reconstruction: validation of a new method using stereophotogrammetry. *Int J Oral Maxillofac Surg* 2013;**42**:19-25.



25. Claes P, Walters M, Vandermeulen D, Clement JG: Spatially-dense 3D facial asymmetry assessment in both typical and disordered growth. *J Anat* 2011; **219**:444-55.
26. Yamada T, Mori Y, Minami K, Mishima K, Tsukamoto Y: Surgical results of primary lip repair using the triangular flap method for the treatment of complete unilateral cleft lip and palate: a three-dimensional study in infants to four-year-old children. *Cleft Palate Craniofac J* 2002; **39**:497-502.
27. Ayoub A, Garrahy A, Millett D, Bowman A, Siebert JP, Miller J, Ray A: Three-dimensional assessment of early surgical outcome in repaired unilateral cleft lip and palate: Part 1. Nasal changes. *Cleft Palate Craniofac J* 2011; **48**:571-577.
28. Tiddeman B, Rabey G, Duffy N: Synthesis and transformation of three-dimensional facial images. *IEEE Eng Med Biol Mag* 1999; **18**:64-9.
29. Khambay B, Ullah R: Current methods of assessing the accuracy of three-dimensional soft tissue facial predictions: technical and clinical considerations. *Int J Oral Maxillofac Surg* 2015; **44**:132-8.
30. Al-Rudainy D, Ju X, Mehendale F, Ayoub A. Assessment of facial asymmetry before and after the surgical repair of cleft lip in unilateral cleft lip and palate cases. *Int J Oral Maxillofac Surg* 2017; **17**:31605-3.
31. Meyer-Marcotty P, Kochel J, Boehm H, Linz C, Klammert U, Stellzig-Eisenhauer A: Face perception in patients with unilateral cleft lip and palate and patients with severe Class III malocclusion compared to controls. *J Craniomaxillofac Surg* 2011; **39**:158-63.
32. Bugaighis I, Mattick CR, Tiddeman B, Hobson R: 3D asymmetry of operated children with oral clefts. *Orthod Craniofac Res* 2014; **17**:27-7.

33. Verzé L, Bianchi FA, Ramieri G: Three-dimensional laser scanner evaluation of facial soft tissue changes after LeFort I advancement and rhinoplasty surgery: patients with cleft lip and palate vs patients with nonclefted maxillary retrognathic dysplasia (control group). *Oral Surg Oral Med Oral Pathol Oral Radiol* 2014;**117**:416-23.
34. Almukhtar A, Ayoub A, Khambay B, McDonald J, Ju X: State-of-the-art three-dimensional analysis of soft tissue changes following Le Fort I maxillary advancement. *Br J Oral Maxillofac Surg* 2016; S0266-4356: 30107-3.

## Table Legends

- Table 1** Landmark definitions (red indicates additional landmarks for conformation).
- Table 2** Linear and angular measurements (Bell et al., 2014) and there diagrammatic representation.
- Table 3** Mean difference for linear and angular measurements between the UCLP group and the reference group, together with the 95% CI and results of the independent t-test (\* indicates significant difference  $p < 0.05$ ).
- Table 4** Mean asymmetry score of the UCLP and the reference groups, together with the 95% CI and results of the independent t-test (\* indicates significant difference  $p < 0.05$ ).

**Table 1** Landmark definitions (red indicates additional landmarks for conformation)

Number	Abbreviation	Landmark	Anatomical Location
1	G	Glabella	Most prominent point between the eyebrows, in the midline
2	N	Nasion	Midline between and slightly above en-en, maximum concavity of nasal bridge in profile
3,4	exR exL	Exocanthion right and left	Outer skin junction, where upper eyelid meets lower; most lateral extent of lower eyelid
5,6	enR enL	Endocanthion right and left	Lower and innermost point at junction between upper and lower eyelids
7	Prn	Pronasale	Most prominent point on nose tip selected where normal is perpendicular to frontal plane in profile view
8,9	acR acL	Alar crest right and left	Most lateral point of nose in groove between ala and facial skin
10,11	alR alL	Alare right and left	Point of maximum convexity of ala on the alar ridge
12,13	sbalR sbalL	Subalare right and left	Point where inner rim of nostril joins upper lip skin; where this is a wide area lowermost point on curve
14,15	cR cL	Columella right and left	Highest point of the columella (reflected onto nostril), where nostril starts to curve round
16,17	alOiR alOiL	Alare inner right and left	Midpoint on inner margin of nostril, between sbal and Columella
18,19	alOoR alOoL	Alare outer right and left	Point on outer ala, opposite alOi point (narrowest lateral alar width)
20, 21	snOR snOL	Edge of columellar base right and left	Narrowest and lowest point of columella on inner nostril margin / most lateral aspect of columella
22	Sn	Subnasale	Midpoint of columella, maximum concavity at junction of lip skin and columella
23, 24	chR chL	Cheilion right and left	Most lateral extent of vermilion border of lower lip
25, 26	cphR cphL	Crista philtri right and left	Point at lower most extent of philtral ridge, junction of white roll and vermilion of upper lip
27	Ls	Labiale superius	Point at maximum concavity of philtrum, junction of white roll and vermilion

			of upper lip
28	Stos	Stomion superioris	Point on lower most extent of vermilion border of upper lip, in the midline
29	Stoi	Stomion inferioris	Point on upper margin of vermilion border lip, in the midline
30	Li	Labiale inferius	Lowermost midline point on vermilion border of the lower lip
31	SI	Sublabialis (soft tissue B point)	Point of maximum concavity at lowermost extent lower lip skin, in the midline
32	Pog	Pogonion	Most anterior point in midline of chin, marked with normal perpendicular to frontal plane in profile view
33	Me	Menton	Lowest point on chin curvature
34, 35	mulR mulL	Anchor points on upper lip	Midpoint between ch and cph on upper lip
36, 37	mlIR mlIL	Anchor points on lower lip	Midpoint between ch and cph on lower lip
38, 39	mexchR mexchL	Anchor points on mid-face	Midpoint between ex and ch
40, 41	anchR anchL	Anchor points on ears	Curvature of the lobule of ear inserts into facial skin
42	mllip	Anchor point on lower lip in midline	Most prominent point on lower lip, in midline

**Table 2** Linear and angular measurements (Bell et al., 2014) and there diagrammatic representation.

Measurements	Landmarks	Diagrammatic representation
Nasal base width	sbaR-sbaL	1
Width of R nostril floor	sbaR-Sn	
Width of L nostril floor	sbaL-Sn	2
Nasal height	N-Sn	5
Nasal projection	Sn-Prn	8
Anatomical width of nose	acR-acL	4
Nasolabial angle	Prn-Sn-Ls	7
Nasal tip angle	N-Prn-Sn	6
Length of R columella	cR-Sn	
Length of L columella	cL-Sn	3
Upper cutaneous lip height	Sn-Ls	9
R upper lip long length	Ls-chR	11
L upper lip long length	Ls-chL	
R upper lip short length	cphR-chR	10
L upper lip short length	cphL-chL	
R philtrum width	cphR-Ls	
L philtrum width	cphL-Ls	12
R philtrum length	cphR-Sn	
L philtrum length	cphL-Sn	13

**Table 3** Mean difference for linear and angular measurements between the UCLP group and the reference group, together with the 95% CI and results of the independent *t*-test (\* indicates significant difference  $p < 0.05$ ).

Measurement	Landmarks	Reference Mean	UCLP Mean	Mean difference	95% confidence interval of mean difference		p-value
					Lower limit	Upper limit	
Nasal base width (mm)	sbalR-sbalL	23.6	22.3	1.4	-0.2	3.0	0.086
Width of R nostril floor (mm)	sbalR-Sn	13.4	12.1	1.3	0.4	2.2	0.007*
Width of L nostril floor (mm)	sbalL-Sn	12.6	11.7	0.9	0.0	1.8	0.048*
Nasal height (mm)	N-Sn	52.5	52.1	0.4	-1.5	2.3	0.664
Nasal projection (mm)	Sn-Prn	18.6	19.1	-0.6	-1.7	0.5	0.317
Anatomical width of nose (mm)	acR-acL	41.1	43.9	-2.8	-4.3	-1.2	0.001*
Nasolabial angle (degrees)	Prn-Sn-Ls	116.4	114.1	2.3	-2.8	7.4	0.366
Nasal tip angle (degrees)	N-Prn-Sn	104.8	106.2	-1.3	-4.2	1.5	0.353
Length of R columella (mm)	cR-Sn	11.6	13.6	-2.0	-2.9	-1.0	0.001*
Length of L columella (mm)	cL-Sn	10.6	11.5	-0.9	-2.0	0.3	0.124
Upper cutaneous lip height (mm)	Sn-Ls	16.5	14.1	2.4	1.0	3.8	0.001*
R upper lip long length (mm)	Ls-chR	33.4	29.6	3.8	2.3	5.3	0.0001*
L upper lip long length (mm)	Ls-chL	33.3	28.2	5.1	3.6	6.6	0.0001*
R upper lip short length (mm)	cphR-chR	28.2	24.2	4.0	2.7	5.4	0.0001*
L upper lip short length (mm)	cphL-chL	28.3	21.8	6.5	5.2	7.8	0.0001*
R philtrum width (mm)	cphR-Ls	8.0	7.4	0.6	-0.2	1.4	0.157
L philtrum width (mm)	cphL-Ls	7.6	8.3	-0.7	-1.7	0.3	0.171
R philtrum length (mm)	cphR-Sn	15.6	13.7	1.9	0.6	3.2	0.005*
L philtrum length (mm)	cphL-Sn	15.6	15.6	0.0	-1.2	1.2	0.995

**Table 4** Mean asymmetry score of the UCLP and the reference groups, together with the 95% CI and results of the independent *t*-test (\* indicates significant difference  $p < 0.05$ ).

	Normal	UCLP	Mean difference	95% CI for mean difference		p-value
				Lower limit	Upper limit	
Mean asymmetry score	0.8	2.3	-1.5	-1.8	-1.3	0.001*



Figure 1  
[Click here to download high resolution image](#)

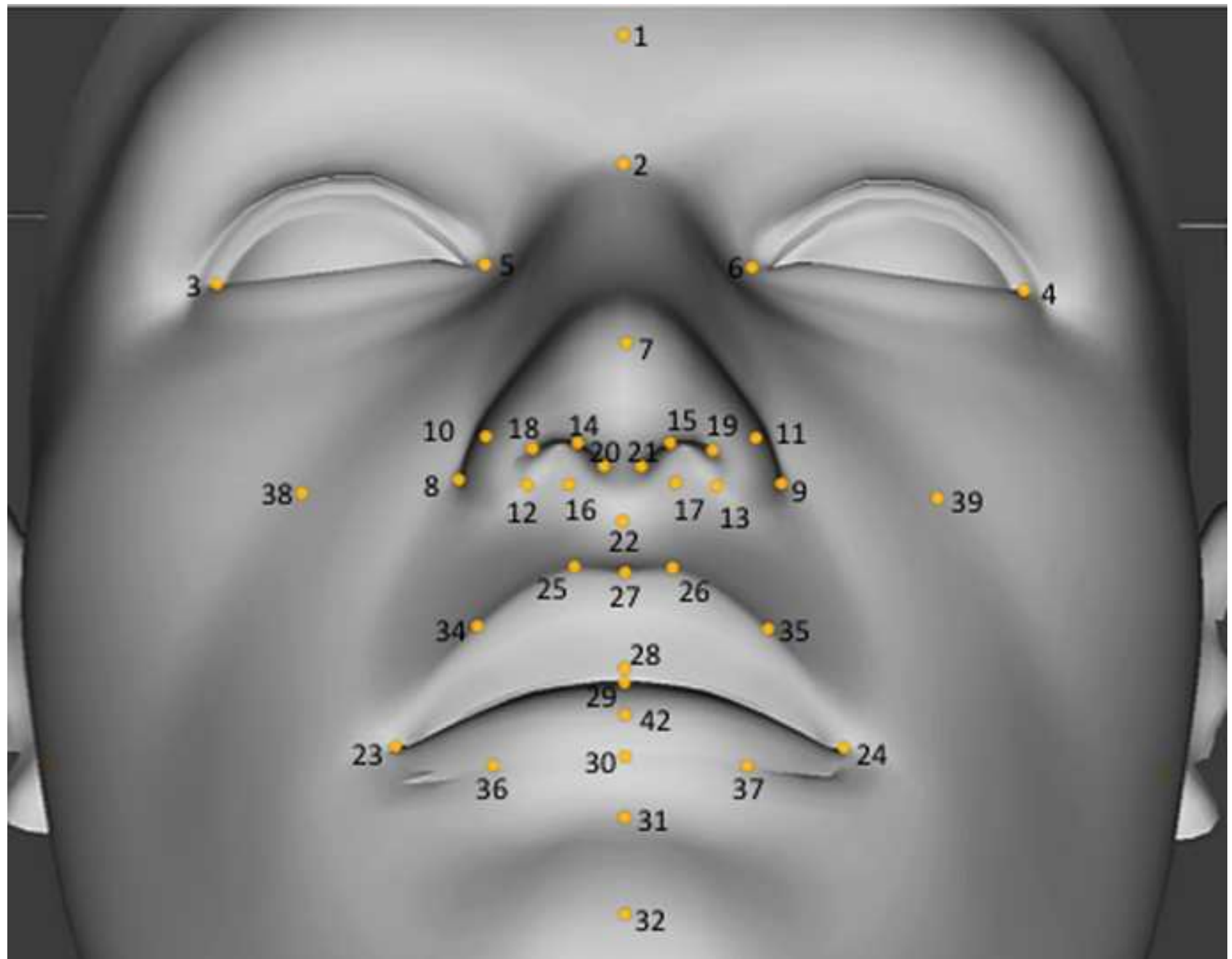
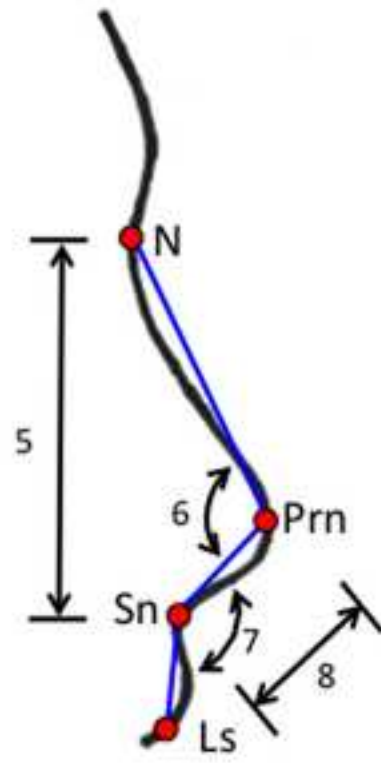
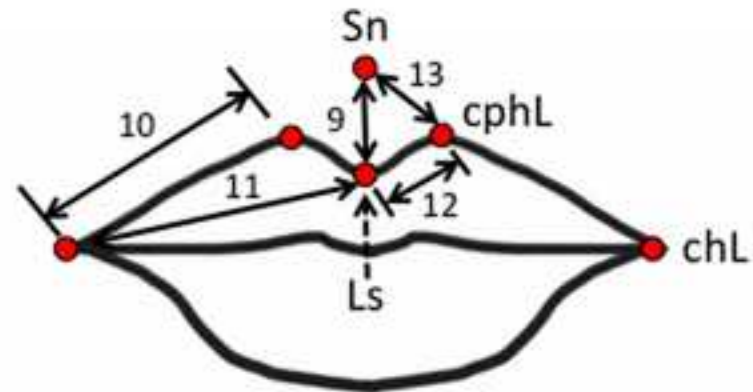
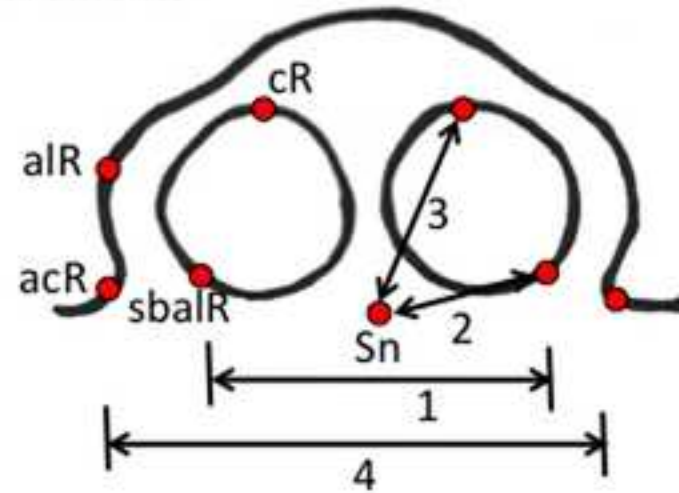


Figure 2  
[Click here to download high resolution image](#)



Nasolabial measurements

Nasal measurements

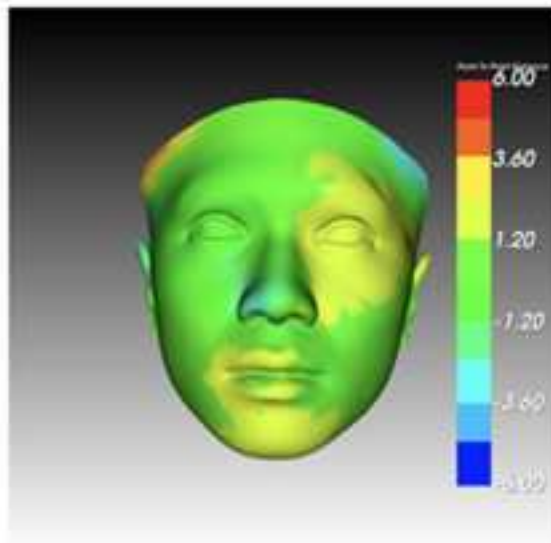


Lip measurements

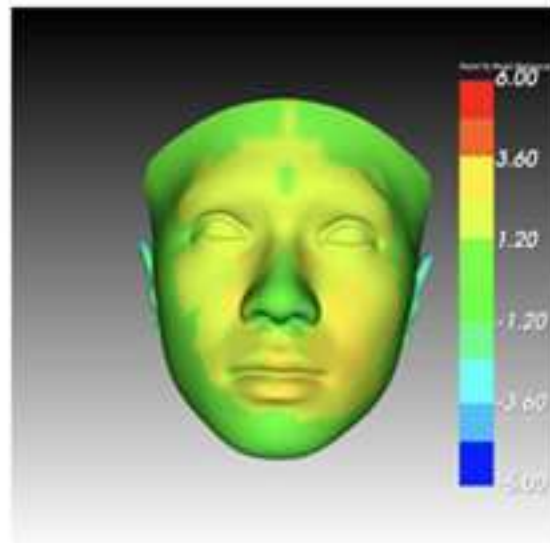
**Figure 3**  
[Click here to download high resolution image](#)



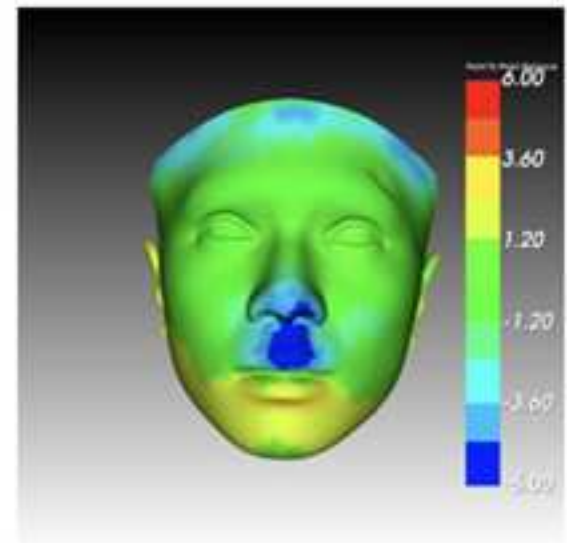
UCLP average face (red wire frame) superimposed over average reference face (grey)



Transverse  
(x-direction)

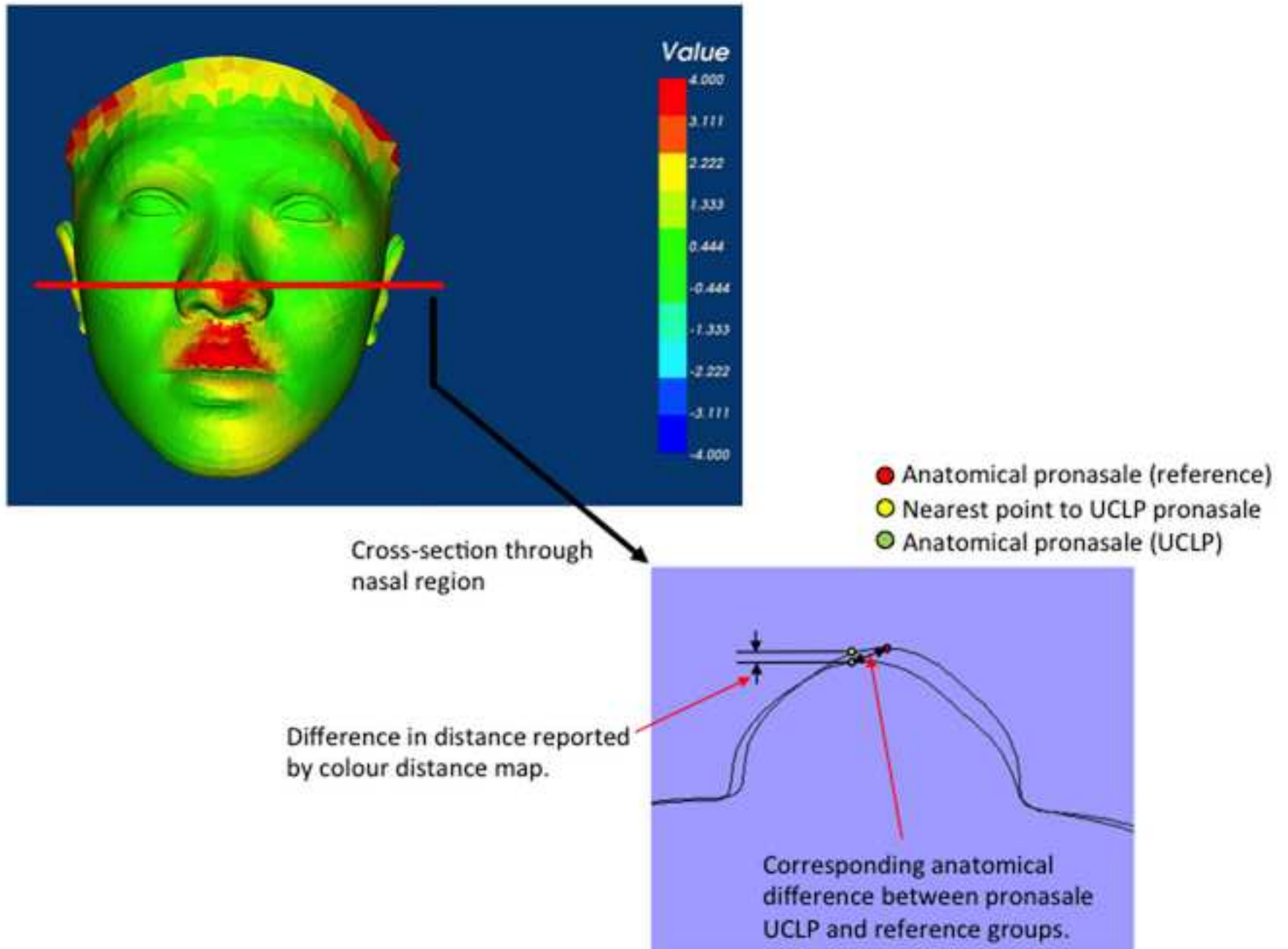


Vertical  
(y-direction)



Anterior-posterior  
(z-direction)

Figure 4  
[Click here to download high resolution image](#)



**Figure legends**

**Figure 1** 42 landmarks placed on each of the 3D images.

**Figure 2** 17 linear, 2 angular measurements used to analyse the images.

**Figure 3** Superimposition of the normal 3D average face and the average left UCLP group.

**Figure 4** Differences between anatomical and nearest point analysis of facial images using the average and left UCLP images as examples.