

Prevention of coronal discoloration induced by regenerative endodontic treatment in an ex vivo model

Shokouhinejad, Noushin; Khoshkhounejad, Mehrfam; Alikhasi, Marzieh; Bagheri, Parisa; Camilleri, Josette

DOI:

[10.1007/s00784-017-2266-0](https://doi.org/10.1007/s00784-017-2266-0)

License:

None: All rights reserved

Document Version

Peer reviewed version

Citation for published version (Harvard):

Shokouhinejad, N, Khoshkhounejad, M, Alikhasi, M, Bagheri, P & Camilleri, J 2018, 'Prevention of coronal discoloration induced by regenerative endodontic treatment in an ex vivo model', *Clinical Oral Investigations*, vol. 22, no. 4, pp. 1725–1731. <https://doi.org/10.1007/s00784-017-2266-0>

[Link to publication on Research at Birmingham portal](#)

Publisher Rights Statement:

This is a post-peer-review, pre-copyedit version of an article published in *Clinical Oral Investigations*. The final authenticated version is available online at: <http://dx.doi.org/10.1007/s00784-017-2266-0>

General rights

Unless a licence is specified above, all rights (including copyright and moral rights) in this document are retained by the authors and/or the copyright holders. The express permission of the copyright holder must be obtained for any use of this material other than for purposes permitted by law.

- Users may freely distribute the URL that is used to identify this publication.
- Users may download and/or print one copy of the publication from the University of Birmingham research portal for the purpose of private study or non-commercial research.
- User may use extracts from the document in line with the concept of 'fair dealing' under the Copyright, Designs and Patents Act 1988 (?)
- Users may not further distribute the material nor use it for the purposes of commercial gain.

Where a licence is displayed above, please note the terms and conditions of the licence govern your use of this document.

When citing, please reference the published version.

Take down policy

While the University of Birmingham exercises care and attention in making items available there are rare occasions when an item has been uploaded in error or has been deemed to be commercially or otherwise sensitive.

If you believe that this is the case for this document, please contact UBIRA@lists.bham.ac.uk providing details and we will remove access to the work immediately and investigate.

Clinical Oral Investigations

Prevention of coronal discoloration induced by regenerative endodontic treatment in an ex vivo model --Manuscript Draft--

Manuscript Number:	CLOI-D-17-00960R1
Full Title:	Prevention of coronal discoloration induced by regenerative endodontic treatment in an ex vivo model
Article Type:	Original Article
Corresponding Author:	Josette Camilleri University of Malta Msida, MALTA
Corresponding Author Secondary Information:	
Corresponding Author's Institution:	University of Malta
Corresponding Author's Secondary Institution:	
First Author:	Josette Camilleri
First Author Secondary Information:	
Order of Authors:	Josette Camilleri Noushin Shokouhinejad Mehrfam Khoshkhounejad Marzieh Alikhasi Parisa Bagheri
Order of Authors Secondary Information:	
Funding Information:	
Abstract:	<p>Objectives The aim of this study was to assess the effect of sealing the pulp chamber walls with a dentin bonding agent (DBA) on prevention of discoloration induced by regenerative endodontic procedures (REPs) in an ex vivo model.</p> <p>Materials and methods Ninety-six bovine incisors were prepared and randomly divided into two groups. In one group, the pulp chamber walls was sealed with DBA before placement of triple antibiotic paste (TAP) containing minocycline inside the root canals; but in the other group, DBA was not applied. After 4 weeks, the root canals were filled with human blood and each group was then randomly divided into 4 subgroups (n = 12) according to the endodontic cements placed over the blood clot (ProRoot MTA, OrthoMTA, RetroMTA, or Biodentine). The color changes (ΔE) were measured at different steps. The data were analyzed using t-test and two-way ANOVA.</p> <p>Results The specimens in which dentinal walls of pulp chamber were sealed with DBA showed significantly less coronal discoloration at each step of regenerative treatment ($p < 0.001$). However, application of DBA did not prevent the coronal color changes. Sealing the blood clot with different endodontic cements did not result in significant difference in coronal discoloration ($p > 0.05$).</p> <p>Conclusions Sealing the pulp chamber walls before insertion of TAP decreased coronal discoloration following REP using different endodontic cements. However, the specimens in which pulp chamber was covered with DBA even showed clinically perceptible discoloration.</p> <p>Clinical relevance: Discoloration of teeth undergoing REPs is an unfavorable outcome. Considering the significant contribution of TAP containing minocycline to the coronal tooth discoloration even after sealing the pulp chamber walls, the revision of current guidelines in relation to the use of TAP with minocycline might need to be revised.</p>
Response to Reviewers:	Dear Prof. About, Thank you very much for your kind review of the manuscript (Ms. No. CLOI-D-17-

00960) entitled "prevention of coronal discoloration induced by regenerative endodontic treatment in an ex vivo model". I would like to submit the revised version considering all comments point by point.

Reply to associate editor comments

Concern of the associate editor: The authors might extend the discussion to clearly indicate if they recommend the application of DBA to decrease the discoloration in this treatment procedure. If so, they may need to mention the possible consequences of applying resin containing materials (which are known to be toxic) on the underlying stem cells.

Our response: Thanks for your valuable comments. Your concern was considered in the revised manuscript at the end of the discussion section (page 9, line 12)

Revised text: Based on the results of this study, application of DBAs may be recommended to seal the dentinal tubules of the pulp chamber; especially when minocycline-containing TAP is used as the intracanal antimicrobial agent in endodontic regenerative treatments. However, there may be concerns about the toxic effect of different bonding systems on the stem cells; especially in unpolymerized forms [34, 35]. Given that in REPs the blood clot as a rich source of stem cells is attempted to be placed below the CEJ and remain limited to the root canal space, the possible risk of direct contact between stem cells and dentin bonding agents, which are applied and already completely cured before the stage of blood entry into the root canal system, would be the least. Thus in order to prevent the contact between DBAs and stem cells, along with providing enough space for endodontic cements to be placed over the blood clot, it recommends that the blood clot be limited to a few millimeters below CEJ level. Moreover, further researches would be advisable to access DBAs with the least toxic effect on the stem cells used in regenerative treatments.

Concern of the associate editor :..... associated to the each step of treatment
.....remove the

Our response: Thank you for your attention. It was removed.

Revised text: (page 9, line 8) "It is worth mentioning that in endodontic regenerative treatments, the color changes associated to each step of treatment....."

Reply to reviewer # 1

Concern of the reviewer: Maybe the second application of dentin bonding agent prior to placing the blood should be better justified and described in the method (that just placed it over the old layer? they sandblasted? they etched?).

Our response: In order to deal with the possibility of previous DBA layer impairment during temporary filling material removal, DBA was reapplied on the access cavity walls in the same manner used for the first application of DBA. The inner surfaces of the pulp chamber in this group were etched for 15 sec with 35% phosphoric acid (Vococid, Voco, Germany) and rinsed. The dentin bonding agent (Solobond M, Voco, Germany) was applied to the etched surfaces and cured for 20 sec. It was deleted from the discussion section (page 7, line 24) and described in the methods and materials in detail (page 4, line 6).

Revised text: (page 4, line 6) "In order to deal with the possibility of previous DBA layer impairment during temporary filling material removal, DBA was reapplied on the access cavity walls in the same manner described for the first application of DBA." In the materials and methods (page 4, line 6), the reason for reapplication of DBA before blood insertion and its method was added. Therefore, this part was deleted from the discussion section (page 7, line 9).

Reply to reviewer # 2

Concern of the reviewer: Triple antibiotics were filled into the specimens, and then the specimens were incubated at 37°C in fully saturated humidity for 4 weeks.

This methodology is not co-related to clinical procedure. Medication of triple antibiotics is usually no more than 2 weeks. Please show the results about antibiotics treatment in time dependent manner (1, 2, or 3 weeks). This result is important to know the relationship between the period of antibiotics treatment in the pulp space and discoloration of dentin walls. The result may indicate the methodology of combination with DBA to prevent discoloration by antibiotics (minocycline) in clinic.

Our response: The revascularization technique which was first introduced by Banchs &

Trope [1] reported TAP dressing for 4 weeks. Since then, a large number of clinical studies, case reports and case series have been published concerning regenerative endodontic treatment which reveals a broad range of variety in treatment protocol. In a data analysis of clinical protocols used in regenerative endodontic procedures, Kontakiotis et al. [2] showed that 32 out of 41 studies on regenerative endodontic therapy used TAP with minocycline for ≥ 3 weeks and in only 4 studies it was used for 1-2 weeks. Furthermore, AAE considerations for endodontic regenerative procedure recommend a low concentration of TAP for 1-4 weeks. There are limited information regarding the effect of increasing the time on the severity of color changes following root canal disinfection with minocycline-containing TAP. In an in vitro study on dentin discoloration induced by TAP and other antibiotics, Porter et al. [3] showed no significant difference between ΔE values after 28 days of storage when compared with 21 and 14 days; however, there were significant difference between the teeth color seen in day 0 and the other period of times (day 1, 7, 14, 21, and 28). Kim et al. [4] also showed no significant difference between mean changes in E^* , L^* , a^* , and b^* values after 7 days compared with 14 days of storage. However, they analyzed the color change for 2 weeks. Therefore, we treated the root canals with TAP for 4 weeks according to the previous studies. As the current study was not aimed to evaluate the TAP induced coronal color changes at different time intervals, the color changes were assessed after a 4 week medication period with TAP and at the end of this step of regenerative treatment (S1). Based on your valuable comments, discussion section was revised (page 7, line 3).

Banchs F, Trope M (2004) Revascularization of immature permanent teeth with apical periodontitis: new treatment protocol? J Endod 30:196–200.

Kontakiotis EG, Filippatos CG, Tzanetakis GN, Agrafioti A (2015) Regenerative endodontic therapy: a data analysis of clinical protocols. J Endod 41:146-154.

Porter ML, Münchow EA, Albuquerque MT, Spolnik KJ, Hara AT, Bottino MC (2016) Effects of Novel 3-dimensional Antibiotic-containing Electrospun Scaffolds on Dentin Discoloration. J Endod 42:106-112

Kim JH, Kim Y, Shin SJ, Park JW, Jung IY (2010) Tooth discoloration of immature permanent incisor associated with triple antibiotic therapy: a case report. J Endod 36:1086-1091.

Revised text: (page 7, line 3) In the present study, the root canals were medicated with TAP for 4 weeks. The technique for revascularization introduced by Banchs and Trope [24] included TAP dressing for 4 weeks. Since then, a large number of clinical studies, case reports and case series have been published concerning regenerative endodontic treatments, revealing a broad range of variety in treatment protocol. In a data analysis of clinical protocols used in REPs, Kontakiotis et al. [11] showed that the root canals were medicated with minocycline-containing TAP for ≥ 3 weeks in most studies. Furthermore, AAE considerations for endodontic regenerative procedure recommend a low concentration of TAP for 1-4 weeks. In the current study, the clinical observation of specimens which were not sealed with DBA revealed severe coronal discoloration within the first 2 weeks of antibiotic therapy. In an in vitro study on dentin discoloration induced by TAP and other antibiotics, Porter et al. [25] showed no significant difference between ΔE values after 28 days of storage when compared with 21 and 14 days. Kim et al. [6] also showed no significant difference between mean changes in E^* , L^* , a^* , and b^* values after 7 days compared with 14 days of storage. In the present study, coronal discoloration was clinically visible 24 hours after filling the root canals with TAP in the specimens in which the access cavity walls did not sealed with DBA. This is in accordance with the finding of studies that showed discoloration began to appear 24 hours after insertion of TAP [6, 25]. Therefore, reducing the duration of antibiotic therapy from 21-28 days to 1-2 weeks or even 24-48 hours does not seem to be completely effective in preventing coronal discoloration [6, 25].

Sincerely yours,
Dr. Josette Camilleri

[Click here to view linked References](#)

1
2
3
4
5
6
7
8
9
10
11
12
13
14
15
16
17
18
19
20
21
22
23
24
25
26
27
28
29
30
31
32
33
34
35
36
37
38
39
40
41
42
43
44
45
46
47
48
49
50
51
52
53
54
55
56
57
58
59
60
61
62
63
64
65

Prevention of coronal discoloration induced by regenerative endodontic treatment in an *ex vivo* model

Noushin Shokouhinejad^{1,2}, Mehrfam Khoshkhounejad¹, Marzieh Alikhasi^{3,4}, Parisa Bagheri¹, Josette Camilleri⁵

¹ Department of Endodontics, School of Dentistry, Tehran University of Medical Sciences, Tehran, Iran

² Dental Research Center, Dentistry Research Institute, Tehran University of Medical Sciences, Tehran, Iran

³ Dental research center, Dental Implant Research Center, Dentistry Research Institute, Tehran University of Medical Sciences, Tehran, Iran

⁴ Department of Prosthodontics, School of Dentistry, Tehran University of Medical Sciences, Tehran, Iran

⁵ School of Dentistry, College of Clinical and Medical Sciences, University of Birmingham, Edgbaston, Birmingham, UK

Corresponding author:

Prof. Josette Camilleri B.Ch.D., M.Phil., Ph.D., FICD, FADM, FIMMM, FHEA

School of Dentistry,

Institute of Clinical Sciences,

College of Medical and Dental Sciences,

The University of Birmingham,

5 Mill Pool Way,

Edgbaston, Birmingham, B5 7EG

E-mail address: J.Camilleri@bham.ac.uk

Tel: +44 121 4665506

1
2
3
4
5
6
7 **Abstract**
8
9

10 *Objectives* The aim of this study was to assess the effect of sealing the pulp chamber walls with a dentin bonding agent
11 (DBA) on prevention of discoloration induced by regenerative endodontic procedures (REPs) in an *ex vivo* model.
12
13

14
15 *Materials and methods* Ninety-six bovine incisors were prepared and randomly divided into two groups. In one group,
16 the pulp chamber walls was sealed with DBA before placement of triple antibiotic paste (TAP) containing minocycline
17 inside the root canals; but in the other group, DBA was not applied. After 4 weeks, the root canals were filled with
18 human blood and each group was then randomly divided into 4 subgroups ($n = 12$) according to the endodontic
19 cements placed over the blood clot (ProRoot MTA, OrthoMTA, RetroMTA, or Biodentine). The color changes (ΔE)
20 were measured at different steps. The data were analyzed using t-test and two-way ANOVA.
21
22
23
24
25
26
27

28 *Results* The specimens in which dentinal walls of pulp chamber were sealed with DBA showed significantly less
29 coronal discoloration at each step of regenerative treatment ($p < 0.001$). However, application of DBA did not
30 completely prevent the clinically perceptible coronal color change. Sealing the blood clot with different endodontic
31 cements did not result in significant difference in coronal discoloration ($p > 0.05$).
32
33
34
35
36

37 *Conclusions* Sealing the pulp chamber walls before insertion of TAP decreased coronal discoloration following REP
38 using different endodontic cements but did not prevent it. However, the specimens in which pulp chamber was covered
39 with DBA even showed clinically perceptible discoloration.
40
41
42
43

44 *Clinical relevance* Discoloration of teeth undergoing REPs is an unfavorable outcome. Considering the significant
45 contribution of TAP containing minocycline to the coronal tooth discoloration even after sealing the pulp chamber
46 walls, the revision of current guidelines in relation to the use of TAP with minocycline might need to be revised.
47
48
49
50

51 **Key Words:** Biodentine, calcium silicate-based materials, coronal discoloration, dentin bonding agent, mineral
52 trioxide aggregate, regenerative endodontic treatment
53
54
55
56
57
58
59
60
61
62
63
64
65

1
2
3
4 **Introduction**
5

6
7 Regenerative endodontic procedures (REPs) generally involve disinfection of the root canal followed by introduction
8
9 of a blood clot or platelet rich plasma/platelet rich fibrin, which is sealed with a bioactive material such as white
10
11 mineral trioxide aggregate (MTA) [1]. These procedures result in thickening of the root canal walls and continuing
12
13 root development [2-5]. However, coronal discoloration of teeth that have undergone REPs is an unfavorable outcome
14
15 [6-8].
16

17
18 A broad range of differences in clinical protocols is seen in the studies related to REPs. The "Regenerative Endodontics
19
20 Committee" founded by the American Association of Endodontists (AAE) has recommended some considerations for
21
22 a regenerative procedure [9] which has been lately revised in 2016 [1]. Furthermore, the European Society of
23
24 Endodontology (ESE) has developed a position statement regarding revitalization procedures in 2016 [10].
25

26
27 It has been shown that the most popular medicament in REPs is triple antibiotic paste (TAP) composed of
28
29 ciprofloxacin, metronidazole, and minocycline [11]. Although ESE position statement suggests a nondiscoloring
30
31 calcium hydroxide as an intracanal medicament [10], TAP has been still recommended by AAE clinical considerations
32
33 [1]. The ability of antibiotic combinations to eliminate bacteria within dentinal tubules [2, 12] has been the main
34
35 reason for the widespread use of TAP in REPs. On the other hand, TAP has been associated with significant tooth
36
37 discoloration [6, 13].
38

39
40 Although antibiotic compounds, especially those containing minocycline, have been attributed as the major cause of
41
42 discoloration, entrance of evoked bleeding into the root canal and placement of MTA just below the cemento-enamel
43
44 junction (CEJ) for sealing the blood clot can be considered as the other factors that underline the crown discoloration.
45
46 In a data analysis of clinical protocols, it has been reported that MTA was used as the intracanal coronal barrier in
47
48 85% of the clinical articles. Several studies have reported undesirable tooth discoloration after the use of MTA [14-
49
50 18]. Other calcium silicate-based materials such as Biodentine (Septodont, Saint Maur des Fossés, France), OrthoMTA
51
52 and RetroMTA (BioMTA, Seoul, Korea) have been introduced to overcome the shortcomings of MTA including
53
54 coronal discoloration.
55

56
57 In order to minimize the risk of crown discoloration, AAE considerations for REPs suggests the sealing of pulp
58
59 chamber in case of using TAP, as well as covering the blood clot with bioceramics or other calcium silicate-based
60

1
2
3
4 materials (e.g., Biodentine) as alternatives to MTA [1]. Therefore, this study aimed to assess the preventive role of a
5
6 dentin bonding agent on the coronal discoloration via sealing the pulp chamber walls, in an *ex vivo* model of
7
8 regenerative endodontic procedure using triple antibiotic paste as the intracanal medicament and different endodontic
9
10 cements (ProRoot MTA, OrthoMTA, RetroMTA, and Biodentine) for coronal sealing of blood clot.
11

12 **Materials and methods**

13
14
15
16 Ninety-six bovine mandibular incisors having almost identical crown and root size from animals of approximately the
17
18 same age were selected. Teeth were disinfected by immersion in 0.5% Chloramine T solution for 48 hours and then
19
20 stored in normal saline solution until use.
21

22 **Experimental setup**

23
24
25
26 The apical portion of each specimen was resected to obtain a standardized root length of 15 mm below the labial CEJ.
27
28 In order to seal the apical openings with composite resin material, the apical 4 mm of the root canals and total
29
30 surrounding dentin of cross sectional surface were etched for 15 sec with 35% phosphoric acid (Vococid, Voco,
31
32 Germany) and rinsed. A dentin bonding agent (Solobond M, Voco, Germany) was applied to the etched surfaces and
33
34 cured for 20 sec. Composite resin material (Grandio, Voco, Germany) was then placed incrementally and cured using
35
36 a LED curing light (Valo, Ultradent, Products Inc, South Jordan, USA) for 40 sec. After that, endodontic access
37
38 cavities were prepared and the root canals were shaped using #3 to 6 Gates-Glidden drills. The root canals were
39
40 irrigated with 20 mL 1.5% NaOCl followed by 20 mL 17% EDTA each for 5 min. After the root canal space was
41
42 dried using paper points, the specimens were randomly divided into two groups ($n = 48$) as follows:
43

44
45 *Group 1: DBA.* The inner surfaces of the pulp chamber in this group were etched for 15 sec with 35% phosphoric acid
46
47 (Vococid, Voco, Germany) and rinsed. The dentin bonding agent (Solobond M, Voco, Germany) was applied to the
48
49 etched surfaces and cured for 20 sec.
50

51
52 *Group 2: No DBA.* The inner surfaces of the pulp chamber were not sealed with DBA.
53

54
55 In the next step, triple antibiotic mixture was prepared by mixing equal proportions of ciprofloxacin, metronidazole,
56
57 and minocycline (1:1:1) with sterile water to a final concentration of 0.1 mg/mL and was delivered into the root canals
58
59 via a syringe to ensure that the solution was confined to the root canal below the labial CEJ. After that, the access
60
61

1
2
3
4 cavities were sealed with a temporary filling material (Zonalin, Kemdent, UK). The specimens were then incubated
5
6 at 37°C in fully saturated humidity for 4 weeks. Then temporary coronal seal were removed and the root canals were
7
8 irrigated with 20 mL 17% EDTA for 5 min and dried with paper points. In group 1, **in order to deal with the possibility**
9
10 **of previous DBA layer impairment during temporary filling material removal, DBA was reapplied on the access cavity**
11 **walls in the same manner described for the first application of DBA. DBA was reapplied to the inner surfaces of pulp**
12 **chamber.** In both groups, the root canals were then filled with human blood using a syringe until 4 mm below the
13
14 facial CEJ. Whole fresh human blood was collected from healthy consented volunteers by a trained individual and
15
16 approved by a panel from the Tehran University of Medical Sciences Ethical Committee (Ethics code:
17
18 IR.TUMS.VCR.REC.1395.649). A blood clot was allowed to form for 15 minutes. After that, a resorbable collagen
19
20 matrix (Bone Protect Fleece, Dentsply, Germany) was placed over the blood clot. The specimens of each group were
21
22 then randomly assigned to 1 of 4 experimental subgroups ($n = 12$) and labeled according to the applied endodontic
23
24 cements: ProRoot MTA, OrthoMTA, RetroMTA, and Biodentine. Each material was prepared according to the
25
26 manufacturers' instructions and placed on the top of the collagen matrix in a homogeneous layer of about 3 mm
27
28 underneath the facial CEJ. A cotton pellet wetted with saline was then placed over the endodontic materials and the
29
30 cavity was temporarily sealed with Coltosol (Coltene, Altstätten, Switzerland). The specimens were incubated at 37°C
31
32 in fully saturated humidity for 72 hours. Subsequently, the access cavities were filled with composite resin material,
33
34 A1 shade (Grandio, Voco, Germany). The shade of the composite was matched to the coronal tooth structure measured
35
36 with a spectrophotometer (Vita Easyshad; VITA Zahnfabrik, Bad Säckingen, Germany).
37
38
39
40

41 **Tooth color assessment**

42
43
44 For reproducible color assessment, a window measuring 3 × 3 mm was created on the cervical and middle thirds of
45
46 the crowns using a needle-shaped diamond bur in such a way that two thirds of its height was in the cervical and one
47
48 third was in the middle third of the tooth crown [18]. A spectrophotometer (Vita Easyshad; VITA Zahnfabrik, Bad
49
50 Säckingen, Germany) was used to measure the L*, a* and b* values. L* indicates the value of lightness-darkness, a*
51
52 indicates greenness-redness and b* indicates blueness-yellowness. The device was calibrated before use for each
53
54 specimen. The color measurements were taken at the following 5 steps:
55
56

57 S0: Prior to placement of antibiotic mixture as the baseline color

58
59
60 S1: Four weeks after placement of antibiotic mixture
61
62

1
2
3
4 S2: Immediately after placement of endodontic cements
5
6

7 S3: Immediately after permanent filling of the access cavity
8
9

10 S4: Four months after permanent filling of the access cavity
11
12

13 Color measurements were performed 3 times inside the marked window on each for every reading, and the mean value
14 of three measurements was calculated. The color change (ΔE) between the baseline (S0) and the other steps (S1, S2,
15 S3, and S4) was calculated using the following formula:
16
17
18

$$\Delta E = [(\Delta L)^2 + (\Delta a)^2 + (\Delta b)^2]^{1/2}$$

19
20
21
22

23 Photographs were taken of the specimens at each treatment step using a digital camera for informal visual comparison.
24
25

26 **Statistical analysis**

27

28 Data were evaluated using SPSS software (PASW Statistics 18; SPSS Inc, Chicago, IL). The effect of bonding agent
29 on the color changes at the end of antibiotic therapy (S1) was analyzed using t-test. The effect of dentin bonding agent
30 and the type of endodontic cement on color change at the end of S2, S3, and S4 compared to baseline color (S0) was
31 analyzed using two-way ANOVA. The level of statistically significant difference was set at $p < 0.05$.
32
33
34
35
36

37 **Results**

38
39

40 The mean values for the color changes in each subgroup are shown in Fig. 1. The results of this study showed that
41 sealing the dentinal walls of the access cavity with DBA significantly decreased crown discoloration at any step ($p <$
42 0.001). Antibiotic therapy made the most contribution to coronal discoloration in both groups with or without DBA
43 compared to the other treatment steps. Considering the type of endodontic cements, there was no significant difference
44 between the coronal discoloration in subgroups of four endodontic cements neither at the end of treatment (S3) nor
45 after the four-month follow-up (S4) ($p > 0.05$).
46
47
48
49
50
51
52

53 Although sealing the access cavity walls with DBA significantly decreased the coronal discoloration, all specimens
54 exhibited a clinically perceptible discoloration ($\Delta E \geq 3.3$) at the end of each step. Photos of a specimen from each
55 group with or without the application of DBA are shown in Fig. 2.
56
57
58
59
60
61
62
63
64
65

1
2
3
4 **Discussion**
5
6

7 Crown discoloration has been reported as an unfavorable outcome following REPs. This is the first study to assess the
8 role of sealing the dentinal walls of the pulp chamber using a dentin bonding agent (DBA) before the initiation of
9 regenerative endodontic procedures in preventing coronal discoloration using an *ex vivo* model for regeneration. In
10 the present study, bovine incisors were selected to evaluate coronal discoloration. It has been shown that bovine teeth
11 are suitable substitute for human teeth in assessing the crown discoloration [13, 19, 20]. The use of human teeth in *ex*
12 *vivo* studies is limited due to ethical issues, difficulty to obtain adequate restorations or caries free specimens, and
13 insufficient flat labial surface for color measurement [21]. Furthermore, it is easy to create a model for immature teeth
14 with thin dentinal walls and wide canal lumens with bovine teeth.
15
16
17
18
19
20
21
22

23
24 In the current study, sealing the dentinal tubules with DBA before placement of TAP into the root canals significantly
25 decreased the coronal discoloration at the end of the antibiotic therapy as well as at the completion of treatment. But
26 it is important to mention that DBA did not completely prevent the clinically perceptible color change of the crown
27 induced by TAP. This result is in accordance with Kim et al. [6] who showed that the use of an adhesive dentin
28 bonding (AdheSE; Ivoclar Vivadent, Schaan, Liechtenstein) on the dentinal walls of the root canals before insertion
29 of TAP reduced the overall color change of the crown but did not completely prevent it. However, it seems to be more
30 reasonable to apply DBA on the access cavity walls rather than into the root canals in REPs because of the handling
31 problems associated with using DBA within the root canals. Moreover, covering the dentin which surrounds the canal
32 might compromise the outcome of regenerative endodontic treatment.
33
34
35
36
37
38
39
40
41
42

43 TAP containing minocycline is the most popular of all intracanal medicaments in endodontic regenerative treatments.
44 It has been shown that minocycline and TAP containing minocycline are associated with substantial tooth staining [6,
45 13]. Minocycline chelates the calcium ions and stains the dentin [22]. It has been found that even after irrigation using
46 different techniques; about 88% of the TAP remained in the root dentinal walls to a depth greater than 350 μ m [23].
47
48
49
50

51 ~~In the present study, coronal discoloration was clinically visible 24 hours after filling the root canals with TAP in the~~
52 ~~specimens in which the access cavity walls did not sealed with DBA. This is in accordance with the finding of studies~~
53 ~~that showed discoloration began to appear 24 hours after insertion of TAP [6, 24]. Therefore, reducing the duration of~~
54 ~~antibiotic therapy from 21-28 days to 24-48 hours, as recommended by some researchers [2, 12], does not seem to be~~
55 ~~completely effective in preventing coronal discoloration [6].~~ In the present study, the root canals were medicated with
56
57
58
59
60
61

1
2
3
4 TAP for 4 weeks. The technique for revascularization introduced by Banchs and Trope [24] included TAP dressing
5
6 for 4 weeks. Since then, a large number of clinical studies, case reports and case series have been published concerning
7
8 regenerative endodontic treatments, revealing a broad range of variety in treatment protocol. In a data analysis of
9
10 clinical protocols used in REPs, Kontakiotis et al. [11] showed that the root canals were medicated with minocycline-
11
12 containing TAP for ≥ 3 weeks in most studies. Furthermore, AAE considerations for endodontic regenerative
13
14 procedure recommend a low concentration of TAP for 1-4 weeks. In the current study, the clinical observation of
15
16 specimens which were not sealed with DBA revealed severe coronal discoloration within the first 2 weeks of antibiotic
17
18 therapy. In an *in vitro* study on dentin discoloration induced by TAP and other antibiotics, Porter et al. [25] showed
19
20 no significant difference between ΔE values after 28 days of storage when compared with 21 and 14 days. Kim et al.
21
22 [6] also showed no significant difference between mean changes in E^* , L^* , a^* , and b^* values after 7 days compared
23
24 with 14 days of storage. In the present study, coronal discoloration was clinically visible 24 hours after filling the root
25
26 canals with TAP in the specimens in which the access cavity walls did not sealed with DBA. This is in accordance
27
28 with the finding of studies that showed discoloration began to appear 24 hours after insertion of TAP [6, 25].
29
30 Therefore, reducing the duration of antibiotic therapy from 21-28 days to 1-2 weeks or even 24-48 hours does not
31
32 seem to be completely effective in preventing coronal discoloration [6, 25].
33
34

35
36 Another step in regenerative endodontic procedure is to induce bleeding and formation of a blood clot in the root
37
38 canal followed by placement of endodontic cements below the CEJ for sealing the blood clot. ~~In the present study,~~
39
40 ~~before insertion of blood into the canals, DBA was reapplied on the access cavity walls in order to deal with the~~
41
42 ~~possibility of previous DBA layer impairment during temporary filling material removal.~~ In this study, the blood was
43
44 inserted into the canals using a syringe to the limit of 4 mm below the labial CEJ. However, in some clinical situations,
45
46 it may be difficult to control the level of blood in the root canal and confine it to the ideal level; which is 3-4 mm
47
48 below the gingival margin. Therefore, the dentinal walls of pulp chamber might be contaminated with blood.
49
50 Discoloration of tooth structure induced by blood has been shown by many studies [14, 18, 2526, 2627]. Penetration
51
52 of erythrocytes into the tooth structure [14] and accumulation of hemoglobin and hemein molecules within dentinal
53
54 tubules following hemolysis of erythrocytes [2728] are among the possible mechanisms of tooth discoloration in
55
56 REPs.
57
58
59
60
61
62
63
64
65

1
2
3
4 Several studies have revealed the unfavorable discoloration of tooth structure induced by calcium silicate-based
5 materials [14-18]. The composition of a material is of great importance in its discoloration potential. The resultant
6 discoloration depends on metal constituents such as bismuth, iron, aluminum, and magnesium. Possible mechanisms
7 of tooth discoloration are related to the oxidation of the iron content [14], oxidation of bismuth oxide [28, 29, 30],
8 and interference of bismuth oxide with dentin collagen [21]. Calcium silicate-based materials with alternative
9 radiopacifiers such as calcium zirconia complex, zirconium oxide, or tantalum oxide are available clinically. It has
10 been shown that discoloration potential of materials which do not include bismuth oxide in their formulation (e.g.,
11 RetroMTA, Biodentine, and Neo MTA Plus) was significantly lower than that of materials containing bismuth oxide
12 (e.g., ProRoot MTA) [15, 26, 30-32, 27, 31-33]. However, those mentioned studies did not evaluate the discoloration
13 potential of materials in the presence of blood contamination. The results of the present study showed no significant
14 difference between the discoloration potential of ProRoot MTA, OrthoMTA, RetroMTA, and Biodentine neither in
15 DBA nor in no DBA groups at the end of the treatment and at a four-month evaluation. In the present study, although
16 endodontic cements were placed over a collagen matrix to avoid apical displacement of the material, the cements were
17 approximately in contact with blood. The results of the current study are in agreement with those of previous study
18 that showed no significant difference between the coronal discoloration induced by ProRoot MTA, OrthoMTA, and
19 Biodentine in the presence of blood contamination [18]. It has been shown that blood contamination significantly
20 exacerbated discoloration associated with calcium silicate-based materials containing bismuth oxide or other
21 radiopacifiers [14, 18, 25, 26]. One hypothesis put forward to explain the exacerbation of tooth discoloration in the
22 presence of blood would be the absorption and hemolysis of erythrocytes to calcium silicate-based materials which
23 can cause the discoloration of the material and tooth structure [14, 25, 26]. In the recent study, another explanation for
24 similar findings with ProRoot MTA and its recommended alternatives by the AAE clinical considerations might be
25 the extreme discoloration potential of TAP which may mask the effect of different endodontic cements on the color
26 change.

27
28
29
30
31
32
33
34
35
36
37
38
39
40
41
42
43
44
45
46
47
48
49
50
51
52 The application of DBA on the dentinal walls of the pulp chamber would decrease the interaction between
53 minocycline/dentin and bismuth oxide/collagen as well as the entrance of erythrocytes into dentinal tubules, leading
54 to less coronal discoloration following regenerative endodontic treatment. Furthermore, coverage of access cavity
55 walls with DBA makes them to be more easily cleaned in case of contamination with TAP or blood.
56
57
58
59
60
61
62
63
64
65

1
2
3
4 It is worth mentioning that in endodontic regenerative treatments, the color changes associated to ~~the~~ each step of
5
6 treatment could not be measured per se because of the presence of the color change induced in the previous treatment
7
8 steps. Therefore the results of this study cannot be simply compared with those of some other studies which have
9
10 evaluated the tooth discoloration caused by calcium silicate-based materials or intracanal medicaments.

11
12
13 Based on the results of this study, application of DBAs may be recommended to seal the dentinal tubules of the pulp
14
15 chamber; especially when minocycline-containing TAP is used as the intracanal antimicrobial agent in endodontic
16
17 regenerative treatments. However, there may be concerns about the toxic effect of different bonding systems on the
18
19 stem cells; especially in unpolymerized forms [34, 35]. Given that in REPs the blood clot as a rich source of stem cells
20
21 is attempted to be placed below the CEJ, the possible risk of direct contact between stem cells and dentin bonding
22
23 agents, which are applied on the pulp chamber walls and already completely cured before the stage of blood entry into
24
25 the root canal system, would be the least. Thus in order to prevent the contact between DBAs and stem cells, along
26
27 with providing enough space for endodontic cements to be placed over the blood clot, it recommends that the blood
28
29 clot be limited to a few millimeters below CEJ level. Moreover, further researches would be advisable to access DBAs
30
31 with the least toxic effect on the stem cells used in regenerative treatments.
32
33

34 **Conclusions**

35
36 Taken together, sealing the dentinal tubules of pulp chamber before application of TAP containing minocycline into
37
38 the root canal led to a significantly less tooth discoloration. However, application of DBA did not completely prevent
39
40 the clinically perceptible color change. Sealing the blood clot even with bioceramics and non bismuth oxide containing
41
42 calcium silicate-based materials in teeth treated with TAP containing minocycline did not resolve the problem of
43
44 discoloration. Considering the significant contribution of minocycline-containing TAP to the coronal tooth
45
46 discoloration, the current guidelines in relation to the use of TAP with minocycline as an intracanal medicament might
47
48 need to be revised.
49
50

51 **Acknowledgments**

52
53
54 This study was supported by Tehran University of Medical Sciences (grant no: 32011). The authors wish to thank
55
56 Dr. MJ. Kharrazifard for his assistance in statistical analysis.
57
58
59
60
61
62
63
64
65

1
2
3
4
5
6
7
8
9
10
11
12
13
14
15
16
17
18
19
20
21
22
23
24
25
26
27
28
29
30
31
32
33
34
35
36
37
38
39
40
41
42
43
44
45
46
47
48
49
50
51
52
53
54
55
56
57
58
59
60
61
62
63
64
65

Compliance with ethical standards

Conflict of interest The authors declare that they have no conflict of interest.

Funding This study was funded by Tehran University of Medical Sciences (grant number: 32011).

Ethical approval This study was approved by a panel from the Tehran University of Medical Sciences Ethical Committee (Ethics code: IR.TUMS.VCR.REC.1395.649).

Informed consent Informed consent was obtained from all individual participants included in the study.

1
2
3
4 **References**
5
6
7

- 8
9 1. American Association of Endodontists (2016) AAE clinical considerations for a regenerative procedure. Revised
10 6-8-16.
11 [https://www.aae.org/uploadedfiles/publications_and_research/research/currentregenerativeendodonticconsiderat](https://www.aae.org/uploadedfiles/publications_and_research/research/currentregenerativeendodonticconsiderations.pdf)
12 [ions.pdf](https://www.aae.org/uploadedfiles/publications_and_research/research/currentregenerativeendodonticconsiderations.pdf). Accessed 30 July 2017.
13
14
15
16 2. Hoshino E, Kurihara-Ando N, Sato I, et al. (1996) In-vitro antibacterial susceptibility of bacteria taken from
17 infected root dentine to a mixture of ciprofloxacin, metronidazole and minocycline. *Int Endod J* 29:125-130.
18
19 3. Iwaya SI, Ikawa M, Kubota M (2001) Revascularization of an immature permanent tooth with apical periodontitis
20 and sinus tract. *Dent Traumatol* 17:185-187.
21
22 4. Hargreaves KM, Giesler T, Henry M, Wang Y (2008) Regeneration potential of the young permanent tooth: what
23 does the future hold? *J Endod* 34:S51-56.
24
25 5. Hargreaves KM, Diogenes A, Teixeira FB (2013) Treatment options: biological basis of regenerative endodontic
26 procedures. *J Endod* 39:S30-43.
27
28 6. Kim JH, Kim Y, Shin SJ, Park JW, Jung IY (2010) Tooth discoloration of immature permanent incisor associated
29 with triple antibiotic therapy: a case report. *J Endod* 36:1086-1091.
30
31 7. Kahler B, Mistry S, Moule A, et al. (2014) Revascularization outcomes: a prospective analysis of 16 consecutive
32 cases. *J Endod* 40:333-338.
33
34 8. Kahler B, Rossi-Fedele G (2016) A review of tooth discoloration after regenerative endodontic therapy. *J Endod*
35 42:563-569.
36
37 9. Hargreaves KM, Diogenes A, Teixeira FB (2014) Paradigm lost: a perspective on the design and interpretation
38 of regenerative endodontic research. *J Endod* 40:S65-69.
39
40 10. Galler KM, Krastl G, Simon S, et al. (2016) European Society of Endodontology position statement:
41 Revitalization procedures. *Int Endod J* 49:717-723.
42
43 11. Kontakiotis EG, Filippatos CG, Tzanetakis GN, Agrafioti A (2015) Regenerative endodontic therapy: a data
44 analysis of clinical protocols. *J Endod* 41:146-154.
45
46 12. Sato I, Ando-Kurihara N, Kota K, Iwaku M, Hoshino E (1996) Sterilization of infected root-canal dentine by
47 topical application of a mixture of ciprofloxacin, metronidazole and minocycline in situ. *Int Endod J* 29:118-124.
48
49
50
51
52
53
54
55
56
57
58
59
60
61
62
63
64
65

- 1
2
3
4
5
6
7
8
9
10
11
12
13
14
15
16
17
18
19
20
21
22
23
24
25
26
27
28
29
30
31
32
33
34
35
36
37
38
39
40
41
42
43
44
45
46
47
48
49
50
51
52
53
54
55
56
57
58
59
60
61
62
63
64
65
13. Akcay M, Arslan H, Yasa B, Kavrik F, Yasa E (2014) Spectrophotometric analysis of crown discoloration induced by various antibiotic pastes used in revascularization. *J Endod* 40:845-848.
 14. Felman D, Parashos P (2013) Coronal tooth discoloration and white mineral trioxide aggregate. *J Endod* 39:484-487.
 15. Kang SH, Shin YS, Lee HS, et al. (2015) Color changes of teeth after treatment with various mineral trioxide aggregate-based materials: an ex vivo study. *J Endod* 41:737-741.
 16. Jang JH, Kang M, Ahn S, et al. (2013) Tooth discoloration after the use of new pozzolan cement (Endocem) and mineral trioxide aggregate and the effects of internal bleaching. *J Endod* 39:1598-1602.
 17. Marciano MA, Duarte MA, Camilleri J (2015) Dental discoloration caused by bismuth oxide in MTA in the presence of sodium hypochlorite. *Clin Oral Investig* 19:2201-2209.
 18. Shokouhinejad N, Nekoofar MH, Pirmoazen S, Shamshiri AR, Dummer PM (2016) Evaluation and comparison of occurrence of tooth discoloration after the application of various calcium silicate-based cements: an ex vivo study. *J Endod* 42:140-144.
 19. Schilke R, Lisson JA, Bauss O, Geurtsen W (2000) Comparison of the number and diameter of dentinal tubules in human and bovine dentine by scanning electron microscopic investigation. *Arch Oral Biol* 45:355-361.
 20. Kato MT, Hannas AR, Leite AL, et al. (2011) Activity of matrix metalloproteinases in bovine versus human dentine. *Caries Res* 45:429-434.
 21. Marciano MA, Costa RM, Camilleri J, Mondelli RF, Guimaraes BM, Duarte MA (2014) Assessment of color stability of white mineral trioxide aggregate angelus and bismuth oxide in contact with tooth structure. *J Endod* 40:1235-1240.
 22. Tanase S, Tsuchiya H, Yao J, Ohmoto S, Takagi N, Yoshida S. Reversed-phase ion-pair chromatographic analysis of tetracycline antibiotics (1998) Application to discolored teeth. *J Chromatogr B Biomed Sci Appl* 706:279-285.
 23. Berkhoff JA, Chen PB, Teixeira FB, Diogenes A (2014) Evaluation of triple antibiotic paste removal by different irrigation procedures. *J Endod* 40:1172-1177.
 24. Banchs F, Trope M (2004) Revascularization of immature permanent teeth with apical periodontitis: new treatment protocol? *J Endod* 30:196-200.

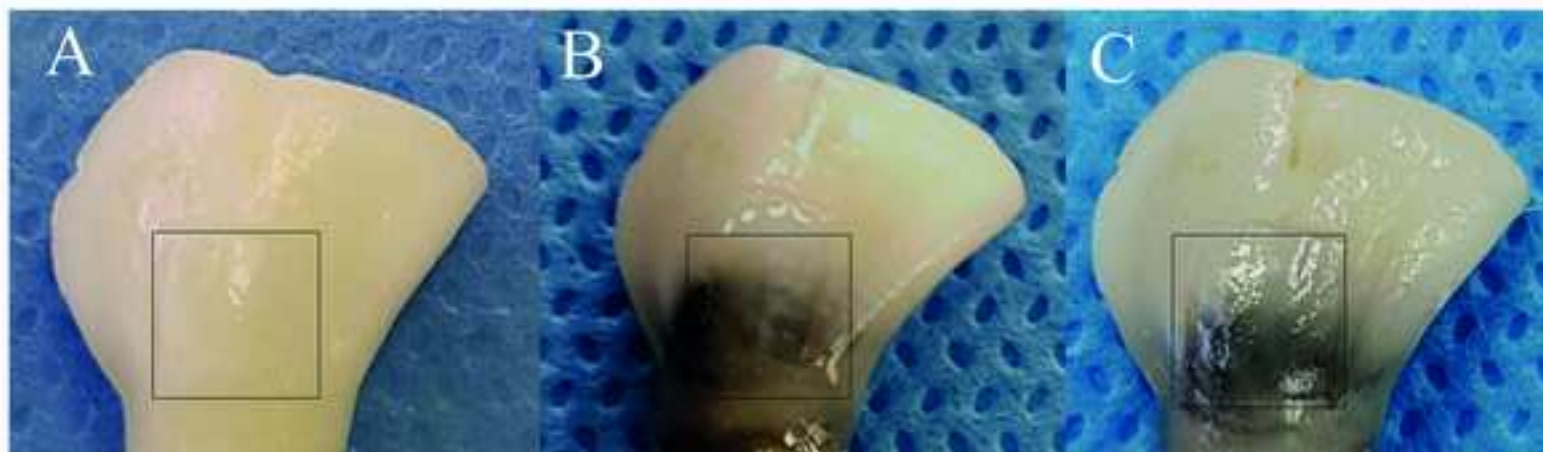
- 1
2
3
4 [23-25.](#) Porter ML, Munchow EA, Albuquerque MT, Spolnik KJ, Hara AT, Bottino MC (2016) Effects of novel 3-
5 dimensional antibiotic-containing electrospun scaffolds on dentin discoloration. *J Endod* 42:106-112.
6
7
8 [24-26.](#) Lenherr P, Allgayer N, Weiger R, Filippi A, Attin T, Krastl G (2012) Tooth discoloration induced by
9 endodontic materials: a laboratory study. *Int Endod J* 45:942-949.
10
11
12 [25-27.](#) Ramos JC, Palma PJ, Nascimento R, et al. (2016) 1-year in vitro evaluation of tooth discoloration Induced
13 by 2 calcium silicate-based cements. *J Endod* 42:1403-1407.
14
15
16 [26-28.](#) Marin PD, Heithersay GS, Bridges TE (1998) A quantitative comparison of traditional and non-peroxide
17 bleaching agents. *Endod Dent Traumatol* 14:64-67.
18
19
20 [27-29.](#) Camilleri J (2014) Color stability of white mineral trioxide aggregate in contact with hypochlorite solution.
21 *J Endod* 40:436-440.
22
23
24 [28-30.](#) Valles M, Mercade M, Duran-Sindreu F, Bourdelande JL, Roig M (2013) Color stability of white mineral
25 trioxide aggregate. *Clin Oral Investig* 17:1155-1159.
26
27
28 [29-31.](#) Kohli MR, Yamaguchi M, Setzer FC, Karabucak B (2015) Spectrophotometric analysis of coronal tooth
29 discoloration induced by various bioceramic cements and other endodontic materials. *J Endod* 41:1862-1866.
30
31
32 [30-32.](#) Marconyak LJ Jr., Kirkpatrick TC, Roberts HW, et al. (2016) A comparison of coronal tooth discoloration
33 elicited by various endodontic reparative materials. *J Endod* 42:470-473.
34
35
36 [34-33.](#) Camilleri J. Staining Potential of Neo MTA Plus, MTA Plus, and Biodentine used for pulpotomy **procedures**
37 **(2015) J Endod 41:1139-1145.**
38
39
40 [32-34.](#) **Yasuda Y, Inuyama H, Maeda H, Akamine A, Nör JE, Saito T (2008) Cytotoxicity of one-step dentin-**
41 **bonding agents toward dental pulp and odontoblast-like cells. J Oral Rehabil 35:940-946.**
42
43
44
45 [35.](#) **Trubiani O, Caputi S, Di Iorio D, et al. (2010) The cytotoxic effects of resin-based sealers on dental pulp**
46 **stem cells. Int Endod J 43:646-653.**
47
48
49
50
51
52
53
54
55
56
57
58
59
60
61
62
63
64
65

1
2
3
4 **Figure legends**
5
6
7
8

9 **Fig. 1.** Mean ΔE value changes at each treatment step. The dotted line represents clinically perceptible discoloration
10 of $\Delta E \geq 3.3$.
11
12

13
14 **Fig. 2.** Photographs of teeth in which pulp chamber was not sealed (No DBA) or sealed (DBA) with dentin bonding
15 agent: (*A* and *D*) at baseline, (*B* and *E*) at the end of the 4-week antibiotic therapy, and (*C* and *F*) at the four-month
16 follow-up. The color changes were measured within the defined area.
17
18
19
20
21
22
23
24
25
26
27
28
29
30
31
32
33
34
35
36
37
38
39
40
41
42
43
44
45
46
47
48
49
50
51
52
53
54
55
56
57
58
59
60
61
62
63
64
65

No DBA



DBA



