

Use of imaging for pre- and post-operative characterisation of ventral hernia

Halligan, Steve; Parker, Sam G; Plumb, Andrew A; Wood, Chris Pj; Bolton, Richard W; Mallett, Susan; Windsor, Alastair Cj

DOI:

[10.1259/bjr.20170954](https://doi.org/10.1259/bjr.20170954)

License:

None: All rights reserved

Document Version

Publisher's PDF, also known as Version of record

Citation for published version (Harvard):

Halligan, S, Parker, SG, Plumb, AA, Wood, CP, Bolton, RW, Mallett, S & Windsor, AC 2018, 'Use of imaging for pre- and post-operative characterisation of ventral hernia: systematic review', *British Journal of Radiology*.
<https://doi.org/10.1259/bjr.20170954>

[Link to publication on Research at Birmingham portal](#)

Publisher Rights Statement:

Published online at: <https://doi.org/10.1259/bjr.20170954>

General rights

Unless a licence is specified above, all rights (including copyright and moral rights) in this document are retained by the authors and/or the copyright holders. The express permission of the copyright holder must be obtained for any use of this material other than for purposes permitted by law.

- Users may freely distribute the URL that is used to identify this publication.
- Users may download and/or print one copy of the publication from the University of Birmingham research portal for the purpose of private study or non-commercial research.
- User may use extracts from the document in line with the concept of 'fair dealing' under the Copyright, Designs and Patents Act 1988 (?)
- Users may not further distribute the material nor use it for the purposes of commercial gain.

Where a licence is displayed above, please note the terms and conditions of the licence govern your use of this document.

When citing, please reference the published version.

Take down policy

While the University of Birmingham exercises care and attention in making items available there are rare occasions when an item has been uploaded in error or has been deemed to be commercially or otherwise sensitive.

If you believe that this is the case for this document, please contact UBIRA@lists.bham.ac.uk providing details and we will remove access to the work immediately and investigate.

Received:
11 December 2017

Revised:
22 February 2018

Accepted:
22 February 2018

<https://doi.org/10.1259/bjr.20170954>

Cite this article as:

Halligan S, Parker SG, Plumb AAO, Wood CPJ, Bolton RW, Mallett S, et al. Use of imaging for pre- and post-operative characterisation of ventral hernia: systematic review. *Br J Radiol* 2018; **91**: 20170954.

THE ROLE OF IMAGING IN OBESITY SPECIAL FEATURE: SYSTEMATIC REVIEW

Use of imaging for pre- and post-operative characterisation of ventral hernia: systematic review

¹STEVE HALLIGAN, MBBS, MD, PhD, FRCP, FRCR, FMedSci, ²SAM G PARKER, MChEM, MBBCh, MRCS,
¹ANDREW A O PLUMB, BMBCh, PhD, MRCP, FRCR, ²CHRIS PJ WOOD, MBBChir, MBBS, MA (Cantab), Med, FRCS,
²RICHARD W BOLTON, BMBS, FRCS, ³SUSAN MALLETT, DipStatOpen, DPhil and
²ALASTAIR CJ WINDSOR, MBBS, MD, FRCS

¹Centre for Medical Imaging, University College London, Charles Bell House, London, UK

²Department of Surgery, The Abdominal Wall Unit, University College Hospital, London, UK

³Institute of Applied Health Sciences, University of Birmingham, Edgbaston, UK

Address correspondence to: Prof Steve Halligan
E-mail: s.halligan@ucl.ac.uk

Objective: Complex ventral hernia (CVH) repair is performed increasingly, exacerbated by the obesity epidemic. Imaging can characterise hernia morphology and diagnose recurrence. By systematic review we investigated the extent to which studies employ imaging.

Methods: The PubMed database was searched for studies of ventral hernia repair from January 1995 to March 2016. Hernias of all size were eligible. Independent reviewers screened articles and extracted data from selected studies related to study design, use of pre- and post-operative hernia imaging and the proportion of subjects imaged. The review was registered: PROSPERO CRD42016043071.

Results: 15,771 records were identified initially. 174 full-texts were examined and 158 ultimately included in the systematic review [31 randomised controlled trials (RCTs); 32 cohort studies; 95 retrospective cohort studies]. 31,874 subjects were reported overall. Only 19 (12%) studies employed pre-operative imaging for hernia characterisation and 46 (29%) post-operatively [equating to 511 (2%) of all pre-operative subjects and 1123 (4%) post-operative]. Furthermore, most studies employing

imaging did not do so in all subjects: Just 6 (4%) of the 158 studies used imaging in all subjects pre-operatively and just 4 (3%) post-operatively, *i.e.* imaging was usually applied to a proportion of patients only. Moreover, the exact proportion was frequently not specified. Studies using imaging frequently stated that “imaging”, “radiography” or “radiology” was used but did not specify the modality precisely nor the proportion of subjects imaged.

Conclusion: Despite the ability to characterise ventral hernia morphology and recurrence with precision, most indexed studies do not employ imaging. Where imaging is used, data are often reported incompletely.

Advances in knowledge: (1) This systematic review is the first to focus on the use of imaging in surgical studies of ventral hernia repair. (2) Studies of ventral hernia repair rarely use imaging, either to characterise hernias pre-operatively or to diagnose recurrence, despite the latter being the primary outcome of most studies. (3) Failure to use imaging will result in incomplete hernia characterisation and underestimate recurrence rates in studies of surgical repair.

INTRODUCTION

Ventral hernia describes anterior, incisional, abdominal wall hernias and complex ventral hernia (CVH) describes those that are large. CVH incidence is rising rapidly due to the increasing prevalence of both obesity and abdominal surgery.¹ 49,736 ventral hernia repairs were performed in the UK in 2015 (Hospital Episode Statistics, NHS Digital, unpublished data). CVH poses specific surgical challenges since repair requires extensive surgical dissection

to mobilise tissue flaps that allow access to surgical planes for component separation² and implantation of prosthetic mesh where needed. The aim is to cover the fascial defect, re-approximate the rectus muscles into the midline and strengthen the abdominal wall. Such major surgery is not tackled easily by “general” surgeons, and specialists dedicated to abdominal wall repair are emerging.^{3,4} In our experience, these surgeons often refer their patients for pre- and post-operative imaging, normally CT scanning.

Imaging is able to characterise hernia morphology pre-operatively including its precise location, content and its volume. Imaging can also determine “loss of domain”, which describes the ratio between the volume of the hernia and residual abdominopelvic cavity volume.⁵ Recurrence rates for CVH reach 40%, even in experienced hands,^{6,7} and post-operative imaging can diagnose recurrence with precision. A recent systematic review of randomised controlled trials (RCTs) of ventral hernia repair found that the methods used to detect recurrence were either not defined or inconsistent⁸ and an accompanying Editorial stressed the need for robust outcomes in hernia research.⁹ Given that CVH repair is a developing field, and to emphasise the potential for imaging to provide important pre- and post-operative information for hernia research, we performed a systematic review of the available literature to investigate the extent to which imaging is being used to manage ventral hernia patients.

METHODS AND MATERIALS

Objectives

The primary aim of this review was to explore how often imaging was used in research studies to characterise the pre-operative nature of the hernia and the post-operative appearances, and what was reported in these studies.

This would include how often was imaging used as an independent tool to confirm either that the hernia had been treated successfully or to confirm that a recurrence suspected clinically was actually due to a hernia rather than, for example, a seroma. We decided *a priori* that the review focus was not around the use of imaging to detect early post-operative complications (since this is part of normal practice).

Reporting and registration

This systematic review was reported in line with the Preferred Reporting Items for Systematic Reviews and Meta-Analyses (PRISMA) statement.¹⁰ Ethical permission is not required by our centre for systematic reviews of available primary literature. A protocol was developed and registered with PROSPERO, the international prospective register of systematic reviews: CRD42016043071.

Inclusion criteria for studies

We aimed to identify indexed studies that described clinical outcomes in patients following ventral hernia repair between 1st January 1995 and 31st March 2016 inclusive. We excluded studies with fewer than 10 patients since such data are weak. The search was restricted to the English language.

Target condition

The target condition was surgical ventral hernia repair. Although our primary research interest was CVH, no generally accepted definition of this exists. Accordingly, all different abdominal wall hernia morphologies and grade¹¹ were eligible except parastomal. Hernias elsewhere were excluded, for example groin hernias. Emergency repair was excluded, for example primary closure after damage control laparotomy. However, patients having elective ventral hernia repair following such events were

eligible. We excluded trials with concomitant tumour removal or bariatric surgery.

Participants

Adult participants undergoing surgical VH repair. We excluded paediatric studies (defined as 18 years or less), which are unrepresentative of “typical” CVH patients.

Follow-up

No minimum follow-up length was stipulated.

Search strategy and string

A surgical research fellow, SGP, searched the PubMed database from 1st January 1995 to 31st March 2016 inclusive, limiting the search using the following terms: “adult 19+”, “human studies” and to those written in English. Our search string identified and combined the two following criteria to identify relevant articles:

- (1) To identify studies of ventral hernia disease including complex disease we used the MESH terms “hernia”, “abdominal hernia”, “umbilical hernia” and “ventral hernia”. These were combined with keywords: “abdominal wall reconstruction”; “herniorrhaphy”; “ventral defect” and “entero-cutaneous fistula”.
- (2) To identify studies of surgical techniques used for ventral hernia repair we used the MESH terms: “general surgery”; “reconstructive surgical procedures” and “surgical mesh”. This was combined with keywords: “pneumoperitoneum”, “botox”, “botulinium”, “two-stage”, “two step”, “staged repair”, “component separation”, “transversus abdominis”, “retro-rectus”, “bridging”, “bridge repair”, “silo”, “open” and “laparoscopic”.

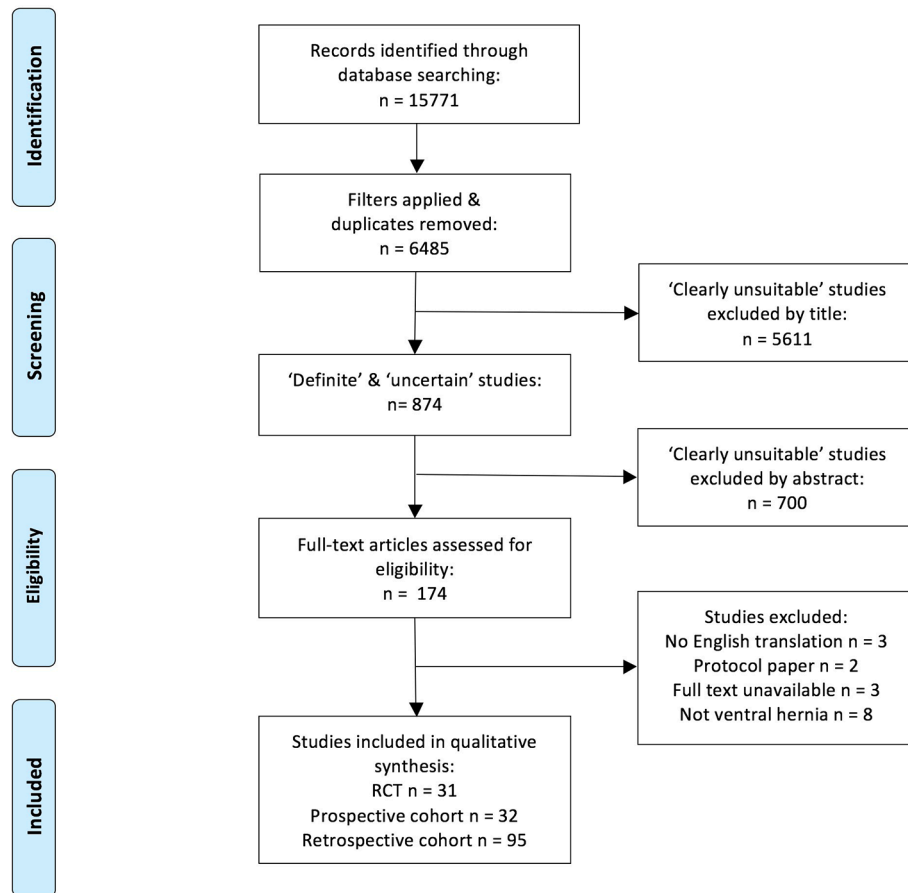
We did not use any terms to identify studies that used imaging since we believed that doing so was likely to result in a significant proportion of missed studies.

Our complete search string is shown in online [Supplementary Material 1](#) (Supplementary material available online).

Citation management and screening

Identified citations were entered into a spreadsheet (Microsoft Excel for Mac 2011 v. 14.5.9, Microsoft Corporation, Washington), and uploaded subsequently into a reference manager able to access online original articles directly (Mendeley Desktop v. 1.17, London, UK). After the search filters were applied and duplicates excluded, citations were divided into two equal groups. Titles of the first-half were screened by SGP and the second-half by CPJW, also a surgical research fellow. The researchers screened abstracts for studies of ventral hernia and discarded articles that were “clearly unsuitable” (*e.g.* subject not ventral hernia) and retained any regarded as “uncertain” or “definitely possible”. These two latter groups were combined and assessed independently by three researchers (SGP, CPJW, RWB) with the aim of identifying all comparative studies. These were divided into groups based on study methodology as follows: RCTs; prospective cohort studies; retrospective cohort studies. Any article where uncertainty persisted was discussed face-to-face with senior members of the research team (SH, SM,

Figure 1. PRISMA flow chart of study selection. PRISMA, Preferred Reporting Items for Systematic Reviews and Meta-Analyses; RCT, randomised controlled trial.



ACJW). An exclusion log was kept at all stages. The PRISMA¹⁰ diagram (Figure 1) shows the flow of article selection.

Data extraction

The full list of articles and copies of their full text were passed to the senior radiologist on the research team (SH) who reviewed each article with the aim of extracting data relating specifically to the use of imaging in each study. Data were extracted into an Excel spreadsheet as before. The following categories were extracted: Citation; study design (RCT; prospective cohort study; retrospective cohort study); the total number of individual patients reported in each individual study; the proportion of patients in whom pre-operative imaging was used to characterise the hernia (and the type of characterisation noted where imaging was adopted); the proportion of patients in whom post-operative imaging was used to characterise the hernia repair; the imaging modality used.

A primary aim of this review was to collect data regarding how imaging was used in research studies, beyond a simple metric of hernia size and/or recurrence. Accordingly, specific attention was paid during extraction to any reported attempt to characterise hernia morphology (e.g. loss of domain, muscular quality). Our a priori intention was to note details of these in a free text column in the extraction sheet where any such attempts were described.

Free text space was also available for notes regarding exactly how imaging was implemented within each individual study.

We deemed that separate reports originating from the same research group were acceptable, even if reported patients were found to overlap, because the review focuses on reporting methods rather than treatment effects.

Risk of bias

We note that risk of bias assessments are not relevant to this review of frequency and reporting within studies. Risk of bias assessment for these articles is included in separate review and meta-analysis that describes reported peri- and post-operative factors and hernia recurrence.⁸

RESULTS

The search string identified 15,771 records with 874 remaining potentially eligible after duplicates and “clearly unsuitable” articles were discarded via their title (Figure 1). Following review of the associated abstracts, 174 full-text articles were examined and ultimately 158 included in the systematic review (31 RCTs, 32 prospective cohort studies, 95 retrospective cohort studies). Individual studies are described in [Supplementary Material 2](#). These 158 articles reported a total of 31,874 patients overall. The number of subjects reported split by study type are shown in

Table 1. Details of patients included in the review, split by study design

	Total patients reported (mean no. per study; range)	No. of studies where imaging used for pre-operative hernia characterisation (%)	No. of patients in whom imaging used for pre-operative hernia characterisation (%)	No. of studies where imaging used for post-operative hernia characterisation (%)	No. of patients in whom imaging used for post-operative hernia characterisation (%)
Study type:					
RCTs (<i>n</i> = 31)	3386 (109; 24 to 337)	2 (6)	124 (4)	9 (29)	139 (4)
Prospective cohort studies (<i>n</i> = 32)	9020 (282; 23 to 4786)	2 (6)	89 (1)	8 (25)	286 (3)
Retrospective cohort study (<i>n</i> = 95)	19,486 (205; 24 to 2754)	15 (16)	298 (2)	29 (31)	698 (4)
Total:	31,874	19 (12)	511 (2)	46 (29)	1123 (4)

RCTs, randomised controlled trials.

Table 1, with mean number per design and range. Overall, most subjects were reported in retrospective cohort studies and least in RCTs.

The number of studies and individual subjects in whom imaging was used for pre- and post-operative hernia characterisation is shown in **Table 1**, split by study type. Overall, just 19 (12%) studies employed imaging to characterise hernias pre-operatively and 46 (29%) post-operatively. This equated to just 511 (2%) of all patients pre-operatively and 1123 (4%) post-operatively. Thus, the vast majority of subjects reported in the indexed literature underwent no imaging characterisation of their hernia at any time. We searched articles for any mention of imaging including within the discussion or when pre-operative chest X-ray was used: Imaging of any description was not mentioned in 92 (58%) articles overall (16 RCTs; 16 prospective cohort studies; 61 retrospective cohort studies).

Furthermore, most studies employing imaging pre- and/or post-operatively did not do so in all of the subjects recruited. Indeed only one RCT¹² of 24 patients, two prospective cohort studies of 54¹³ and 35¹⁴ subjects and three retrospective cohort studies of 44,¹⁵ 93¹⁶ and 48¹⁷ subjects employed pre-operative imaging in the whole group reported, *i.e.* just 6 (4%) of the 158 studies included used imaging in all subjects pre-operatively. Post-operative imaging was used in all subjects reported in one RCT of 40 subjects,¹⁸ three prospective cohort studies of 50,¹⁹ 93²⁰ and 100²¹ subjects and in no retrospective cohort study, *i.e.* just 4 (3%) of the 158 studies included used imaging in all subjects post-operatively. Moreover, no study design used imaging both pre- and post-operatively in all of the subjects reported.

It follows that when imaging was used either pre- or post-operatively, it was usually applied to only a proportion of patients. Moreover, where imaging was employed, the exact proportion of patients in whom this happened was frequently not stated, nor any selection criteria described. Typical examples include a RCT²² of 80 patients where inclusion criteria required that the hernia be, “detected by sonography or palpation” but the relative

proportions were unstated, and a retrospective cohort of 392 subjects²³ where “radiographic evidence” was used to confirm recurrence but neither the method(s) used nor the proportion were stated. The number of studies where imaging was apparently used but where the proportion of patients was unstated was 30 (46% of the 65 studies using pre- and/or post-operative imaging): 7 RCT; 1 prospective cohort study; 22 retrospective cohort studies.

CT was the imaging modality most used (41 of the 65 studies using imaging), followed by ultrasound (19 studies). 10 studies used either CT or ultrasound. MRI was used in three studies and abdominal radiography in one. Where multiple imaging modalities were employed, the proportion of subjects having each was almost always unspecified, nor the reason why. Studies often stated that “imaging”, “radiography” or “radiology” was used but did not specify the precise modality.

Some studies stated that case-note review was used to obtain hernia dimensions but did not state the proportion, *e.g.* “hernia size was obtained from pre-operative imaging or intra-operative documentation”.²⁴ No study stated that imaging was used to calculate loss of domain; a single study stated that “loss of domain” was a contraindication to surgery but no information was provided regarding how this was calculated nor the proportion of subjects affected.²⁵

DISCUSSION

While most ventral hernias are repaired easily, CVH poses specific problems because of factors related to both the patient (*e.g.* morbid obesity, diabetes) and their hernia (large volume, extensive muscular deficiency). While pre-operative imaging can characterise hernia morphology pre-operatively, our anecdotal impression has been that imaging is used rarely. This systematic review has confirmed this impression: Just 19 (12%) of the 158 studies ultimately included in the review characterised the hernia using pre-operative imaging. Moreover, we found that most studies imaged only a proportion of patients; just six studies imaged all patients pre-operatively. Overall, just 2% of reported

patients were imaged pre-operatively. An a priori intention was to record the extent to which imaging was used to characterise patients beyond simple metrics of pre-operative dimension and post-operative recurrence but such investigations were absent. For example, no study reported “loss of domain”⁵

Imaging was also infrequently used post-operatively; 46 (29%) studies used post-operative imaging but, again, usually only in a small proportion of patients, equating to just 4% of all patients reported. These data surprised us especially since the primary outcome for most studies was hernia recurrence. The working group for the European Registry of abdominal wall hernias defined recurrence as, “protrusion of the contents of the abdominal cavity or preperitoneal fat through a defect in the abdominal wall at the site of a previous repair”²⁶. The group noted the problem of “post-operative bulging or so-called pseudorecurrence” whereby there is no post-operative fascial defect but lack of abdominal wall support gives the clinical impression of a hernia.²⁶ Post-operative distinction between the two can only be made via imaging. A subsequent meeting of the group noted that hernia recurrence is the primary outcome in most studies of CVH repair and that the rate will be contingent on the method used for detection and length of follow-up, agreeing that imaging represented the highest quality tier to detect recurrence, superior to clinical examination.²⁷ Some studies have simply used a questionnaire to detect recurrence, a method that has been judged to underestimate recurrence fivefold.²⁸

Emphasising the importance of post-operative imaging for research studies of hernia repair, a recent RCT of prophylactic onlay and sublay mesh vs suture repair, published after our search was completed, stated, “one of the main limitations of the PRIMA study is the fact that not all patients underwent radiological examination”, going on to say that, “radiological examination is more sensitive than physical examination”.²⁹ While we do not advocate imaging all ventral hernias in clinical practice, notably small hernias, we believe that research studies of surgical methods should adopt procedures to minimise bias. For example, in studies of limited follow-up, asymptomatic early post-operative recurrence may be missed without an imaging endpoint, and such hernias may precipitate symptoms later.

Our review does have limitations. In particular, while our primary interest was CVH, a precise and generally accepted definition for CVH does not exist. Our early scoping searches found that studies reported across a wide range of hernia sizes and specific data pertaining to CVH were often not extractable

as a subgroup, even if a precise definition was available. Using component separation and/or mesh insertion as a surrogate for CVH was also confounded by inability to extract these subgroups from many primary reports. Accordingly, in order to avoid discarding useful data, we elected to review studies of “ventral hernia”. Furthermore, while small hernias may not demand pre-operative imaging, it is unfortunate that studies employing imaging do not report these data where the authors state they have been obtained. In particular, incomplete reporting meant that the exact proportion of patients imaged was unclear and the modality used was unstated. These data are important because we might anticipate that imaged patients have larger hernias than those who went unimaged, thus introducing a spectrum bias. Studies often neglected to state the proportions of morphological data obtained via clinical examination vs imaging. Again, this will introduce a spectrum bias since the precision of different measurement methods varies. We did include studies with overlapping patient populations, since our focus was on the quality of reporting rather than outcomes, and, although small, this overlap will have had some effect on the proportions stated.

In summary, our systematic review of studies of ventral hernia repair found that both pre- and post-operative imaging are used rarely, and that where used, reporting is often incomplete. Hernia specific metrics such as loss of domain are not being reported. Failure to use imaging will result in incomplete hernia characterisation and underestimate recurrence rates in studies of surgical repair.

FUNDING

This work was supported by the United Kingdom National Institute for Health Research (NIHR) via Research for Patient Benefit grant PB-PG-0816-20005 and the University College London Hospitals Biomedical Research Centre (SH and AAP). The views expressed in this publication are those of the authors and not necessarily those of the NHS, the NIHR or the Department of Health. The authors also wish to thank Allergan PLC (Dublin, Ireland) for educational support for SGP and ACJW.

DISCLOSURE

SGP and ACJW declare a relationship with Allergan PLC (Dublin, Ireland). ACJW also declares relationships with BARD Medical (Covington GA, USA), and Cook Medical (Limerick, Ireland). The remaining authors declare no relationships with any companies whose products or services may be related to the subject matter of the article.

REFERENCES

1. Poulou BK, Shelton J, Phillips S, Moore D, Nealon W, Penson D, et al. Epidemiology and cost of ventral hernia repair: making the case for hernia research. *Hernia* 2012; **16**: 179–83. doi: <https://doi.org/10.1007/s10029-011-0879-9>
2. Ramirez OM, Ruas E, Dellon AL. “Components separation” method for closure of abdominal-wall defects: an anatomic and clinical study. *Plast Reconstr Surg* 1990; **86**: 519–26.
3. Köckerling F, Berger D, Jost JO. What is a certified hernia center? The example of the German hernia society and German society of general and visceral surgery. *Front Surg* 2014; **1**: 26. doi: <https://doi.org/10.3389/fsurg.2014.00026>
4. Sanders DL, Kingsnorth AN, Windsor AC. Is there a role for hernia subspecialists? Or is this a step too far? *Hernia* 2016; **20**: 637–40. doi: <https://doi.org/10.1007/s10029-016-1511-9>

5. Tanaka EY, Yoo JH, Rodrigues AJ, Utiyama EM, Birolini D, Rasslan S. A computerized tomography scan method for calculating the hernia sac and abdominal cavity volume in complex large incisional hernia with loss of domain. *Hernia* 2010; **14**: 63–9. doi: <https://doi.org/10.1007/s10029-009-0560-8>
6. Rios A, Rodriguez JM, Munitiz V, Alcaraz P, Pérez D, Parrilla P. Factors that affect recurrence after incisional herniorrhaphy with prosthetic material. *Eur J Surg* 2001; **167**: 855–9. doi: <https://doi.org/10.1080/11024150152717706>
7. Flum DR, Horvath K, Koepsell T. Have outcomes of incisional hernia repair improved with time? A population-based analysis. *Ann Surg* 2003; **237**: 129–35. doi: <https://doi.org/10.1097/01.SLA.0000041042.86225.9C>
8. Parker SG, Wood CPJ, Butterworth JW, Boulton RW, Plumb AAO, Mallett S, et al. A systematic methodological review of reported perioperative variables, postoperative outcomes and hernia recurrence from randomised controlled trials of elective ventral hernia repair: clear definitions and standardised datasets are needed. *Hernia* 2018; [Epub ahead of print]. doi: <https://doi.org/10.1007/s10029-017-1718-4>
9. Rosen MJ. We have a long way to go. Invited comment to: a systematic methodological review of reported perioperative variables, postoperative outcomes and hernia recurrence from randomized controlled trials of elective ventral hernia repair: clear definitions and standardized datasets are needed. Samuel G. Parker, C. P. J. Wood, J. W. Butterworth, R. W. Boulton, A. A. O. Plumb, S. Mallett, S. Halligan, A. C. J. Windsor. *Hernia* 2018; [Epub ahead of print]. doi: <https://doi.org/10.1007/s10029-018-1750-z>
10. Moher D, Liberati A, Tetzlaff J, Altman DG, PRISMA Group. Preferred reporting items for systematic reviews and meta-analyses: the PRISMA statement. *PLoS Med* 2009; **6**: e1000097. doi: <https://doi.org/10.1371/journal.pmed.1000097>
11. Ventral Hernia Working Group, Breuing K, Butler CE, Ferzoco S, Franz M, Hultman CS, et al. Incisional ventral hernias: review of the literature and recommendations regarding the grading and technique of repair. *Surgery* 2010; **148**: 544–58. doi: <https://doi.org/10.1016/j.surg.2010.01.008>
12. Navarra G, Musolino C, De Marco ML, Bartolotta M, Barbera A, Centorrino T. Retromuscular sutured incisional hernia repair: a randomized controlled trial to compare open and laparoscopic approach. *Surg Laparosc Endosc Percutan Tech* 2007; **17**: 86–90. doi: <https://doi.org/10.1097/SLE.0b013e318030ca8b>
13. Anadol AZ, Akin M, Kurukahvecioglu O, Tezel E, Ersoy E. Comparison of laparoscopic primary and open primary repair of ventral hernias. *Surg Laparosc Endosc Percutan Tech* 2011; **21**: 301–5. doi: <https://doi.org/10.1097/SLE.0b013e3182245d61>
14. Werkgartner G, Cerwenka H, Rappl T, Kniepeiss D, Kornprat P, Iberer F, et al. Effectiveness of porcine dermal collagen in giant hernia closure in patients with deleterious fascia constitution after orthotopic liver transplantation. *Transpl Int* 2015; **28**: 156–61. doi: <https://doi.org/10.1111/tri.12464>
15. Fox M, Cannon RM, Egger M, Spate K, Kehdy FJ. Laparoscopic component separation reduces postoperative wound complications but does not alter recurrence rates in complex hernia repairs. *Am J Surg* 2013; **206**: 869–75. doi: <https://doi.org/10.1016/j.amjsurg.2013.08.005>
16. Docimo L, Manzi F, Sparavigna L, De Rosa M, Granato F, Amoroso V, et al. Dynamic suture less repair of incisional hernia. *Acta Biomed* 2003; **74**(Suppl 2): 38–40.
17. Bogetti P, Boriani F, Gravante G, Milanese A, Ferrando PM, Baglioni E. A retrospective study on mesh repair alone vs. mesh repair plus pedicle flap for large incisional hernias. *Eur Rev Med Pharmacol Sci* 2012; **16**: 1847–52.
18. Beldi G, Wagner M, Bruegger LE, Kurmann A, Candinas D. Mesh shrinkage and pain in laparoscopic ventral hernia repair: a randomized clinical trial comparing suture versus tack mesh fixation. *Surg Endosc* 2011; **25**: 749–55. doi: <https://doi.org/10.1007/s00464-010-1246-0>
19. Morales-Conde S, Suárez-Artacho G, Socas M, Barranco A. Influence of fibrin sealant in preventing postoperative seroma and normalizing the abdominal wall after laparoscopic repair of ventral hernia. *Surg Endosc* 2013; **27**: 3214–9. doi: <https://doi.org/10.1007/s00464-013-2894-7>
20. Schroeder AD, Debus ES, Schroeder M, Reinhold WM. Laparoscopic transperitoneal sublay mesh repair: a new technique for the cure of ventral and incisional hernias. *Surg Endosc* 2013; **27**: 648–54. doi: <https://doi.org/10.1007/s00464-012-2508-9>
21. Lomanto D, Iyer SG, Shabbir A, Cheah WK. Laparoscopic versus open ventral hernia mesh repair: a prospective study. *Surg Endosc* 2006; **20**: 1030–5. doi: <https://doi.org/10.1007/s00464-005-0554-2>
22. Rickert A, Kienle P, Kuthe A, Baumann P, Engemann R, Kuhlitz J, et al. A randomised, multi-centre, prospective, observer and patient blind study to evaluate a non-absorbable polypropylene mesh vs. a partly absorbable mesh in incisional hernia repair. *Langenbecks Arch Surg* 2012; **397**: 1225–34. doi: <https://doi.org/10.1007/s00423-012-1009-6>
23. Berger RL, Li LT, Hicks SC, Liang MK. Suture versus preperitoneal polypropylene mesh for elective umbilical hernia repairs. *J Surg Res* 2014; **192**: 426–31. doi: <https://doi.org/10.1016/j.jss.2014.05.080>
24. Ng N, Wampler M, Palladino H, Agullo F, Davis BR. Outcomes of laparoscopic versus open fascial component separation for complex ventral hernia repair. *Am Surg* 2015; **81**: 714–9.
25. Stirler VM, Schoenmaeckers EJ, de Haas RJ, Raymakers JT, Rakic S. Laparoscopic repair of primary and incisional ventral hernias: the differences must be acknowledged: a prospective cohort analysis of 1,088 consecutive patients. *Surg Endosc* 2014; **28**: 891–5. doi: <https://doi.org/10.1007/s00464-013-3243-6>
26. Muysoms F, Campanelli G, Champault GG, DeBeaux AC, Dietz UA, Jeekel J, et al. EuraHS: the development of an international online platform for registration and outcome measurement of ventral abdominal wall hernia repair. *Hernia* 2012; **16**: 239–50. doi: <https://doi.org/10.1007/s10029-012-0912-7>
27. Muysoms FE, Deerenberg EB, Peeters E, Agresta F, Berrevoet F, Campanelli G, et al. Recommendations for reporting outcome results in abdominal wall repair: results of a Consensus meeting in Palermo, Italy, 28–30 June 2012. *Hernia* 2013; **17**: 423–33. doi: <https://doi.org/10.1007/s10029-013-1108-5>
28. Helgstrand F, Rosenberg J, Kehlet H, Strandfelt P, Bisgaard T. Reoperation versus clinical recurrence rate after ventral hernia repair. *Ann Surg* 2012; **256**: 955–8. doi: <https://doi.org/10.1097/SLA.0b013e318254f5b9>
29. Jairam AP, Timmermans L, Eker HH, Pierik R, van Klaveren D, Steyerberg EW, et al. Prevention of incisional hernia with prophylactic onlay and sublay mesh reinforcement versus primary suture only in midline laparotomies (PRIMA): 2-year follow-up of a multicentre, double-blind, randomised controlled trial. *Lancet* 2017; **390**: 567–76. doi: [https://doi.org/10.1016/S0140-6736\(17\)31332-6](https://doi.org/10.1016/S0140-6736(17)31332-6)