

Diagnostic Utility of IDH1/2 Mutations to Distinguish Dedifferentiated Chondrosarcoma from Undifferentiated Pleomorphic Sarcoma of Bone

Chen, Shaoxiong; Fritchie, Karen; Wei, Shi; Ali, Naser; Curless, Kendra; Shen, Tiansheng; Brini, Anna T.; Latif, Farida; Sumathi, Vaiyapuri; Siegal, Gene P.; Cheng, Liang

DOI:

[10.1016/j.humpath.2017.05.015](https://doi.org/10.1016/j.humpath.2017.05.015)

License:

Creative Commons: Attribution-NonCommercial-NoDerivs (CC BY-NC-ND)

Document Version

Peer reviewed version

Citation for published version (Harvard):

Chen, S, Fritchie, K, Wei, S, Ali, N, Curless, K, Shen, T, Brini, AT, Latif, F, Sumathi, V, Siegal, GP & Cheng, L 2017, 'Diagnostic Utility of IDH1/2 Mutations to Distinguish Dedifferentiated Chondrosarcoma from Undifferentiated Pleomorphic Sarcoma of Bone', *Human Pathology*.
<https://doi.org/10.1016/j.humpath.2017.05.015>

[Link to publication on Research at Birmingham portal](#)

General rights

Unless a licence is specified above, all rights (including copyright and moral rights) in this document are retained by the authors and/or the copyright holders. The express permission of the copyright holder must be obtained for any use of this material other than for purposes permitted by law.

- Users may freely distribute the URL that is used to identify this publication.
- Users may download and/or print one copy of the publication from the University of Birmingham research portal for the purpose of private study or non-commercial research.
- User may use extracts from the document in line with the concept of 'fair dealing' under the Copyright, Designs and Patents Act 1988 (?)
- Users may not further distribute the material nor use it for the purposes of commercial gain.

Where a licence is displayed above, please note the terms and conditions of the licence govern your use of this document.

When citing, please reference the published version.

Take down policy

While the University of Birmingham exercises care and attention in making items available there are rare occasions when an item has been uploaded in error or has been deemed to be commercially or otherwise sensitive.

If you believe that this is the case for this document, please contact UBIRA@lists.bham.ac.uk providing details and we will remove access to the work immediately and investigate.

Accepted Manuscript

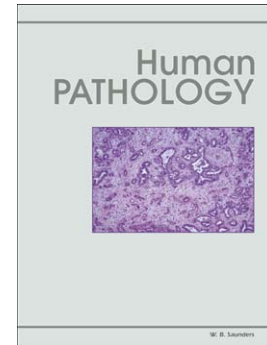Diagnostic Utility of *IDH1/2* Mutations to Distinguish Dedifferentiated Chondrosarcoma from Undifferentiated Pleomorphic Sarcoma of Bone

Shaoxiong Chen MD, Karen Fritchie MD, Shi Wei MD, Naser Ali MSc, Kendra Curless BA, Tiansheng Shen MD, Anna T Brini PhD, Farida Latif PhD, Vaiyapuri Sumathi MD, Gene P Siegal MD, Liang Cheng MD

PII: S0046-8177(17)30172-7
DOI: doi: [10.1016/j.humpath.2017.05.015](https://doi.org/10.1016/j.humpath.2017.05.015)
Reference: YHUPA 4234

To appear in: *Human Pathology*

Received date: 31 March 2017
Revised date: 1 May 2017
Accepted date: 10 May 2017



Please cite this article as: Chen Shaoxiong, Fritchie Karen, Wei Shi, Ali Naser, Curless Kendra, Shen Tiansheng, Brini Anna T, Latif Farida, Sumathi Vaiyapuri, Siegal Gene P, Cheng Liang, Diagnostic Utility of *IDH1/2* Mutations to Distinguish Dedifferentiated Chondrosarcoma from Undifferentiated Pleomorphic Sarcoma of Bone, *Human Pathology* (2017), doi: [10.1016/j.humpath.2017.05.015](https://doi.org/10.1016/j.humpath.2017.05.015)

This is a PDF file of an unedited manuscript that has been accepted for publication. As a service to our customers we are providing this early version of the manuscript. The manuscript will undergo copyediting, typesetting, and review of the resulting proof before it is published in its final form. Please note that during the production process errors may be discovered which could affect the content, and all legal disclaimers that apply to the journal pertain.

Diagnostic Utility of *IDH1/2* Mutations to Distinguish Dedifferentiated Chondrosarcoma from Undifferentiated Pleomorphic Sarcoma of Bone

Shaoxiong Chen, MD¹, Karen Fritchie, MD², Shi Wei, MD³, Naser Ali, MSc⁴, Kendra Curless, BA¹, Tiansheng Shen, MD³, Anna T Brini, PhD⁵, Farida Latif, PhD⁴, Vaiyapuri Sumathi, MD⁶, Gene P Siegal, MD³ and Liang Cheng, MD¹

¹Department of Pathology and Laboratory Medicine, Indiana University School of Medicine, Indianapolis, IN, USA;

²Department of Laboratory Medicine and Pathology, Mayo Clinic, Rochester, MN, USA;

³Department of Pathology, The University of Alabama at Birmingham, Birmingham, AL, USA

⁴Institute of Cancer and Genomic Sciences, University of Birmingham, Birmingham, U.K.

⁵Department of Biomedical, Surgical and Dental Sciences, University of Milan, Milan, Italy

⁶Department of Musculoskeletal Pathology, The Royal Orthopaedic Hospital, Birmingham B15 2TT, UK

Running title: *IDH1/2* mutational analysis in dedifferentiated chondrosarcoma and UPS of bone

Corresponding author:
Shaoxiong Chen, MD, Ph.D
Department of Pathology and Laboratory Medicine
Indiana University School of Medicine
350 W 11th St, Room 4088
Indianapolis, IN 46202
Phone: 317-491-6000
Fax: 317-491-6419
Email: chen251@iupui.edu

Summary Histologically it is nearly impossible to distinguish the dedifferentiated component of dedifferentiated chondrosarcoma from undifferentiated pleomorphic sarcoma of bone when the low-grade cartilaginous component is absent. Previous studies have revealed that isocitrate dehydrogenase 1 (*IDH1*) and *IDH2* mutations are present in a significant number of cartilaginous tumors including the majority of conventional chondrosarcoma and dedifferentiated chondrosarcomas. These mutations have not been studied in undifferentiated pleomorphic sarcomas of bone. We sought to investigate whether an *IDH1* or *IDH2* mutation signature could be used as a clinically diagnostic marker for the distinction of dedifferentiated component of chondrosarcoma from undifferentiated pleomorphic sarcoma of bone. Sixty-eight bone tumor cases, including 31 conventional chondrosarcomas, 23 dedifferentiated chondrosarcomas, and 14 undifferentiated pleomorphic sarcomas of bone, were collected for *IDH1/2* mutation analysis either using the Qiagen *IDH1/2* RGQ PCR Kit or using whole exome sequencing. *IDH1/2* mutations were detected in 87% (20/23) of dedifferentiated chondrosarcomas and 30% (6/20) of conventional chondrosarcomas. No mutations were detected in the *IDH1/2* codon 132 or codon 172 among 14 UPS of bone. Identification of *IDH1* or *IDH2* mutations supports the diagnosis of dedifferentiated chondrosarcoma rather than undifferentiated pleomorphic sarcoma of bone while also providing some insight into the pathogenesis of these two lesions.

Key Words: *IDH1*, *IDH2*, dedifferentiated chondrosarcoma, undifferentiated pleomorphic sarcoma (UPS) of bone

1. Introduction

Chondrosarcoma, a malignant cartilaginous tumor, is the second most common primary malignancy of bone after osteosarcoma, often arising from the pelvis, femur, or humerus. Tumors are classified as conventional chondrosarcoma when the histology resembles non-neoplastic cartilage, as opposed to dedifferentiated chondrosarcoma containing areas of high grade sarcoma. The most common morphological pattern of the dedifferentiated component is undifferentiated pleomorphic sarcoma (UPS), so-called malignant fibrous histiocytoma (MFH). Diagnosis of dedifferentiated chondrosarcoma relies on identifying both the well-differentiated cartilaginous and dedifferentiated components (1). UPS of bone is commonly located in the lower extremities, particularly the femur followed by tibia and pelvis. Morphologically, tumors are composed of atypical spindled and pleomorphic cells which may be arranged in a storiform, fascicular or haphazard pattern with marked nuclear pleomorphism, mitoses, and necrosis (2, 3). Importantly, these tumors lack chondroid and osteoid matrix deposition.

Although dedifferentiated chondrosarcoma and UPS of bone may share clinical presentations, including arising in similar anatomical locations, dedifferentiated chondrosarcoma is extremely aggressive with a dismal prognosis. Most patients with dedifferentiated chondrosarcoma die within 2 years of initial presentation. The 5-year survival rate is 19% based on a large study of 52 cases but ranges from 7.1 to 24% in studies throughout the literature (4, 5). With the lack of convincing evidence of the benefit of chemotherapy, complete surgical excision is the initial recommended treatment. UPS of bone is also aggressive. However, neoadjuvant or adjuvant chemotherapy is beneficial with the improved 5-year survival rate up to 59% (median survival time 63 months) (3, 6). In fact, neoadjuvant chemotherapy using an osteosarcoma treatment

protocol is gradually becoming the standard of care particularly for high grade resectable UPS of bone (3). Therefore, differentiating these two entities is of paramount importance. However, as there is significant morphologic overlap between UPS of bone and the dedifferentiated component of dedifferentiated chondrosarcoma, distinction often relies on the presence or absence of a low-grade cartilaginous component which may not be present with biopsy or limited sampling. To date, there are no reliable ancillary tests, such as immunohistochemistry, cytogenetics, or molecular studies, to improve diagnostic specificity.

Point mutations in the isocitrate dehydrogenase 1 (*IDH1*) or *IDH2* gene were originally detected in gliomas, secondary glioblastomas (7), and later identified in a variety of malignancies including some de novo acute myeloid leukemias (8, 9), myelodysplastic disorders (10), cholangiocarcinoma (11), thyroid carcinoma (12), prostate carcinoma, B cell lymphoma, and colorectal carcinomas (13). Further studies have shown that the majority of chondrosarcomas, including dedifferentiated chondrosarcomas, harbor mutations in the metabolic enzyme *IDH1* or *IDH2* gene whereas osteosarcomas including chondroblastic, fibroblastic, osteoblastic subtypes, etc, lack these genetic abnormalities (14-16). IDH is an important homodimeric enzyme in the citric acid cycle (the Krebs cycle) and normally catalyzes the decarboxylation of isocitrate (ICT) to α -ketoglutarate (α -KG). IDH1 and IDH2 employ NADP⁺ as a cofactor and are located in the cytoplasm (IDH1), peroxisomes (IDH1), and mitochondria (IDH2) (17). Mutations almost always affect a single amino acid residue at arginine-132 in *IDH1* or arginine-172 in *IDH2*. The majority of mutations occur in *IDH1* (14, 15). All reported *IDH1* and *IDH2* mutations are heterozygous, with cancer cells retaining one wild-type copy of the relevant *IDH1* or *IDH2* allele. These mutations lead to a reduced capacity to convert ICT to α -KG and a gain of function

to convert α -KG to delta-2-hydroxyglutarate (D-2-HG), an oncometabolite (18). Typically, mutations in *IDH1* or *IDH2* are mutually exclusive (18). Biochemical analysis revealed a >100-fold increase in D-2-hydroxyglutarate in human glioma samples with *IDH1* mutations while D-2-hydroxyglutarate is present at very low levels in normal tissue (19). The pathogenesis by D-2-hydroxyglutarate has been under extensive study (17, 19-21).

The fact that *IDH1/2* mutations are present in dedifferentiated chondrosarcoma and have not been studied in UPS of bone prompted us to evaluate whether an *IDH1* and *IDH2* mutation signature could be used as a molecular diagnostic marker to distinguish these two lesions, as well as give insight into the pathogenesis of these two lesions and provide useful information for clinical management.

2. MATERIALS AND METHODS

2.1 Ethics Statement

This study was approved by the Institutional Review Board of Indiana University, Mayo Clinic and University of Alabama at Birmingham. Resected specimens were submitted for routine histological diagnoses and the remaining tissues were used for research. There was no compromise of the patient's privacy.

2.2 Collection of Tumor Specimens

After searching pathology information system databases, cases of conventional chondrosarcoma and dedifferentiated chondrosarcoma were collected from Indiana University, Mayo Clinic, and the University of Alabama at Birmingham. Samples of primary undifferentiated pleomorphic

sarcomas of bone were collected from Musculoskeletal Pathology Department at the Royal Orthopaedic Hospital, Birmingham, UK. A significant number of conventional chondrosarcoma tissues were decalcified due to the presence of bone fragments. For a subset of dedifferentiated chondrosarcomas, both the conventional cartilaginous and the dedifferentiated components were available for mutation analysis from the same lesion. For each case, one or two hematoxylin and eosin-stained slides with tumor cells were selected by one pathologist at each institution and the corresponding formalin-fixed, paraffin-embedded tissue blocks were retrieved. Ten unstained sections (10 μ m in thickness per section) were cut from each tissue block and mounted on uncharged slides (one section per slide). Areas with lesional cells on the unstained sections (at least 6–7 sections) were circled by comparing with the corresponding hematoxylin and eosin-stained (H&E) slides and removed for DNA extraction. Necrotic tissue and surrounding paraffin were avoided.

2.3 DNA Extraction

DNA extraction from formalin-fixed, paraffin-embedded tissue was performed using a QIAamp DNA FFPE Tissue Kit (QIAGEN Catalog #56404, Valencia, CA) and recommended protocol. A few drops of 70% ethanol were added on the slide to wet the tissue section. The lesional cells were transferred to a 2 ml tube labeled with the case number by scraping the tissue off the slide. Major steps for DNA extraction included removal of paraffin, lysis of tissue, reversal of formalin crosslinking, DNA binding to a silica-based membrane, removal of contaminants, and eluting the DNA from the silica-based membrane. For the final steps, 50 μ l distilled DNase/RNase-free water was applied to the center of the membrane of the QIAamp MinElute column for each specimen for 1 min at room temperature (15–25 °C). The specimen was centrifuged at full speed

(20,000×g; 15,000 rpm) for 1 min. The QIAamp MinElute column was discarded and the microcentrifuge tube containing eluted DNA was labeled with the appropriate specimen information. The DNA concentration was determined by measuring the optical density of the sample at 260 nm and diluted to a concentration of 5 ng/μl in 1×TE buffer at pH 8.0.

2.4 Mutation Analysis by PCR

PCR reaction mixes were prepared according to the number of samples being processed and the Rotor-Gene Q instrument was programmed with the thermal cycling program as mentioned in the *IDH1/2* RGQ PCR Kit (QIAGEN Catalog #873001, Valencia, CA). This PCR kit detects multiple mutations in codon 132 of the *IDH1* gene and codon 172 of the *IDH2* gene, respectively. Reaction controls included the water control, the *IDH1/2* wild-type control, and the mutated *IDH1/2* positive control (Mut-PC). For each mutant assay, standards were set whereby the wild-type control had to be detected as mutation-negative and the Mut-PC had to be detected as mutation-positive. The entire experiment was invalid if both conditions were not met. For each specimen, Δ CT values were calculated for *IDH1* Mut R132, *IDH2* Mut R172, *IDH1* Mut R100, *IDH1* Mut R132H, *IDH1* Mut R132C, and *IDH2* Mut R172K. Samples were classified as mutation-positive (*IDH1* Mut R132, *IDH2* Mut R172, and *IDH1* Mut R100) if the Δ CT value was less than or equal to the Δ CT cutoff value of the respective mutation detection assay. The sample specific mutation was identified (*IDH1* Mut R132H, *IDH1* Mut R132C, and *IDH2* Mut R172K) if the Δ CT value was less than or equal to the Δ CT cutoff value of the respective mutation identification assay. Using the *IDH1/2* RGQ PCR Kit, multiple mutations including R132H, R132C and four other R132 mutations in the codon 132 of *IDH1*, R172K and four other R172 mutations in the codon 172 of *IDH2*, and one R100 mutation in the codon of *IDH1* could be detected. The other four *IDH1* R132 mutations, R132S, R132G, R132L, and R132V, could

not be further defined due to *IDH1/2* RGQ PCR Kit limitations and were simply designated as *IDH1* R132. The same was true for the other four *IDH2* R172 mutations which included R172M, R172W, R172S and R172G.

2.5 Exome capture, DNA sequencing and *IDH1/2* mutational hotspot analysis

Genomic DNA of undifferentiated pleomorphic sarcoma (UPS) of the bone was extracted from thirteen fresh frozen tumors using a standard phenol–chloroform extraction protocol. For one FFPE sample (Table 3 case 12), DNA was extracted using the QIAamp DNA FFPE Tissue Kit (QIAGEN Catalog #56404), following the manufacturer's protocol. Exome capture of sheared DNA fragments was performed using the Agilent SureSelect Human All Exon V5 kit following manufacturer's protocol (Agilent, Santa Clara, CA, USA). Paired end sequencing was performed using either Illumina 2x100bp (22) or NextSeq 2x150bp high output (23) protocols to achieve a 50X average coverage. The reads were aligned to the human genome reference sequence GRCh37 using BWA 0.7.x (24). Using Integrative Genomics Viewer (IGV) (<http://software.broadinstitute.org/software/igv/>), the Binary Alignment Map (BAM) files for all samples were manually checked for variations in the mutational hotspot codons R132 and R172 of *IDH1/2* genes, respectively.

2.6 Immunohistochemical Staining

Immunohistochemical staining was performed according to a previously published protocol (25). Only two changes were made to the protocol: Antigen retrieval was performed using Tris-EDTA buffer, pH 9.0 in a PT module (Dako) for 15 minutes and a mouse anti-human *IDH1* R132H monoclonal antibody (Catalog number DIA H09, Dianova, Hamburg, Germany) was used at 1:60 dilution as a primary antibody to detect mutated *IDH1* R132H enzyme. Human glioma was

used as a positive control. Cytoplasmic staining in the lesional cells of chondrosarcoma and dedifferentiated chondrosarcoma was considered a positive result.

3. RESULTS

3.1 Clinicopathologic Features

A total of 68 cases were collected for IDH1/2 mutation analysis and included 31 conventional chondrosarcomas, 23 dedifferentiated chondrosarcomas, and 14 UPS of bone. Among the 31 chondrosarcoma cases as shown in Table 1, the tumor size ranged from 1.5 cm in the cricoid to 47.0 cm in the right pelvis (mean, 10.4 cm; median, 8.5 cm). Seventy-seven percent lesions arose from the femur (n=11), pelvis (n=5), sacrum (n=4), or rib (n=4). The tumor size of dedifferentiated chondrosarcoma (Table 2) ranged from 4.2 cm to 26.0 cm (mean, 11.6 cm; median, 9.9 cm). All but one were primary lesions; the exception being a metastatic lesion in the liver. The primary tumors mainly arose from the femur (n=8), humerus (n=6), and pelvis (n=5). The tumor size of UPS of bone (Table 3) ranged from 3.0 cm to 12.5 cm (mean, 8.3 cm; median, 8.5 cm). The primary tumors mainly arose from the femur (n=9) and tibia (n=2).

Cases of conventional chondrosarcoma showed hyaline cartilage neoplasms containing variable numbers of atypical chondrocytes with enlarged, hyperchromatic nuclei (Fig. 1A). Those classified as dedifferentiated chondrosarcoma were biphasic tumors with areas of low-grade chondrosarcoma juxtaposed to foci containing atypical spindle and epithelioid cells with marked nuclear atypia (Fig. 1B). Typically, there was an abrupt transition between the cartilaginous and the non-chondrogenic sarcomatous component (Fig. 1C). UPS of bone revealed atypical spindle

and epithelioid cells with nuclear pleomorphism, hyperchromatism and readily-identifiable mitoses, lacking any specific line of differentiation by immunohistochemistry (Fig. 1D).

3.2 Mutational Analysis

Among the 31 cases of conventional chondrosarcoma, *IDH1/2* mutation analysis was successfully performed in 20 (65%). Of the 20 successful samples, 6 (30%) harbored a somatic mutation in either *IDH1* or *IDH2* (Table 1). The majority of mutations were detected in the *IDH1* gene (n=4) and included R132H (1), R132C (2), and R132 (1) (not specified, see Materials and Methods). Two other R172 mutations were found in the *IDH2* gene. Two of 4 grade 1 cases and 4 of 14 grade 2 cases contained *IDH1/2* mutations (Table 1). Review of the pathology reports and H&E slides revealed that the 11 failed cases were previously decalcified with hydrochloric acid. Among 23 cases of dedifferentiated chondrosarcoma, 20 (87%) harbored a somatic mutation in either *IDH1* or *IDH2* (Table 2) in the dedifferentiated components. Specifically, they were 1 R132H, 5 R132C, and 5 R132 mutations in the *IDH1* gene and 9 R172 mutations in the *IDH2* gene. Both conventional cartilaginous and dedifferentiated regions were tested in 16 cases; however, analysis of both components was successful in only 3, revealing 2 *IDH1* R132 and 1 *IDH2* R172 mutations. The mutations were concordant for both components tested in all three cases. By analyzing Whole Exome Sequencing data of 14 cases of UPS of bone, mutations in *IDH1/2* hotspots codon R132 and R172 were not detected (Table 3).

3.3 Detection of *IDH1* R132H Mutated Enzyme Expression Using Immunostaining

One conventional chondrosarcoma (Table 1, case 1) and one dedifferentiated chondrosarcoma (Table 2, case 19) were found to contain single *IDH1* R132H mutation. Therefore

immunostaining was performed to confirm the presence of the mutated IDH1 R132H protein expression in these two cases. Cytoplasmic staining was clearly demonstrated in the atypical chondrocytes of the conventional chondrosarcoma (Fig. 2B) and the dedifferentiated component the dedifferentiated chondrosarcoma (Fig. 2C).

4. DISCUSSION

Dedifferentiated chondrosarcoma is a highly aggressive biphasic mesenchymal tumor consisting of a well-differentiated cartilaginous component admixed with area of high-grade sarcoma. With extensive sampling and careful correlation with radiologic findings, the diagnosis is often straightforward. However, in the advent of core biopsy techniques, the conventional cartilaginous component can be easily missed. Specifically, if the biopsy only shows the high grade sarcomatous component, distinction from UPS of bone is nearly impossible with morphology alone. As treatment protocols and prognosis differ for these two entities, accurate diagnosis is critical.

Our results show that the presence of an *IDH1* or *IDH2* mutation strongly supports the diagnosis of dedifferentiated chondrosarcoma rather than UPS of bone. While an *IDH1/2* mutation was identified in the dedifferentiated component of 87% (20 of 23 cases) of our dedifferentiated chondrosarcomas, no UPS of bone (0 of 14 cases) harbored a detectable aberration in these genes. Therefore, *IDH1* and *IDH2* mutational analysis seems to be a robust strategy to be used in distinguishing these two lesions. Interestingly, the incidence of *IDH1/2* mutations in dedifferentiated chondrosarcoma in our series is slightly higher than what has previously

reported in the literature. Amary and colleagues identified *IDH1/2* mutations in 13 of 23 cases (56.5%) of dedifferentiated chondrosarcoma, while Meijer and coworkers found that 50% of dedifferentiated harbored *IDH1/2* aberrations (14, 16). We also showed concordance of mutation status in both well-differentiated and dedifferentiated components in three cases in which both regions we successfully analyzed. This is consistent with the previous report which demonstrated the same mutation detected in both components (grade I and dedifferentiated) in four cases (14). While the concept of dedifferentiation has long been recognized, these findings provide further evidence to support shared pathogenesis for both components. Furthermore, the absence of *IDH1/2* mutations in UPS of bone yields insight into the biological difference between dedifferentiated chondrosarcoma and undifferentiated pleomorphic sarcoma of bone.

Among a total of 11 cases of dedifferentiated chondrosarcoma with *IDH1* mutations in this study, 1 case harbored an *IDH1* R132H mutation, which was also confirmed by immunostaining using monoclonal antibody. Although the *IDH1* R132H mutation occurs in approximately 70% of WHO grade II and III gliomas (7), it was detected in only 17% of the *IDH 1/2* mutations present in cartilaginous tumors in one study (14) and 0% (0/14 positive cases) in another study (15). While the *IDH1* R132H monoclonal antibody appears to be a reliable surrogate for mutation status, the low rate of its prevalence in dedifferentiated chondrosarcoma limits its usefulness in this setting.

In recent years there has been a strong and growing interest in performing molecular analysis of tumors in the era of precision medicine. Even if *IDH1/2* mutation status is not required for diagnosis, unique *IDH1/2* signatures detected in dedifferentiated chondrosarcoma may lead to a

new approach for effective targeted therapy which may result in better survival rates and prognosis. Recent in vitro study revealed that high doses of *IDH1* inhibitor AGI-5198 inhibited colony formation and migration, interrupted cell cycling, and induced apoptosis using chondrosarcoma cell lines, which revealed anti-tumor activity of the *IDH1* inhibitor (17). More in vitro and in vivo studies need to be performed to explore the possibility of finding specific and effective *IDH1/2* mutation inhibitors available for targeted therapy of dedifferentiated chondrosarcoma.

One potential drawback of performing mutational analysis on bone tumors is that the decalcification procedure involves hydrochloric acid which is known to cause DNA damage through chemical hydrolysis which has been previously discussed by Kerr and colleagues in their analysis of *IDH1/2* mutations in chondroblastic osteosarcoma (15). Consequently, tumor sections with significant bone matrix may be subjected to this process, often rendering them unsuitable for these studies. Eleven cases of conventional chondrosarcoma with unsuccessful mutation analysis were exposed to decalcification techniques (Table 1). Fortunately, the dedifferentiated component of dedifferentiated chondrosarcoma, as well as UPS of bone, often lacks osteoid or bone matrix. In our series, mutation analysis was successful in all 23 cases of dedifferentiated chondrosarcoma and 14 UPS of bone by selecting tissue sections not previously decalcified. Nonetheless, pathologists should be aware of the limitations of molecular analysis after decalcification procedures.

In summary, *IDH1/2* mutation analysis is a useful tool for distinguishing dedifferentiated chondrosarcoma from undifferentiated pleomorphic sarcoma of bone to help ensure accurate diagnosis and appropriate treatment for these patients. While there is no substitute for careful correlation with clinical and radiologic data in bone lesions, *IDH1/2* mutation analysis is an ancillary technique which may be employed particularly for biopsy specimens when clinical information is lacking or radiologic findings are equivocal. Finally, this study gives insight into the difference in pathogenesis between dedifferentiated chondrosarcoma and UPS of bone. If effective *IDH1/2* mutation inhibitors become available in the future, PCR mutation analysis on cases of dedifferentiated chondrosarcoma help guide treatment decisions.

Disclosure/conflict of interest

The authors declare no conflict of interest.

Acknowledgement

The authors thank Dr. Ulbright for making comments on this manuscript.

REFERENCES

1. Johnson S, Tetu B, Ayala AG, et al. Chondrosarcoma with additional mesenchymal component (dedifferentiated chondrosarcoma). I. A clinicopathologic study of 26 cases. *Cancer*. 1986;58:278-286.
2. Nishida J, Sim FH, Wenger DE, et al. Malignant fibrous histiocytoma of bone. A clinicopathologic study of 81 patients. *Cancer*. 1997;79:482-493.
3. Papagelopoulos PJ, Galanis EC, Sim FH, et al. Clinicopathologic features, diagnosis, and treatment of malignant fibrous histiocytoma of bone. *Orthopedics*. 2000;23:59-65; quiz 66-57.
4. Corey RM, Swett K, Ward WG. Epidemiology and survivorship of soft tissue sarcomas in adults: a national cancer database report. *Cancer Med*. 2014;3:1404-1415.
5. Yokota K, Sakamoto A, Matsumoto Y, et al. Clinical outcome for patients with dedifferentiated chondrosarcoma: a report of 9 cases at a single institute. *J Orthop Surg Res*. 2012;7:38.
6. Bramwell VH, Steward WP, Nooij M, et al. Neoadjuvant chemotherapy with doxorubicin and cisplatin in malignant fibrous histiocytoma of bone: A European Osteosarcoma Intergroup study. *J Clin Oncol*. 1999;17:3260-3269.
7. Yan H, Parsons DW, Jin G, et al. IDH1 and IDH2 mutations in gliomas. *N Engl J Med*. 2009;360:765-773.
8. Abbas S, Lugthart S, Kavelaars FG, et al. Acquired mutations in the genes encoding IDH1 and IDH2 both are recurrent aberrations in acute myeloid leukemia: prevalence and prognostic value. *Blood*. 2010;116:2122-2126.

9. Ward PS, Patel J, Wise DR, et al. The common feature of leukemia-associated IDH1 and IDH2 mutations is a neomorphic enzyme activity converting alpha-ketoglutarate to 2-hydroxyglutarate. *Cancer Cell*. 2010;17:225-234.
10. Abdel-Wahab O, Manshouri T, Patel J, et al. Genetic analysis of transforming events that convert chronic myeloproliferative neoplasms to leukemias. *Cancer Res*. 2010;70:447-452.
11. Sia D, Tovar V, Moeini A, et al. Intrahepatic cholangiocarcinoma: pathogenesis and rationale for molecular therapies. *Oncogene*. 2013;32:4861-4870.
12. Murugan AK, Bojdani E, Xing M. Identification and functional characterization of isocitrate dehydrogenase 1 (IDH1) mutations in thyroid cancer. *Biochem Biophys Res Commun*. 2010;393:555-559.
13. Yen KE, Bittinger MA, Su SM, et al. Cancer-associated IDH mutations: biomarker and therapeutic opportunities. *Oncogene*. 2010;29:6409-6417.
14. Amary MF, Bacsi K, Maggiani F, et al. IDH1 and IDH2 mutations are frequent events in central chondrosarcoma and central and periosteal chondromas but not in other mesenchymal tumours. *J Pathol*. 2011;224:334-343.
15. Kerr DA, Lopez HU, Deshpande V, et al. Molecular distinction of chondrosarcoma from chondroblastic osteosarcoma through IDH1/2 mutations. *Am J Surg Pathol*. 2013;37:787-795.
16. Meijer D, de Jong D, Pansuriya TC, et al. Genetic characterization of mesenchymal, clear cell, and dedifferentiated chondrosarcoma. *Genes Chromosomes Cancer*. 2012;51:899-909.
17. Li L, Paz AC, Wilky BA, et al. Treatment with a Small Molecule Mutant IDH1 Inhibitor Suppresses Tumorigenic Activity and Decreases Production of the Oncometabolite 2-Hydroxyglutarate in Human Chondrosarcoma Cells. *PLoS One*. 2015;10:e0133813.

18. Tinoco G, Wilky BA, Paz-Mejia A, et al. The biology and management of cartilaginous tumors: a role for targeting isocitrate dehydrogenase. *Am Soc Clin Oncol Educ Book*. 2015;35:e648-655.
19. Dang L, White DW, Gross S, et al. Cancer-associated IDH1 mutations produce 2-hydroxyglutarate. *Nature*. 2009;462:739-744.
20. Lu C, Venneti S, Akalin A, et al. Induction of sarcomas by mutant IDH2. *Genes Dev*. 2013;27:1986-1998.
21. Cairns RA, Mak TW. Oncogenic isocitrate dehydrogenase mutations: mechanisms, models, and clinical opportunities. *Cancer Discov*. 2013;3:730-741.
22. Imielinski M, Berger AH, Hammerman PS, et al. Mapping the hallmarks of lung adenocarcinoma with massively parallel sequencing. *Cell*. 2012;150:1107-1120.
23. Sahm F, Schrimpf D, Jones DT, et al. Next-generation sequencing in routine brain tumor diagnostics enables an integrated diagnosis and identifies actionable targets. *Acta Neuropathol*. 2016;131:903-910.
24. Li H, Durbin R. Fast and accurate short read alignment with Burrows-Wheeler transform. *Bioinformatics*. 2009;25:1754-1760.
25. Lai X, Chen S. Identification of novel biomarker candidates for immunohistochemical diagnosis to distinguish low-grade chondrosarcoma from enchondroma. *Proteomics*. 2015;15:2358-2368.

Figure legends:

FIGURE 1. Morphological features of malignant cartilaginous neoplasms and undifferentiated pleomorphic sarcoma of bone (objective lens x20, enlarged images in insets). A, Conventional chondrosarcoma shows atypical chondrocytes with enlarged and hyperchromatic nuclei. B, Dedifferentiated component of chondrosarcoma reveals atypical spindle and epithelioid cells with marked nuclear pleomorphism, hyperchromatism and prominent nucleoli. C, Dedifferentiated chondrosarcoma has an abrupt demarcation between the cartilaginous component and the dedifferentiated component. D, Undifferentiated pleomorphic sarcoma of bone shows atypical cells with nuclear pleomorphism, atypical mitosis and hyperchromatism without a specific line of differentiation.

FIGURE 2. Immunostaining for IDH1 R132H mutated enzyme (objective lens x40). A, Standard positive control glioma with cytoplasmic staining. B, Cytoplasmic staining in conventional chondrosarcoma harboring IDH1 R132H mutation. C, Cytoplasmic staining of dedifferentiated component of chondrosarcoma with IDH1 R132H mutation. D, Dedifferentiated component of chondrosarcoma without IDH1 R132H mutation shows lack of immunoreactivity (negative control).

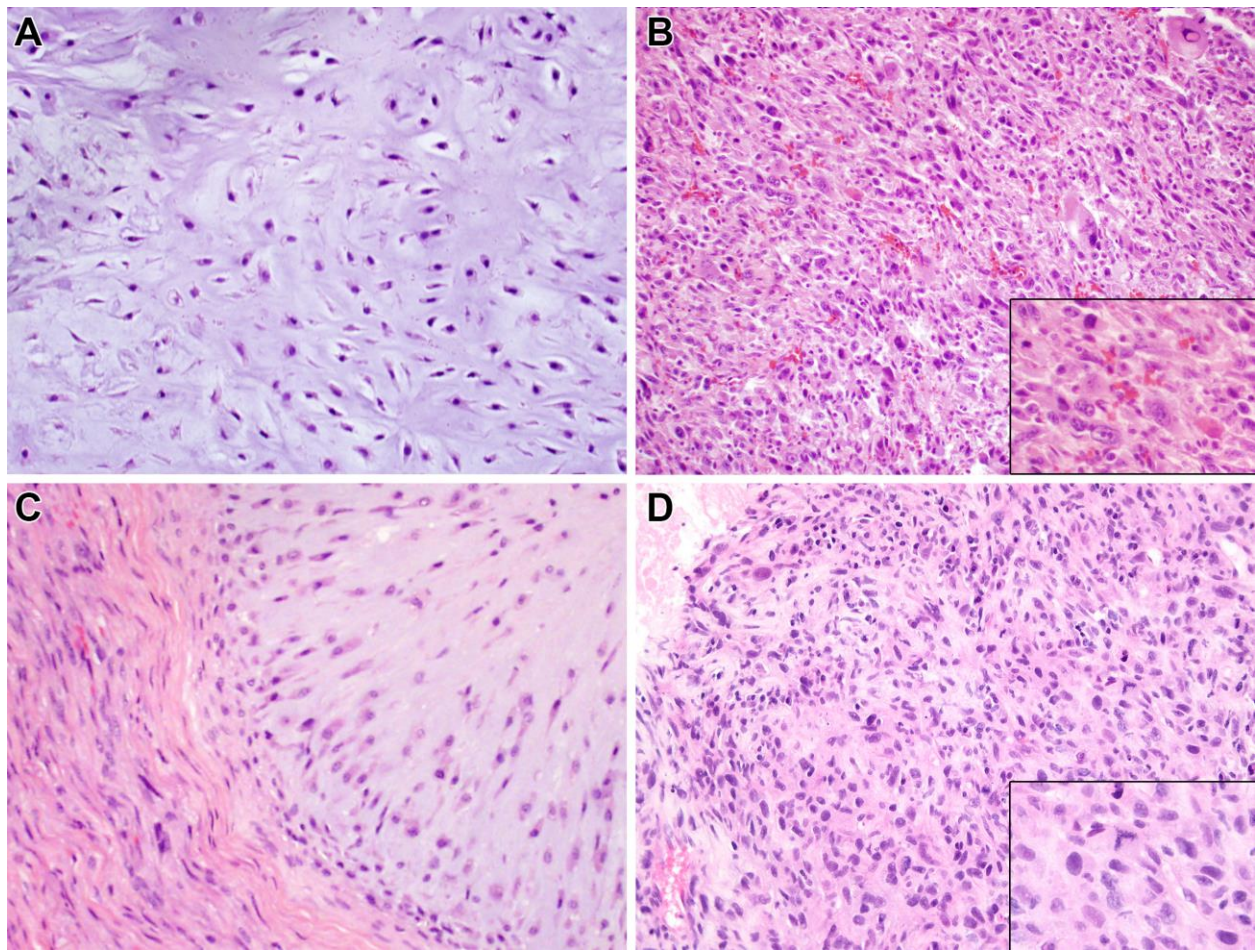


Figure 1

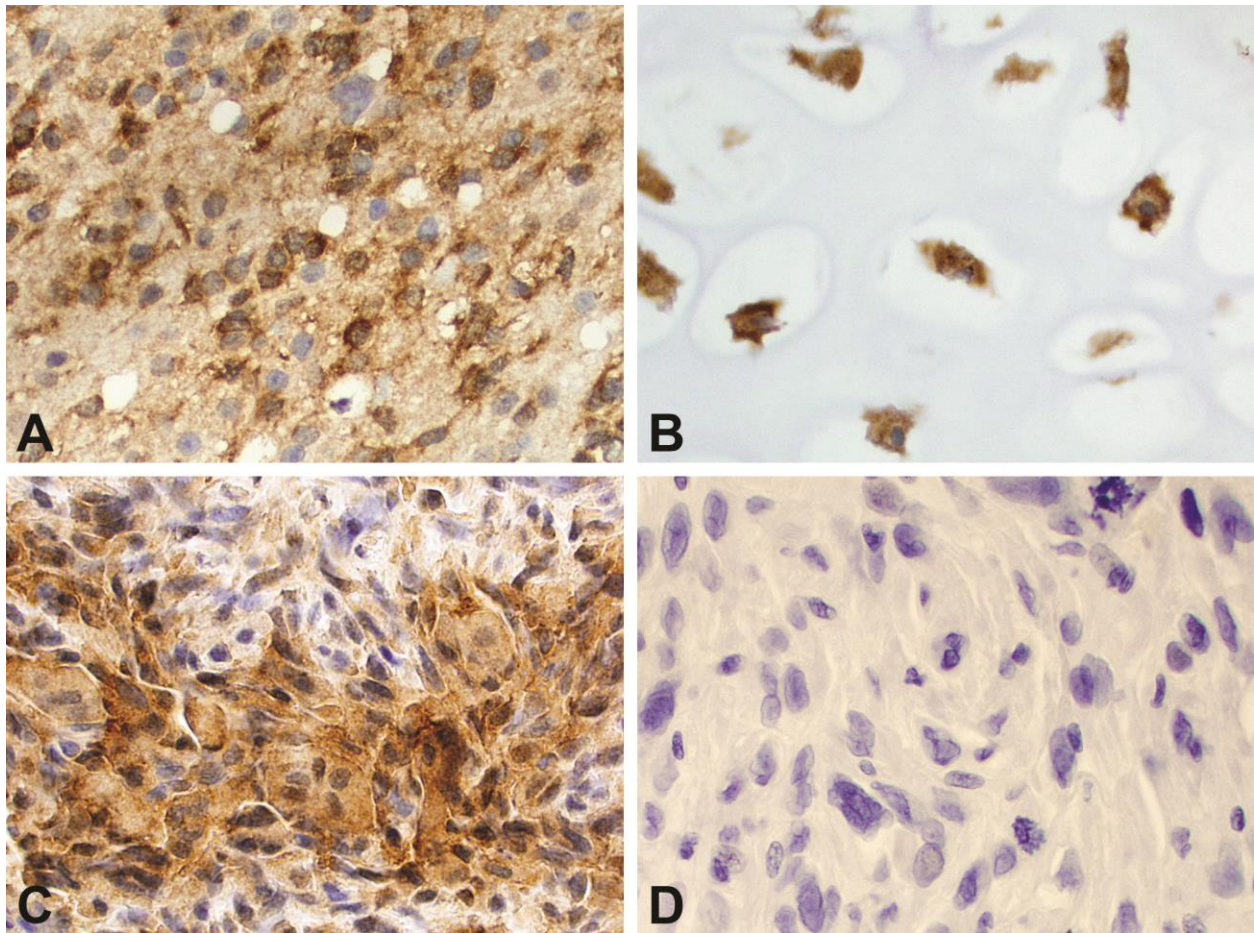


Figure 2

Table 1. Clinicopathologic Features and IDH1/2 Mutation Analysis of Conventional Chondrosarcoma Specimens

Cases	Age (y)	Sex	Site	Sample Class	Size (cm)	Grade	Decal	Mutation status
1	58	F	Humerus	Primary	5.0	G1	No	IDH1 R132H
2	75	M	Femur	Primary	9.0	G2	Yes	failed
3	48	M	Calcaneus	Primary	6.0	G1	Yes	failed
4	72	F	Rib	Primary	8.5	G1	No	WT
5	85	M	Rib	Primary	3.9	G1	No	WT
6	41	M	Pelvis	Primary	2.5	G1	Yes	failed
7	85	M	Femur	Primary	13.0	G1	Yes	failed
8	60	M	Pelvis	Primary	47.0	G2	No	WT
9	52	M	Femur	Primary	7.8	G2	No	IDH1 R132C
10	41	M	Sacrum	Primary	10.0	G2	No	WT
11	38	F	Fibula	Primary	3.5	G1	Yes	failed
12	87	F	Femur	Primary	7.0	G2	No	WT
13	77	F	Pelvis	Primary	7.0	G1	Yes	failed
14	43	M	Femur	Primary	6.0	G1	Yes	failed
15	38	M	Rib	Primary	13.3	G2	No	WT
16	27	M	Fibula	Primary	8.0	G1	Yes	failed
17	81	M	Femur	Primary	20.0	G1-2	Yes	failed
18	40	F	Pelvis	Primary	18.0	G1-2	No	WT
19	78	M	Femur	Primary	9.8	G1	No	IDH1 R132C
20	69	F	Femur	Primary	24.0	G2	Yes	failed
21	51	M	Femur	Primary	17.0	G2	No	IDH2 R172
22	32	M	Scapula	Primary	6.0	G1	Yes	failed
23	59	M	Sacrum	Recur	10.0	G2	No	WT
24	67	M	Femur	Primary	13.5	G2-3	No	IDH1 R132
25	57	M	Sternum and rib	Primary	11.2	G2	No	WT
26	59	M	Sacrum	Primary	4.0	G2	No	WT
27	57	M	Sacrum	Primary	5.0	G2	No	WT
28	31	M	Femur	Primary	10.0	G2	No	IDH2 R172
29	43	F	Cricoid	Primary	1.5	G2	No	WT
30	65	M	Cricoid	Primary	3.8	G2	No	WT
31	47	M	Pelvis	Primary	10.0	G2	No	WT

Abbreviations: IDH, isocitrate dehydrogenase; ST, soft tissue; WT, wild type.

Table 2. Clinicopathologic Features and IDH1/2 Mutation Analysis of Dedifferentiated Chondrosarcoma Specimens

Cases	Age (y)	Sex	Site	Size (cm)	C-CHS grading	C-CHS mutation	Dediff CHS Decal	Dediff CHS mutation
1	63	F	Femur	8.0	G2	Not tested	No	IDH1 R132
2	60	M	Humerus	10.0	G1	failed	No	IDH2 R172
3	95	F	Humerus	7.0	G1	Not tested	No	IDH2 R172
4	63	M	Femur	4.2	G3	Not tested	No	IDH2 R172
5	63	F	Femur	15.0	G2	failed	No	IDH1 R132C
6	73	M	Humerus	15.8	G3	failed	No	IDH2 R172
7	72	F	Humerus	9.5	G2	failed	No	WT
8	58	F	Pelvis	8.5	G2	failed	No	IDH1 R132C
9	70	M	Femur	6.0	G2	failed	No	IDH1 R132
10	64	M	Tibia	21.0	Unknown	Not tested	No	IDH1 R132
11	36	M	Humerus /Scapula	26.0	G3	failed	No	IDH1 R132C
12	72	F	Pelvis	5.5	G1	failed	No	IDH1 R132C
13	43	M	Coracoid Process	12.0	G1	IDH1 R132	No	IDH1 R132
14	68	F	Femur	18.0	G2	failed	No	IDH2 R172
15	82	M	Femur	7.5	Unknown	Not tested	No	IDH1 R132C
16	78	M	Femur	15.0	G1	failed	No	IDH2 R172
17	58	M	Liver (met)	Unknown	Unknown	Not tested	No	WT
18	69	M	Humerus	15.2	G1	failed	No	IDH2 R172
19	57	M	Pelvis	7.7	Unknown	Not tested	No	IDH1 R132H
20	72	M	Pelvis	10.0	G2	IDH2 R172	No	IDH2 R172
21	62	M	Femur	9.7	G2	failed	No	IDH2 R172
22	67	F	Pelvis	7.8	G2	failed	No	WT
23	72	F	Humerus	17.0	G1	IDH1 R132	No	IDH1 R132

Abbreviations: C-CHS, conventional component of chondrosarcoma; dediff CHS, dedifferentiated component of chondrosarcoma.

met: metastatic; WT: wild type.

Table 3. Clinicopathologic Features and IDH1/2 Mutation Analysis of Undifferentiated Pleomorphic Sarcomas of Bone

Cases	Age (y)	Sex	Site	Size (cm)	Grade	Decal	Mutation
1	73	F	Left tibia	6.2	High	No	WT
2	82	F	Right femur	6.0	High	No	WT
3	82	M	Right humerus	8.5	High	No	WT
4	63	M	Left femur	10.0	High	No	WT
5	67	M	Right femur	7.5	High	No	WT
6	86	F	Left femur	7.5	High	No	WT
7	41	M	Left femur	7.0	High	No	WT
8	68	F	Right tibia	3.0	High	No	WT
9	45	F	Left femur	11.0	High	No	WT
10	71	M	Right leg	9.0	High	No	WT
11	25	F	Left femur	11.0	High	No	WT
12	88	F	Right femur	12.5	High	No	WT
13	24	F	left fibula	8.5	High	No	WT
14	88	F	Right femur	8.5	High	No	WT

Highlights

- Morphologically difficult to distinguish the dedifferentiated chondrosarcoma from UPS of bone
- Identification of *IDH1/2* mutations supports the diagnosis of dedifferentiated chondrosarcoma
- *IDH1/2* mutation analysis using Qiagen IDH1/2 RGQ PCR Kit can be performed in any laboratory