

Synchrotron X-ray diffraction to understand crystallographic texture of enamel affected by Hunter syndrome

Khan, Malik Arshman; Addison, Owen; James, Alison; Hendriksz, Christian J.; Al-jawad, Maisoon

DOI:

[10.1016/j.archoralbio.2017.04.019](https://doi.org/10.1016/j.archoralbio.2017.04.019)

License:

Creative Commons: Attribution-NonCommercial-NoDerivs (CC BY-NC-ND)

Document Version

Peer reviewed version

Citation for published version (Harvard):

Khan, MA, Addison, O, James, A, Hendriksz, CJ & Al-jawad, M 2017, 'Synchrotron X-ray diffraction to understand crystallographic texture of enamel affected by Hunter syndrome', *Archives of Oral Biology*, vol. 80, pp. 193-196. <https://doi.org/10.1016/j.archoralbio.2017.04.019>

[Link to publication on Research at Birmingham portal](#)

General rights

Unless a licence is specified above, all rights (including copyright and moral rights) in this document are retained by the authors and/or the copyright holders. The express permission of the copyright holder must be obtained for any use of this material other than for purposes permitted by law.

- Users may freely distribute the URL that is used to identify this publication.
- Users may download and/or print one copy of the publication from the University of Birmingham research portal for the purpose of private study or non-commercial research.
- User may use extracts from the document in line with the concept of 'fair dealing' under the Copyright, Designs and Patents Act 1988 (?)
- Users may not further distribute the material nor use it for the purposes of commercial gain.

Where a licence is displayed above, please note the terms and conditions of the licence govern your use of this document.

When citing, please reference the published version.

Take down policy

While the University of Birmingham exercises care and attention in making items available there are rare occasions when an item has been uploaded in error or has been deemed to be commercially or otherwise sensitive.

If you believe that this is the case for this document, please contact UBIRA@lists.bham.ac.uk providing details and we will remove access to the work immediately and investigate.

Accepted Manuscript

Title: Synchrotron X-ray diffraction to understand crystallographic texture of enamel affected by Hunter syndrome

Author: Malik Arshman Khan Owen Addison Alison James
Christian J. Hendriksz Maisoon Al-Jawad



PII: S0003-9969(17)30129-2
DOI: <http://dx.doi.org/doi:10.1016/j.archoralbio.2017.04.019>
Reference: AOB 3863

To appear in: *Archives of Oral Biology*

Received date: 6-11-2016
Revised date: 28-2-2017
Accepted date: 17-4-2017

Please cite this article as: Khan MA, Addison O, James A, Hendriksz CJ, Al-Jawad M, Synchrotron X-ray diffraction to understand crystallographic texture of enamel affected by Hunter syndrome., *Archives of Oral Biology* (2017), <http://dx.doi.org/10.1016/j.archoralbio.2017.04.019>

This is a PDF file of an unedited manuscript that has been accepted for publication. As a service to our customers we are providing this early version of the manuscript. The manuscript will undergo copyediting, typesetting, and review of the resulting proof before it is published in its final form. Please note that during the production process errors may be discovered which could affect the content, and all legal disclaimers that apply to the journal pertain.

Synchrotron X-ray diffraction to understand crystallographic texture of enamel affected by Hunter syndrome.

Malik Arshman Khana, Owen Addisonb, Alison Jamesc, Christian J. Hendrikszd, Maisoon Al-Jawada

a Queen Mary University of London, Barts and the London School of Medicine and Dentistry, Institute of Dentistry, London E1 4NS, UK

b University of Birmingham, School of Dentistry, Birmingham B4 6NN, UK

c Birmingham Children's Hospital NHS Foundation Trust, Birmingham, B4 6NH, UK

d Manchester Academic Health Science Centre, The Mark Holland Metabolic Unit, Salford Royal Foundation NHS Trust, Ladywell NW2-2nd Floor Room 112, Salford, Manchester. M6 8HD, UK

Corresponding Author: Malik Arshman Khan

Email address: arshman.khan86@gmail.com<mailto:arshman.khan86@gmail.com>

Contact Number: +923335117505<tel:+923335117505>

Present Address: Abbottabad International Medical College (Dental Section), Mansehra Road, P.O Public School, Abbottabad, Pakistan.

Synchrotron X-ray diffraction to understand crystallographic texture of enamel affected by Hunter syndrome.

Abstract

Objective : To determine whether Hunter syndrome (MPS II) affects the crystallographic texture (preferred orientation) of enamel.

Design: Synchrotron X-ray diffraction being a state of the art technique has been used to determine the enamel crystallite orientation in enamel affected by Hunter syndrome (MPS II). The incisal, lingual and cervical regions of the MPS II affected tooth was observed and compared to healthy tooth.

Results: It was observed that there is a loss of organization of crystallites in deciduous incisal enamel affected by Hunter syndrome (MPS II) as compared to healthy deciduous enamel tissue. Generally it was observed that, in contrast to the healthy enamel, the enamel affected by MPS II possessed a lower crystallographic preferred orientation, with a more uniform spatial distribution, however the enamel at the incisal tip was relatively unaffected.

Conclusion: Hunter syndrome affects the enamel texture in the lingual and cervical regions of the tooth.

Keywords: Synchrotron X-ray Diffraction, Enamel Texture, Mucopolysaccharidosis II, Preferred Orientation.

1. Introduction

The human enamel is a hard mineralized tissue which consists of nanorod-like hydroxyapatite crystallites which are arranged into a highly organized prism (Wu et al., 2013). At times the orientation or texture of these enamel crystallites can be affected by genetic and metabolic disorders. Hunter syndrome or Mucopolysaccharidosis II (OMIM 309900) is an X-linked lysosomal storage disorder caused by the deficiency of an enzyme known as iduronate-2-sulfatase which is required for the breakdown of glycosaminoglycans (GAGs) (Bach et al., 1973). Accumulation of glycosaminoglycans in cells, tissues, and organs produces a multi-systemic disease (Neufeld and Muenzer, 2001, Martin et al., 2008). The progressive cellular damage caused by the accumulation of GAGs affects physical abilities, appearance, organs and mental development. Clinically the patient presents with neurological involvement, hepatosplenomegaly, joint stiffness, pulmonary dysfunction, valvular dysfunction and myocardial enlargement (Wraith et al., 2008, Martin et al., 2008, Kliegman et al., 2007, Tuschl et al., 2005, Shah et al., 2010).

Data collected from Germany and Netherlands indicates that the incidence of MPS II is 1.3 per 100,000 male live births suggesting it is a rare metabolic disorder (Baehner et al., 2005, Poorthuis., 1999). MPS II is classified into an attenuated and severe type and this classification is based on the length of survival and the presence or absence of central nervous system disease. In both types the patients appear normal at birth with exception of frequently a larger than normal head circumference. In the attenuated type of MPS II the clinical features appear in the second decade of life whereas in the severe type the clinical features tend to appear between two and four years of age (Tuschl et al., 2005, Shah et al., 2010) however experts can see the features from about six months of age. The use of synchrotron X-ray diffraction to characterize structural disruption of hard tissues at the subnano and nano-scale can help us understand when the disruption to musculo-skeletal processes may occur. In particular since there is no enamel tissue turn over, the study of the enamel in deciduous teeth would give idea of the developmental stage

in utero or after birth that the disruption occurs. This could act as an earlier marker for diagnosis than the other symptoms which don't appear till later in life, and allow the potential for early treatment.

2. Materials and methods

2.1. Specimen preparation

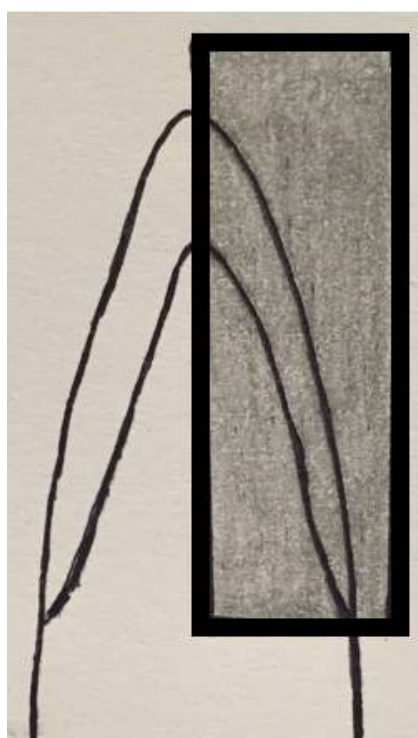The samples used in this study were a deciduous maxillary central incisor collected from an individual affected by Hunter syndrome (MPS II) and healthy deciduous maxillary central incisor which was used as a control. The specimens were collected following ethical approval (UK National Research Ethics Service Reference 08/H1202/119) and consent at the Birmingham Children's Hospital NHS Foundation Trust, Birmingham, United Kingdom. The extracted teeth were stored in 4% thymol-saline solution in order to preserve hydration and prevent bacterial growth. The tooth samples were cut labio-lingually into longitudinal section of 0.5 mm thickness using a diamond blade cutter (Accutom-5, Struers A/S, Ballerup, Denmark) in order to carry out the synchrotron X-ray diffraction experiment.

2.2. Experimental procedure

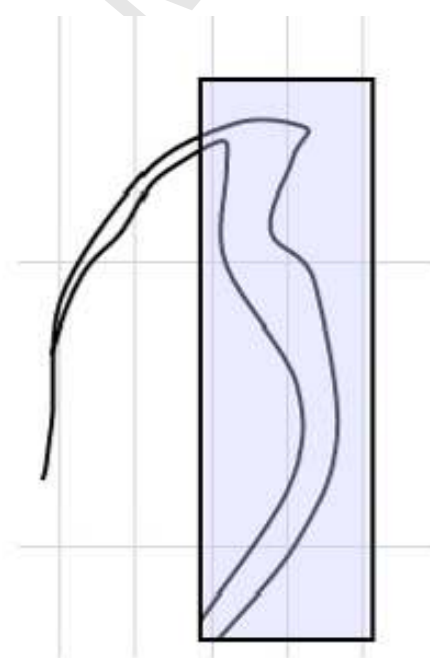
2D X-ray diffraction patterns were collected on the XMaS beamline (BM28) at the European Synchrotron Radiation Facility (ESRF) situated in Grenoble, France. The prepared sample was mounted onto horizontal and vertical translation stages in order to move the sample perpendicular to the X-ray beam, to create a map of region of interest from the samples. The areas selected from each sample are shown in Figure 1. The sample to detector distance was 170 mm and an X-ray wavelength of 0.82\AA was used. A beam spot size of $150\text{ }\mu\text{m}$ was used with a run time of 5 s to collect images using the MAR CCD detector (Khan et al., 2016).

2.3. Data analysis

The diffraction images of enamel collected from the sample were processed using the Fit2d software (Hammersley, 1997). The azimuthal variation in intensity around the Debye ring of the 002 Bragg reflection present in the diffraction image was used to determine the degree of texture in enamel. A Gaussian peak shape was fitted and the values of full width half maximum (FWHM) were extracted, this indicates the level of preferred orientation in enamel where low values of FWHM represent high preferred orientation and vice versa. The (FWHM) values for all the diffraction images were assembled to create 2D spatial texture maps. A high value of FWHM suggests that there is low enamel texture or low degree of preferred orientation in the enamel crystallites whereas a low value of FWHM suggests that there is high enamel texture or high degree of preferred orientation in the enamel crystallites (Khan et al., 2016).



a)



b)

Figure. 1 : shows a schematic diagram of a) MPS II affected deciduous maxillary central incisor with the grey box representing the area of analysis and b) healthy deciduous maxillary central incisor with the blue box representing the area of analysis (Taken from Khan et al., 2016).

2.4 Marking Angulation On 2D Diffraction Pattern

The azimuthal angle for a particular peak was used to mark angulation on a 2D diffraction pattern in order to indicate the direction of the enamel crystallite as shown in Figure.2.

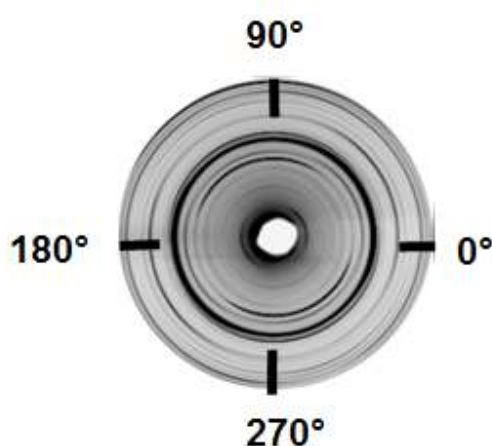


Figure.2 : shows the standard angulations on a 2D diffraction pattern.

3. Results and Discussion

Figure. 3 shows a comparison between the texture maps of a) MPS II affected deciduous maxillary central incisor and b) healthy deciduous maxillary central incisor respectively with the red arrow indicating the incisal surface, green arrow indicating the lingual aspect and the colour scale representing the FWHM (Full Width Half Maximum) values for these teeth indicating the degree of preferred orientation or the texture of enamel.

Figure. 4 shows a comparison between the composite images of MPS II affected deciduous maxillary central incisor and healthy deciduous maxillary central incisor, showing the enamel crystallite orientation directions. The blue arrow indicates the incisal surface whereas the green arrow indicates the lingual aspect.

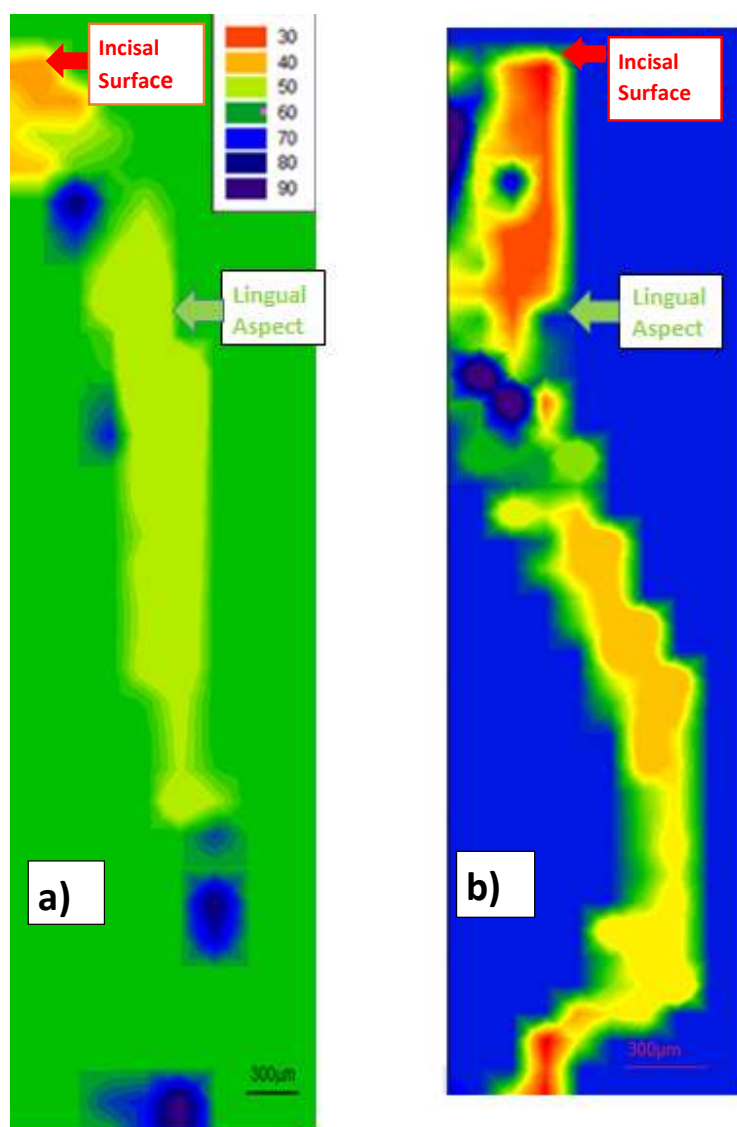


Figure.3: shows comparison between the texture maps of a) MPS II affected and b) healthy deciduous maxillary central incisors. Texture map of healthy deciduous maxillary central incisor (Taken from Khan et al., 2016).




Figure.4 : shows comparison between the composite images of a) MPS II affected and b) healthy deciduous maxillary central incisors. The red arrows indicate the two fiber axes effect.

The texture distribution map of both MPS II affected deciduous maxillary central incisor and healthy enamel (Figure 3) shows that the incisal surface has a high enamel texture or preferred orientation and on progression towards the EDJ (Enamel-Dentine Junction) there is a decrease in the enamel texture. Additionally in general in both specimens the enamel texture is greatest at the incisal tip and decreases along the lingual aspect of the tooth being lowest at the cervical region indicating that this region may be weaker and more prone to fracture. Figure 3 indicates that the texture in the MPS II affected enamel is in general lower than in healthy incisal enamel (on average higher values of FWHM) and is spatially more homogenous as compared to healthy enamel that appears as a highly spatially graded structure. An important finding in this study is the high enamel texture present at the incisal surface of the MPS II enamel which appears to be less affected than the rest of the enamel tissue. It is possible that this is related to the temporal maturation of the enamel. Since it is known that the incisal or cuspal tips lay down mineral at an earlier timepoint than the cervical region (Simmons et al., 2013), and it is known that the build up of GAGs gets progressively worse as a function of time, we hypothesize that the GAGs built-up is less severe in the tips hence higher texture in the structure, whereas by the time bulk of the enamel and the cervical region are forming, the accumulating GAGs are affecting the enamel formation more severely. Our hypothesis is strengthened by the fact that this phenomenon has also been observed in enamel affected by Morquio syndrome (MPS IVA) (Khan et al., 2016). We believe that the orientation of enamel crystallites at the incisal surface prevents the loss of

enamel texture even in the presence of GAGs, the enamel crystallites are so well oriented, almost parallel to the long axis of tooth oriented at an angle ranging from 70 to 90 degrees (as shown in Figure 4) allowing the incisal surface to bear any load or stress. Studies done on the cusp of human enamel by Boyde suggest that the mean crystallite direction is parallel with the axes of prism and this allows the biting surface to bear the masticatory loads well (Boyde, 1976). On progression towards the cervical region in MPS II affected deciduous maxillary central incisor, the enamel crystallites are no longer parallel to the long axis of the tooth, instead are oriented at an angle ranging from 40 to 50 degrees indicating a change in enamel texture direction (as shown in Figure 4), the enamel crystallites present in the cuspal/ incisal regions are well aligned but as there is progression deeper in to the enamel away from the surface the enamel crystallites become less ordered (Al-Jawad et al., 2007). In comparison, the healthy deciduous maxillary central incisor has higher enamel texture overall and higher spatial heterogeneity in the texture distribution (as shown in Figure 3) whereas better enamel texture is observed in the lingual aspect of the healthy tooth. This is in agreement with the enamel crystallite orientation which are almost parallel to the long axis of tooth in a specific portion of cingulum area as shown in Figure 4. A similarity between the MPS affected and healthy tooth was observed which was the high enamel texture at the incisal surface suggesting that GAGs may not affect the enamel texture at the incisal surface of MPS II affected tooth.

Our study suggests that Hunter syndrome (MPS II) affects the crystallographic texture of enamel and is in coherence with a previous study which suggests that Hurler syndrome (MPS I) and Morquio syndrome (MPS IVA) affect the texture of enamel, rendering the tooth structure weak and prone to fracture (Khan et al., 2016). Previously there have been no reports of enamel defects associated with Hunter syndrome (MPS II), however in our study we clearly see

disturbances in the organisation of enamel crystallites affected by Hunter syndrome (MPS II). Accumulation of GAGs in the dental follicle of developing teeth in other MPS diseases, such as Hurler syndrome (MPS I) has been reported in the past but dental abnormalities are not always clinically obvious. It may be in MPS II the disruption affects the nanostructure of enamel but has not yet been detected clinically on the macroscale (Gardner, 1971, Al-Jawad et al., 2012).

4. Conclusion

Our study suggests that the enamel texture or preferred orientation of enamel crystallites is affected by Hunter syndrome (MPS II) particularly in the lingual and cervical region of the deciduous maxillary central incisor rendering these regions potentially weak and prone to fracture when compared to healthy deciduous enamel, the healthy enamel has a higher enamel texture overall. In MPS II, there is a possibility that the accumulation of GAGs in the enamel affects the later stages of enamel formation hence the crystallographic texture of incisal surface is less affected than the bulk and cervical enamel.

Acknowledgements

This work was performed on the EPSRC-funded XMaS beamline at the ESRF, directed by M.J. Cooper, C.A Lucas and T.P.A Hase. We are grateful to the beamline team of S.D. Brown, O. Bikondoa, D. Wermeille, L. Bouchenoire and P. Thompson for their invaluable assistance and to S. Beaufoy and J. Kervin for additional support.

References

- Al-Jawad M, Addison O, Khan MA, James A, Hendriksz CJ 2012. Disruption of enamel crystal formation quantified by synchrotron microdiffraction. *Journal of Dentistry*, 40, 1074-1080.
- Al-Jawad M, Streuwer A, Kilcoyne SH, Shore RC, Cywinski R. 2007. 2D mapping of texture and lattice parameters of dental enamel. *Biomaterials*, 28, 2908-2914.
- Bach G, Eisenberg F Jr, Cantz M, Neufeld EF 1973. The defect in the Hunter syndrome: deficiency of sulfiduronate sulfatase. *Proc Natl Acad Sci USA* 70, 2134–2138.
- Baehner F, Schmiedeskamp C, Krummenauer F, Miebach E, Bajbouj M, Whybra C, Kohlschutter A, Kampmann C, Beck M 2005. Cumulative incidence rates of the mucopolysaccharidoses in Germany. *J Inherit Metab Dis*, 28, 1011–1017.
- Boyde A 1976. Amelogenesis and the structure of enamel. In: *Scientific Foundation of Dentistry* (Edited by Cohen B and Kramer I.R.H.). *Heinemann*, 335-52.
- Gardner DG 1971. The oral manifestations of Hurler's syndrome. *Oral Surgery Oral Medicine Oral Pathology*, 32, 46–57.
- Hammersley AP 1997. FIT2D: an introduction and overview. *ESRF Internal Report ; ESRF97HA02T*.
- Khan MA, Addison O, James A, Hendriksz CJ, Al-Jawad M 2016. Synchrotron X-ray diffraction and scanning electron microscopy to understand enamel affected by metabolic disorder mucopolysaccharidosis. *Micron*, 83, 48-53.
- Kliegman RM, Behrman RE, Jenson HB, Stanton FB 2007. 18th ed. Vol. 1. Philadelphia: Saunders; Nelson Textbook of Pediatrics; pp. 620–6.
- Martin R, Beck M, Eng C, Giugliani R, Harmatz P, Muñoz V, Muenzer J 2008. Recognition and diagnosis of mucopolysaccharidosis II (Hunter syndrome) *Pediatrics*, 121, 377–86.

Neufeld EF, Muenzer J 2001. The mucopolysaccharidoses. In: Scriver CR, Beaudet AL, Sly WS, Valle D (eds). *The Metabolic and Molecular Bases of Inherited Disease*, vol. III. McGraw-Hill: New York, 3421–3452.

Poorthuis BJ, Wevers RA, Kleijer WJ, Groener JE, de Jong JG, van Weely S, Niezen-Koning KE, van Diggelen OP 1999. The frequency of lysosomal storage diseases in The Netherlands. *Hum Genet*, 105, 151–156.

Shah GS, Mahal T, Sharma S 2010. Atypical clinical presentation of mucopolysaccharidosis type II (Hunter syndrome): A case report. *J Med Case Reports*, 4:154.

Simmons LM, Montgomery J, Beaumont J, Davis GR, Al-Jawad M 2013. Mapping the spatial and temporal progression of human dental enamel biomineralization using synchrotron X-ray diffraction. *Arch Oral Biol*, 58(11), 1726-1734.

Tuschl K, Gal A, Paschke E, Kircher S, Bodamer OA 2005. Mucopolysaccharidosis Type II in females: Case report and review of literature. *Pediatr Neurol*, 32, 270–2.

Wraith JE, Scarpa M, Beck M, Bodamer OA, Meirleir LD, Guffon N, Meldgaard Lund A, Malm G, Van der Ploeg AT, Zeman J 2008. Mucopolysaccharidosis Type II (Hunter syndrome): A clinical review and recommendations for treatment in the era of enzyme replacement therapy. *Eur J Pediatr*, 167, 267–77.

Wu D, Yang J, Li J, Chen L, Tang B, Chen X, Wu W, Li J 2013. Hydroxyapatite-anchored dendrimer for in situ remineralization of human tooth enamel. *Biomaterials*, 34 (21), 5036-5047.

Highlights

- Synchrotron X-ray diffraction is a state of the art technique that has been used to determine the orientation of enamel crystallites.

-Enamel in hunter syndrome has poor crystallite organization.

-In Hunter syndrome, the organization of crystallites at the enamel incisal surface is less affected when compared to bulk and cervical enamel.