

Can intra-operative fluorescence play a significant role in hepatobiliary surgery?

Jones, A.D.; Wilton, Joanne

DOI:

[10.1016/j.ejso.2017.02.015](https://doi.org/10.1016/j.ejso.2017.02.015)

License:

Creative Commons: Attribution-NonCommercial-NoDerivs (CC BY-NC-ND)

Document Version

Peer reviewed version

Citation for published version (Harvard):

Jones, AD & Wilton, J 2017, 'Can intra-operative fluorescence play a significant role in hepatobiliary surgery?', *European Journal of Surgical Oncology (EJSO)*. <https://doi.org/10.1016/j.ejso.2017.02.015>

[Link to publication on Research at Birmingham portal](#)

General rights

Unless a licence is specified above, all rights (including copyright and moral rights) in this document are retained by the authors and/or the copyright holders. The express permission of the copyright holder must be obtained for any use of this material other than for purposes permitted by law.

- Users may freely distribute the URL that is used to identify this publication.
- Users may download and/or print one copy of the publication from the University of Birmingham research portal for the purpose of private study or non-commercial research.
- User may use extracts from the document in line with the concept of 'fair dealing' under the Copyright, Designs and Patents Act 1988 (?)
- Users may not further distribute the material nor use it for the purposes of commercial gain.

Where a licence is displayed above, please note the terms and conditions of the licence govern your use of this document.

When citing, please reference the published version.

Take down policy

While the University of Birmingham exercises care and attention in making items available there are rare occasions when an item has been uploaded in error or has been deemed to be commercially or otherwise sensitive.

If you believe that this is the case for this document, please contact UBIRA@lists.bham.ac.uk providing details and we will remove access to the work immediately and investigate.

Accepted Manuscript

Can intra-operative fluorescence play a significant role in Hepatobiliary surgery?

Dr Alexander David Jones, Joanne Wilton, Prof

PII: S0748-7983(17)30362-1

DOI: [10.1016/j.ejso.2017.02.015](https://doi.org/10.1016/j.ejso.2017.02.015)

Reference: YEJSO 4607

To appear in: *European Journal of Surgical Oncology*


Received Date: 22 August 2016

Revised Date: 17 February 2017

Accepted Date: 24 February 2017

Please cite this article as: Jones AD, Wilton J, Can intra-operative fluorescence play a significant role in Hepatobiliary surgery?, *European Journal of Surgical Oncology* (2017), doi: 10.1016/j.ejso.2017.02.015.

This is a PDF file of an unedited manuscript that has been accepted for publication. As a service to our customers we are providing this early version of the manuscript. The manuscript will undergo copyediting, typesetting, and review of the resulting proof before it is published in its final form. Please note that during the production process errors may be discovered which could affect the content, and all legal disclaimers that apply to the journal pertain.



Can intra-operative fluorescence play a significant role in Hepatobiliary surgery?

Authors:

Dr Alexander David Jones, Prof Joanne Wilton.

Institute:

University of Birmingham, Edgbaston, Birmingham, B15 2TT

Corresponding author:

Dr Alexander David Jones, 61 Allesley Hall Drive, Coventry, CV5 9NS, alex.jones6@nhs.net,

07773605504

Nil funding was received

Abstract:

Liver resection remains the cornerstone of curative treatment for hepatocellular carcinoma and colorectal cancer liver metastases. Its success is dependent upon the extent of resection achieved. To this end, intra-operative imaging techniques have been experimented with to aid the surgeon. Fluorescence guided surgery (FGS) utilises the properties of near infrared light emitting molecules to identify malignant tissue, enabling the surgeon to maximise resection of diseased tissue and minimise collateral damage. Data from early trials showed increased superficial lesion detection when using fluorescence to guide liver resection. However, with far greater tissue penetration, intra-operative ultrasound (IOUS) remains the gold-standard intra-operative imaging modality. Subsequent trials have shown that the concomitant use of both FGS and IOUS may increase tumour detection rates intra-operatively. This review provides a comprehensive analysis of the most compelling evidence regarding fluorescence in hepatobiliary surgery and addresses the challenges faced introducing it into common practice.

Key words: Fluorescence guided surgery, liver resection, hepatocellular carcinoma, liver metastases

Can intra-operative fluorescence play a significant role in Hepatobiliary surgery?

Principles of live fluorescence in oncological surgery

Surgical resection remains the cornerstone of curative treatment for solid tumours. Its success is dependent upon the extent of resection achieved. The level of invasion by malignant tissue is assessed pre-operatively using imaging techniques such as computed tomography (CT) and magnetic resonant imaging (MRI). This allows staging of the disease and provides the surgeon with a blueprint of the local anatomy. Yet the pre-operative assessment often does not tell the whole story. Intra-operatively, the surgeon uses vision and palpation to assess the extent of tumour invasion and resects tissue accordingly. A trade-off occurs between removing malignant tissue and preserving vital structures, the relationship between the two often only becomes apparent during the procedure. Over the last decade, intra-operative imaging techniques have been experimented with to aid the surgeon maximise resection of diseased tissue and minimise collateral damage.

Fluorescence describes the phenomenon by which a molecule absorbs light of a particular wave-length (excitation) and emits it at a longer wave-length (emission) (1). Light within the visible spectrum resides between wave-lengths of 350-740nm and cannot penetrate tissue. However, near infra-red light (NIR) has wave-lengths between 750-1000nm and is able to penetrate tissue up to 10 mm in depth (1). To apply this in oncological surgery, a fluorescent marker taken up by malignant tissue is required. Non-specific markers, such as indocyanin-green (ICG) are the workhorses of fluorescence guided surgery (FGS) but specific fluorescent markers, guided by molecular targets are being developed. When malignant tissue (having taken up the fluorescent marker) is exposed to NIR light, it re-emits it. This is detected by a NIR camera system and images are merged with the white light images of the surgical field (Figure 1). The resulting images display the tumour in bright lights

compared with the surrounding healthy tissue. Not only are structures on the surface highlighted, but those up to 10mm in depth are also revealed. Theoretically, the advantages of this aiding resection of diseased tissue, whilst preserving healthy structures is evident, the question is whether it translates to improved patient outcomes.

(Insert figure 1) (2)

Value of the R0 resection in hepatobiliary malignancy

Hepatocellular Carcinoma (HCC) is a leading cause of cancer related death worldwide. Although only the 6th most common malignancy, it has the second highest mortality, resulting in over 700,000 deaths annually (3). The highest incidence rates are in China, Japan and throughout Africa, with incidence in Europe relatively low at 6 per 100,000 (4). Liver resection is the first line treatment for patients with localised, resectable tumours in the non-cirrhotic liver, or in selected patients with Child-Pugh A liver cirrhosis (5). It should be noted that with large tumours, or in the presence of cirrhosis, liver transplantation is often the preferred option. Outcomes of transplant in this setting are favourable, with 5- and 10-year survival rates reaching 62% and 51% respectively (6).

Tumour free resection margins is vital for good outcomes, with R1 resection having been shown to be the only prognostic indicator precluding >10 years survival (7). A randomised trial compared survival outcomes of patients with narrow (1cm) and wide (2cm) resection margins; the 1-, 2-, 3-, and 5-year overall survival rates for the narrow and the wide margin groups were 92.9%, 83.3%, 70.9%, and 49.1% and 96.5%, 91.8%, 86.9%, and 74.9%, respectively (8). Resection margin was a significant prognostic indicator for recurrence (OR 0.598), with all 13 recurrences at the transaction margin occurring within the narrow resection group. With careful selection of patients, 3-year and 5-

year survival rates for complete, tumour free resection (R0) is 54% and 39% respectively, compared with 23% and 0% for R1-2 resections (9).

Surgical resection of the liver is also vitally important for the management of colorectal cancer. Colorectal cancer rates have steadily increased in the UK since the late 1970s. In 2013, over 40,000 patients were diagnosed with it, an incidence of over 70 per 100,000 (10). The liver is often the first site of metastasis, with around 20-25% of patients with liver metastases at diagnosis and half of all patients going on to develop them in their lifetime (11). Unfortunately, survival without treatment is poor and it has become increasingly recognised that surgical resection is the only chance for long-term survival. This has been reflected in the increasing number of resections being performed in the UK, which rose from 1.7% in 1998, to 3.8% in 2004 (12). It is anticipated that 10-20% of patients with liver metastases have surgically resectable disease (13). This rise in resections is a direct result of the changing beliefs of what is considered resectable. Currently, surgically resectable disease is defined as the ability to perform R0 resection, sparing at least two liver segments with independent inflow, outflow and biliary drainage. The amount of the liver remnant after resection should not be less than 20% and 30% of the total liver volume in normal and cirrhotic patients, respectively (14). Once surgical management has been decided upon, obtaining R0 resection, whilst preserving healthy tissue is key, with significantly worse outcomes if tumour extends past the resection margin (15). In both of these scenarios, identification of malignant versus healthy tissue is vital to achieve good outcomes. It was the advances in the use of FGS during assessment of coronary artery bypass grafts and identification of lymph node metastases (16–18) that led surgeons to experiment with fluorescence in liver malignancy.

Fluorescence guided liver resections

Ishizawa et al.(18) published the first report detailing the use of ICG fluorescence to identify liver malignancy during resection. Their investigation commenced as they noted that HCCs fluoresced when performing fluorescence guided intra-operative cholangiography during a previous study (20). The following prospective study involved 49 patients undergoing resection for liver malignancy (37 HCC and 12 colorectal cancer liver metastases (CRLM)). All of the pathologically confirmed HCCs and CRLMs exhibited fluorescence when examined after resection. Intra-operatively, fluorescence imaging identified 21 of the 41 (51%) of the HCCs examined and all of the CRLM present. No tumours at a depth greater than 8mm were identified. This is perhaps the most significant finding and is predictable as near-infrared (NIR) light penetrates human tissue to depths of 5-10mm (21). In one patient with HCC, fluorescence imaging of the specimen identified a large volume of residual malignancy, not identified by examination which required further resection. ICG is excreted by hepatocytes into the bile canaliculi. It was surmised that liver malignancy, by disturbing biliary drainage, caused stasis and impaired excretion of ICG. As such, the malignancy fluoresced, whereas healthy tissue, having excreted ICG prior to the operation, does not.

(Insert figure 2) (22)

These results were echoed by other studies published at the time. Gotoh et al. (23) reported the results of a similar study involving 10 patients with HCCs. Their case series contained 4 malignant lesions first identified by fluorescence. Ishizawa et al. continued their work investigating the prospects of ICG FGS, publishing works regarding delineating the biliary tree and liver segments using ICG. In 2014 the Tokyo based team revealed the first use of FGS during laparoscopic hepatectomy (24). NIR fluorescence identified 75% of HCCs and 69% of liver metastases in 17 patients.

In the same year, Inoue et al. (25), published their use of 5-Aminolevulinic acid (5-ALA); a new fluorescent agent in Hepatobiliary surgery. Their aim was to establish whether 5-ALA fluorescence was advantageous as an adjunct to liver resection in 70 consecutive patients undergoing liver resection for HCC (n=37), CRLM (n=31), intraductal papillary carcinoma (n=1) and hemangiosarcoma (n=1). 342 patients who underwent liver resection between 2007 and 2011 were used as controls. HCC detection was similar during FGS and white light surgery; 64.9% versus 62.1% respectively. White light was marginally better detecting CRLM; 67.7% compared with 58.0% during FGS. It is not discussed whether identification of additional lesions by 5-ALA changed the operative course. There were no positive resection margins within the 5-ALA cohort, compared with 8 (2.3%) within the control group, this difference was not statistically significant. Whilst the primary outcome of lesion detection and resection margin is underwhelming, the frequency of post-operative complications is more significant. No patients experienced post-operative bile leak following FGS, compared with 19 (5.2%) within the control group ($p = 0.0548$). 5-ALA is excreted into bile, leakage is therefore detectable under fluorescence imaging. During 5-ALA guided resection, 3 bile duct leaks were detected intra-operatively and subsequently repaired. This suggests 5-ALA may reduce the incidence of post-operative bile duct leakage. The question not asked by this study is whether 5-ALA may have additional benefits over ICG as a fluorescent marker. The authors suggest 5-ALA may have a lower false positive rate than ICG, however the data is not provided in this study. The tissue penetration of 5-ALA fluorescence is far lower than when using ICG. This significantly hampers the effectiveness of 5-ALA when directly comparing with ICG.

Comparison with current gold standard intra-operative imaging

Intra-operative ultrasound sonography (IOUS) is the gold standard intra-operative imaging technique during liver resections. IOUS was first trialled in 1981 (26) and has been shown to improve detection, characterisation and localisation of solid liver tumours during liver resection (27,28), with up to 30%

increase in lesion detection compared with pre-operative imaging (29). It was thought that due to the improvements in imaging technology that IOUS may be rendered obsolete, however recent studies have shown that IOUS continues to be vital during liver resection (32,33). In a series of 86 consecutive patients undergoing liver resection for CRLM, pre-operative imaging identified 328 lesions (32). IOUS identified an additional 31 lesions in 17 patients. Overall, IOUS changed the intended procedure in 29 (29.9%) cases, in 13 of these a larger resection was performed due to additional lesion detection; in 11 it reduced the resection due to improved lesion characterisation. Jreaz et al. found IOUS changed the pre-operative management plan in 17% of liver resections (33) and Schmidt et al. (34) have shown IOUS to have a sensitivity and specificity of 98% and 95% respectively for the detection of CRLM. With highly effective intra-operative imaging currently utilised, the value of FGS to guide liver resection is questionable. IOUS has a number of significant advantages over FGS, the most significant being its greatly increased tissue penetration. As stated previously, due to the nature of fluorescence, lesions greater than 10 mm deep remain undetected, there is no such restriction with IOUS. IOUS also has the additional benefit of further lesion characterisation. However, two areas of shortcomings of IOUS are that it cannot detect lesions <3mm in size and there is a superficial blind area 1 cm under the liver surface (35).

Abo et al. aimed to further clarify the role of FGS in tumour detection and to compare its efficacy with intra-operative ultrasound sonography (IOUS) (36). The study comprised 117 patients due to undergo resection for Hepatobiliary tumours over a five year period at a single centre. Liver tumours included HCC, intrahepatic cholangiocarcinoma, CRLM, as well as several others. All patients underwent IOUS followed by assessment under fluorescence imaging and lesions were resected as appropriate. IOUS diagnosed 109 of 111 malignant tumours and 5 of 6 benign tumours. Fluorescence imaging diagnosed 85 of the 111 malignant tumours and 3 of 6 of the benign tumours. The sensitivity and specificity of IOUS was 98% and 83% respectively, significantly greater than FGS had a

sensitivity of specificity of 77% and 50% respectively. The negative predictive value of IOUS was far higher, 71%, compared with 10% with FGS. The data (38) shows IOUS to be superior to fluorescence imaging in all measures of diagnostic precision, yet FGS may play a complimentary role with IOUS. In 3 patients, additional deposits were identifiable only with FGS, it is not discussed whether this changed decision making during the operation or whether it resulted in further segmental resection. The two potential roles of fluorescence imaging that should be considered are inspection of the liver surface for lesions missed by IOUS and intra-operative examination of specimens to assess for clear resection margins. There is no data with regards to examination of resected specimens for a clear resection margin. Nor is there a discussion regarding the number of R0 or R1/R2 resections. There is also no data regarding survival or recurrence rates. This study contributes to the evidence that FGS should not replace IOUS during liver resection. Yet it does not fully explore its secondary outcomes. As such, conclusions with regards to the concomitant use of both IOUS and fluorescence imaging cannot be drawn.

Hybridisation of fluorescence guided surgery and intra-operative ultrasound sonography

Uchiyama et al. (37) first attempted to assess the effectiveness of concomitant use of contrast-enhanced IOUS (CE-IOUS) and fluorescence imaging. 32 patients who were due to undergo liver resection for CRLM were enrolled within this prospective study. All patients underwent CT and MRI, as well as intra-operative CE-IOUS and examination under fluorescence imaging. Their findings are summarised, with two further studies in table 1. Sensitivity (using pathology results as the gold standard) of CT/MRI was 88.5%, compared with 98.1% in CE-IOUS/FGS ($p = 0.05$). Positive predictive value (PPV) was comparable; CT/MRI – 95.8%, CE-IOUS/FGS – 96.3%. This small study demonstrates a small benefit for hybridisation. However, whilst two additional metastatic lesions were detected

under fluorescence, there were two additional false positives. CE-IIOUS was highly sensitive and specific for lesions without the addition of fluorescence. Combining techniques added a little to the sensitivity however lowered the positive predictive value. The potential benefit of analysis of on-table resection margins is not described, nor is data on R0 versus R1/R2 resections. This study does not provide data on post-operative outcomes, neither long nor short term. They also do not provide information regarding median operative time. Operative time is known to be a factor influencing outcomes post-operatively. This technique could potentially significantly lengthen operative time and thus negatively impact on outcomes.

(Insert table 1)

Peloso et al. (38) also hypothesised that IIOUS could be used synergistically with fluorescence imaging to aid complete resection. 25 patients with CRLM underwent intra-operative IIOUS and FGS. The results are summarised in table 1. IIOUS detected 15 further lesions compared with CT, however the difference was not statistically significant ($p=0.0708$). Yet, when IIOUS and fluorescence imaging were used concomitantly, lesion detection was significantly higher when compared with CT ($p=0.0029$). With tumours <3mm in size, the joint use of IIOUS and fluorescence imaging resulted in significantly greater tumour detection rates than IIOUS alone ($p=0.0328$). There were a total of 29 lesions <3mm in size. 8 of these were identified pre-operatively, a further 7 were identified using IIOUS and an additional 14 were identified using fluorescence imaging. A detailed account of the pathology reports is not provided but the authors do report one false positive lesion when using fluorescence imaging. The false positive rate is surprisingly low when compared with previous studies. The number of new lesions detected intra-operatively was dramatically higher than that described by Uchiyama et al. This could in part be explained by the difference in pre-operative imaging modality. Uchiyama et al. performed pre-operative CT and MRI; Peloso et al. used CT alone. Unlike Uchimaya et al., IIOUS was not performed with the aid of contrast. As such, a number of

lesions detected by fluorescence imaging alone, may have been detected had CE-IOUS been used. Long term post-operative outcomes, including survival rates are not provided, however in all cases bar one, R0 resection was achieved.

Van der Vorst et al. (22) undertook a similar prospective study investigating the potential benefits of NIR fluorescence to guide liver resections in 40 patients from 2010 to 2012. Their results are summarised in table 1. Further resections were required in all five patients when additional lesions were detected by fluorescence imaging. One malignant lesion (confirmed by pathology), measuring 9mm in diameter, was labelled a complicated cyst by both CT and IOUS and only identified as malignant under fluorescence imaging. Unsurprisingly, 26 lesions located >8mm from the surface were missed by NIR fluorescence.

These three studies provide evidence that hybridisation of the two techniques increases tumour detection rate. By selecting only resections for CRLM a homogenous population is created, this allows greater ease of data interpretation and identifies a cohort where this technique may be effective. Yet their findings are not transferrable to resections for HCC. The differences in methodology between the studies are displayed in table 2. This may account for a number of the differences including, false positive rate, lesions detected only by NIR fluorescence and difference in pattern of fluorescence.

(Insert table 2)

Translating preliminary trials into clinical results

Before new techniques are incorporated into standard practice, a number of factors require consideration. First and foremost, clear evidence that it is better than, or comparable to current technology. The above data shows that IOUS rightly remains the gold-standard for intra-operative assessment of tumour deposition within the liver. The addition of fluorescence imaging may result in an increase in the detection of small, superficial metastatic deposits. Of particular interest, not commented on in the majority of trials is the intra-operative examination of resection margins under fluorescence. Clinical outcomes are also not addressed in the majority of trials. Inoue et al. (24) utilise a historical control group as a comparator and investigate post-operative outcomes between these cohorts. All other studies lack comparators and focus only on number of lesions detected. A randomised control trial to investigate the efficacy of ICG fluorescence with IOUS compared with IOUS alone is justified. Patients should be followed up for R0 resection rates, median survival time and recurrence rates. This would provide a true evaluation of patient outcomes using this technology.

A factor, noted throughout most studies is the presence of false positives. A number of benign lesions cause biliary stasis; therefore due the nature of FGS using ICG, the technique will always be subject to a number of inappropriate resections. 5-ALA may prove to have a higher specificity, yet the future lies in molecular targeting. Fluorescently labelled agents can be directed to adhere to certain cell surface antigens, or peptides displayed by tumour cells. Numerous pre-clinical trials have displayed the efficacy of targeting tumour specific antigens with fluorescent markers (39,40). Increasing the specificity of fluorescent markers will reduce the number of false positives identified during FGS, thus reducing the number of unnecessary resections and preserving normal liver parenchyma.

Fluorescence and the wider picture

Clinical trials with live fluorescence, particularly in Hepatobiliary surgery, are clustered around certain academic institutions. Centres in Osaka, Nagasaki and Tokyo feature prominently in the literature. A significant proportion of the research has been performed by teams attached to the University of Tokyo, aided by numerous government grants (19,20,41,42). This is likely in part due to the health burden that HCC has in Japan compared with the rest of the world, driving research into liver resection. That the Photo Dynamic Eye imaging system is manufactured by Hammamatsu Phototonics, a technology firm based in Japan, may also play a role. The capital investments into this technology are not insignificant (46,000 US dollars (43)) and though no conflict of interest is declared, research incentives may have driven studies in this area. The team at Leiden University also provide significant contributions to the wider field of fluorescence in surgery (44). It is noticeable that some of their members are associated with the FLARE foundation, owners of the mini-FLARE technology. The initial cost of fluorescence devices may provide a disincentive to other institutions who would otherwise further research in this area.

The cost of the technology should be considered not only in terms of guiding research, but also guiding clinical implementation. In health care systems such as the NHS a cost benefit analysis is performed before new technologies are introduced. Duggal et al. (45) performed an outcome analysis of intra-operative ICG angiography for postmastectomy breast reconstruction. Outcomes of 184 patients that underwent the above procedure were compared to 184 historical controls, where ICG angiography was not performed. Rates of mastectomy skin necrosis and re-operation were significantly lower within the ICG angiography group; this resulted in a saving of 113,014 US dollars over the two years that this study was conducted. As yet, no cost benefit analysis for FGS in

Hepatobiliary surgery has been performed and with the advent of molecular targeting, this will almost certainly rise. When research is directed at outcomes following NIR fluorescence guided resections, the costs and potential savings will become more evident. This will increase uptake in systems, such as the NHS, where the opportunity cost must always be considered.

Conclusion

During hepatic resection, identification and removal of all malignant tissue is vital for prolonged patient survival. Fluorescence, due to its poor tissue penetration cannot detect deep liver lesions. As such, it has no role as the sole intra-operative imaging modality during liver resection. However, there is some evidence to suggest that hybridisation of IOUS and fluorescence imaging may increase tumour detection rate compared with IOUS alone. As yet, there is a paucity of evidence that shows this translates into improved patient outcomes. There is potential for FGS to reduce recurrence rates, by allowing the surgeon to assess the margin of resection intra-operatively and to detect further micro-metastatic deposits. To date, studies have not focused on R0 resection rates, recurrence rates and median survival time. Without robust patient outcome data, centres will be reluctant to invest in this relatively untested technology which requires significant start-up costs.

The authors declare no conflict of interest.

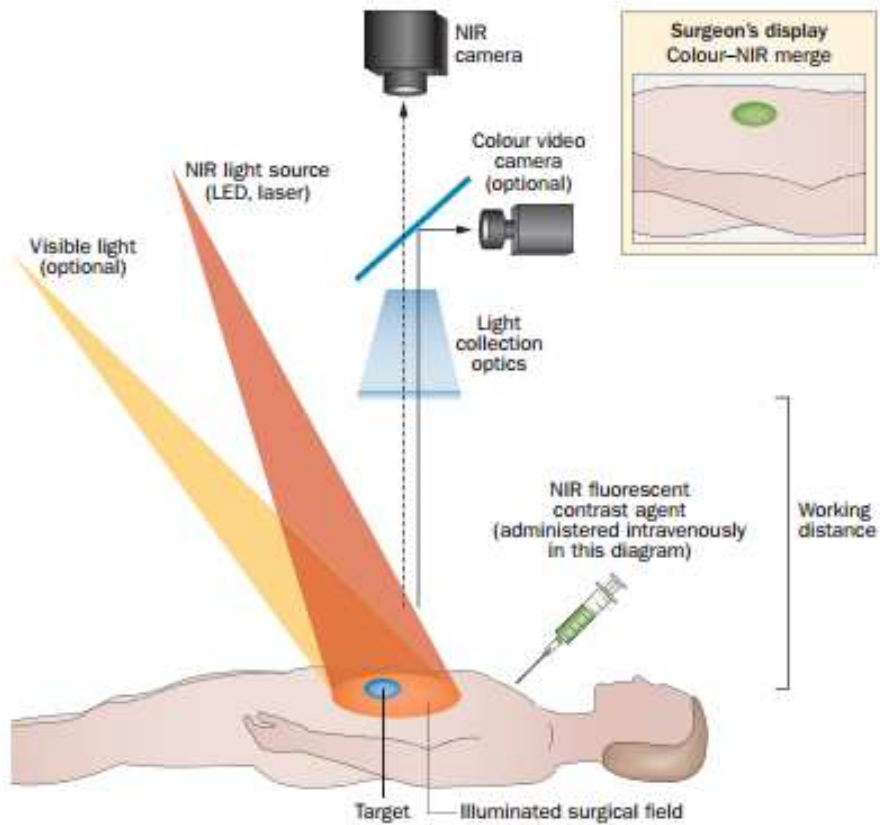


Figure 1 (2): The mechanism of NIR fluorescence imaging. The agent is visualized using an NIR fluorescence imaging system. All systems must have adequate NIR excitation light, collection optics and a camera sensitive to NIR fluorescence emission light. The image displayed is a merging of the surgical field, displayed by white light, and the NIR fluorescence images.

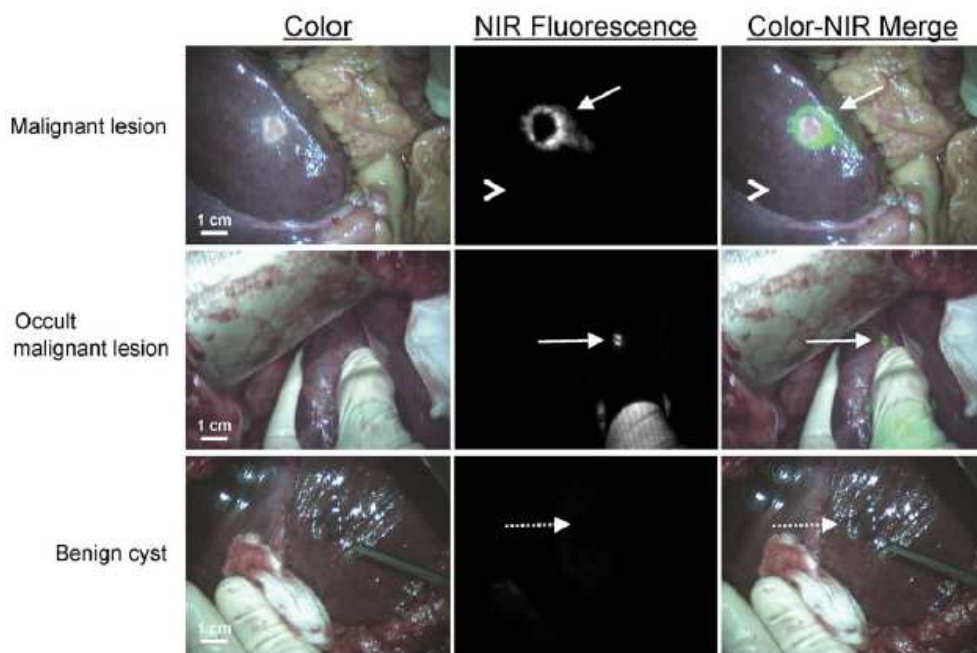


Figure 2: NIR fluorescence of colorectal cancer liver metastases. (22)

No. Additional lesions detected intraoperatively per imaging modality

Study	No. Lesions detected pre-operatively	IOUS	FGS
Uchiyama et al. (39)	46	3	2
Peloso et al. (40)	45	10	23
Van der Vorst et al. (2013)	73	19	5

Table 1: Lesion detection of different imaging modalities between studies

	Pre-operative imaging	Ultrasound technique	NIR imaging device
Uchiyama et al. (2010)	CT + MRI	CE-IOUS	Photo Dynamic Eye
Peloso et al. (2013)	CT	IOUS	Photo Dynamic Eye
Van der Vorst et al. (2013)	CT	IOUS	mini-FLARE

Table 2: Hetrogeneity of studies

Bibliography

1. De Boer E, Harlaar NJ, Taruttis A, Nagengast WB, Rosenthal EL, Ntziachristos V, et al. Optical innovations in surgery. *Br J Surg*. 2015;102(2):56–72.
2. Vahrmeijer, Alexander L. Merlijn Hutteman, Joost R. van der Vorst CJH van de V, Frangioni and J V. Image-guided cancer surgery using near-infrared fluorescence. *Nat Rev Clin Oncol*. 2013;18(9):1199–216.
3. Parkin DM, Bray F, Ferlay J, Pisani P. Global cancer statistics, 2002. *CA Cancer J Clin*. 2005;55(2):74–108.
4. Gomaa A-I. Hepatocellular carcinoma: Epidemiology, risk factors and pathogenesis. *World J Gastroenterol*. 2008;14(27):4300.
5. Forner A, Llovet JM, Bruix J. Hepatocellular carcinoma. *Lancet*. 2012;379(9822)
6. Benckert C, Jonas S, Thelen A, Spinelli A, Schumacher G, Heise M, et al. Liver transplantation for hepatocellular carcinoma in cirrhosis: Prognostic parameters. *Transplant Proc*. 2005;37(4):1693–4.
7. Zheng J, Kuk D, Gönen M, Balachandran VP, Kingham TP, Allen PJ, et al. Actual 10-Year Survivors After Resection of Hepatocellular Carcinoma. *Ann Surg Oncol*. 2016;
8. Shi M, Guo R-P, Lin X-J, Zhang Y-Q, Chen M-S, Zhang C-Q, et al. Partial hepatectomy with wide versus narrow resection margin for solitary hepatocellular carcinoma: a prospective randomized trial. *Ann Surg*. 2007;245(1):36–43.
9. Lang H, Sotiropoulos GC, Brokalaki EI, Schmitz KJ, Bertona C, Meyer G, et al. Survival and Recurrence Rates after Resection for Hepatocellular Carcinoma in Noncirrhotic Livers. *J Am Coll Surg*. 2007;205(1):27–36.
10. Cancer Research UK. Cancer Statistics 2013 [Internet]. 2013 [cited 2016 Aug 20]. Available from:

<http://www.cancerresearchuk.org/health-professional/cancer-statistics/statistics-by-cancer-type/bowel-cancer/incidence>

11. Jemal A, Siegel R, Ward E, Hao Y, Xu J, Thun MJ. Cancer Statistics. *CA Cancer J Clin*. 2009;59(4):225–49.
12. Morris EJA, Forman D, Thomas JD, Quirke P, Taylor EF, Fairley L, et al. Surgical management and outcomes of colorectal cancer liver metastases. *Br J Surg*. 2010;97(7):1110–8.
13. Garden OJ, Rees M, Poston GJ, Mirza D, Saunders M, Ledermann J, et al. Guidelines for resection of colorectal cancer liver metastases. *Gut*. 2006;55 Suppl 3:iii1-i8.
14. Evangelos P Misiakos, Nikolaos P Karidis GK. Current treatment for colorectal liver metastases. *World J Gastroenterol*. 2011;17(36):4067–75.
15. Pawlik TM, Scoggins CR, Zorzi D, Abdalla EK, Andres A, Eng C, et al. Effect of surgical margin status on survival and site of recurrence after hepatic resection for colorectal metastases. *Ann Surg*. 2005;241(5):715–22,
16. Taggart DP, Choudhary B, Anastasiadis K, Abu-Omar Y, Balacumaraswami L PD. Preliminary experience with a novel intraoperative fluorescence imaging technique to evaluate the patency of bypass grafts in total arterial revascularization. *Ann Thorac Surg*. 2003;75:870–3.
17. Kitai T, Inomoto T, Miwa M, Shikayama T. Fluorescence navigation with indocyanine green for detecting sentinel lymph nodes in breast cancer. *Breast Cancer*. 2005;12(3):211–5.
18. Desai ND, Miwa S, Kodama D, Cohen G, Christakis GT, Goldman BS, et al. Improving the quality of coronary bypass surgery with intraoperative angiography: Validation of a new technique. *J Am Coll Cardiol*. 2005;46(8):1521–5.
19. Ishizawa T, Fukushima N, Shibahara J, Masuda K, Tamura S, Aoki T, et al. Real-time identification of liver cancers by using indocyanine green fluorescent imaging. *Cancer*. 2009;115(11):2491–504.
20. Ishizawa T, Tamura S, Masuda K, Aoki T, Hasegawa K, Imamura H, et al. Intraoperative Fluorescent Cholangiography Using Indocyanine Green: A Biliary Road Map for Safe Surgery. *J Am Coll Surg*.

- 2009;208(1):1–4.
21. Mondal SB, Gao S, Zhu N, Liang R, Gruev V, Achilefu S. Real-time fluorescence image-guided oncologic surgery. *Adv Cancer Res.* 2015;124:171–211.
 22. Van Der Vorst JR, Schaafsma BE, Hutteman M, Verbeek FPR, Liefers GJ, Hartgrink HH, et al. Near-infrared fluorescence-guided resection of colorectal liver metastases. *Cancer.* 2013;119(18):3411–8.
 23. Gotoh K, Yamada T, Ishikawa O, Takahashi H, Eguchi H, Yano M, et al. A novel image-guided surgery of hepatocellular carcinoma by indocyanine green fluorescence imaging navigation. *J Surg Oncol.* 2009;100(1):75–9.
 24. Kudo H, Ishizawa T, Tani K, Harada N, Ichida A, Shimizu A, et al. Visualization of subcapsular hepatic malignancy by indocyanine-green fluorescence imaging during laparoscopic hepatectomy. *Surg Endosc Other Interv Tech.* 2014;28(8):2504–8.
 25. Inoue Y, Tanaka R, Komeda K, Hirokawa F, Hayashi M, Uchiyama K. Fluorescence detection of malignant liver tumors using 5-aminolevulinic acid-mediated photodynamic diagnosis: Principles, technique, and clinical experience. *World J Surg.* 2014;38(7):1786–94.
 26. Makuuchi M, Hasegawa H, Yamaoka Y. Intraoperative ultrasonic evaluation for hepatectomy. *Jpn J Clin Oncol.* 1981;11:367–90.
 27. Torzilli G, Olivari N, Moroni E, Del Fabbro D, Gambetti A, Leoni P, et al. Contrast-enhanced intraoperative ultrasonography in surgery for hepatocellular carcinoma in cirrhosis. *Liver Transpl.* 2004;10(2 Suppl 1):S34-8.
 28. Takigawa Y, Sugawara Y, Yamamoto J, Shimada K, Yamasaki S, Kosuge T, et al. New lesions detected by intraoperative ultrasound during liver resection for hepatocellular carcinoma. *Ultrasound Med Biol.* 2001;27(2):151–6.
 29. Clarke MP, Kane RA, Steele G Jr, Hamilton ES, Ravikumar TS, Onik G CM. Prospective comparison of preoperative imaging and intraoperative ultrasonography in the detection of liver tumors. *Surgery.* 1989;106(5):849–55.

30. Sietses C, Meijerink MR, Meijer S, van den Tol MP. The impact of intraoperative ultrasonography on the surgical treatment of patients with colorectal liver metastases. *Surg Endosc.* 2010;24(8):1917–22.
31. D’Hondt M, Vandembroucke-Menu F, Préville-Ratelle S, Turcotte S, Chagnon M, Plasse M, et al. Is intraoperative ultrasound still useful for the detection of a hepatic tumour in the era of modern preoperative imaging? *Hpb.* 2011;13(9):665–9.
32. Schulz A, Dormagen JB, Drolsum A, Bjørnbeth BA, Labori KJ, Kløw N-E. Impact of contrast-enhanced intraoperative ultrasound on operation strategy in case of colorectal liver metastasis. *Acta radiol* 2012;53(10):1081–7.
33. Jreaz R, HartMD R, Jayaraman S. Intraoperative ultrasonography and surgical strategy in hepatic resection: What difference does it make? *Can J Surg.* 2015;58(5):318–22.
34. Schmidt J, Strotzer M, Fraunhofer S, Boedeker H, Zirngibl H. Intraoperative ultrasonography versus helical computed tomography and computed tomography with arteriportography in diagnosing colorectal liver metastases: Lesion-by-lesion analysis. *World J Surg.* 2000;24(1):43–8.
35. Numata K, Morimoto M, Ogura T, Sugimori K, Takebayashi S, Okada M, et al. Ablation Therapy Guided by with Sonazoid for Hepatocellular. *J Ultrasound Med.* 2008;27:395–406.
36. Abo T, Nanashima A, Tobinaga S, Hidaka S, Taura N, Takagi K, et al. Usefulness of intraoperative diagnosis of hepatic tumors located at the liver surface and hepatic segmental visualization using indocyanine green-photodynamic eye imaging. *Eur J Surg Oncol.* 2015;41(2):257–64.
37. Uchiyama K, Ueno M, Ozawa S, Kiriya S, Shigekawa Y, Yamaue H. Combined use of contrast-enhanced intraoperative ultrasonography and a fluorescence navigation system for identifying hepatic metastases. *World J Surg.* 2010;34(12):2953–9.
38. Peloso A, Franchi E, Canepa MC, Barbieri L, Briani L, Ferrario J, et al. Combined use of intraoperative ultrasound and indocyanine green fluorescence imaging to detect liver metastases from colorectal cancer. *Hpb* 2013;15(12):928–34.
39. Maawy AA, Hiroshima Y, Zhang Y, Luiken GA, Hoffman RM, Bouvet M. Polyethylene Glycol (PEG) Linked

- to Near Infrared (NIR) dyes conjugated to chimeric Anti-Carcinoembryonic Antigen (CEA) antibody enhances imaging of liver metastases in a nude-mouse model of human colon cancer. *PLoS One*. 2014;9(5).
40. Metildi CA, Kaushal S, Luiken GA, Talamini MA, Hoffman RM, Bouvet M. Fluorescently labeled chimeric anti-CEA antibody improves detection and resection of human colon cancer in a patient-derived orthotopic xenograft (PDOX) nude mouse model. *J Surg Oncol*. 2014;109(5):451–8.
41. Kawaguchi Y, Ishizawa T, Masuda K, Sato S, Kaneko J, Aoki T, et al. Hepatobiliary surgery guided by a novel fluorescent imaging technique for visualizing hepatic arteries, bile ducts, and liver cancers on color images. *J Am Coll Surg*. 2011;212(6):e33–9.
42. Ishizawa T, Masuda K, Urano Y, Kawaguchi Y, Satou S, Kaneko J, et al. Mechanistic background and clinical applications of indocyanine green fluorescence imaging of hepatocellular carcinoma. *Ann Surg Oncol*. 2014;21(2):440–8.
43. N. Tagaya, M. Tsumuraya, A. Nakagawa, Y. Iwasaki, H. Kato KK. Indocyanine green (ICG) fluorescence imaging versus radioactive colloid for sentinel lymph node identification in patients with breast cancer. In: ASCO Annual Meeting. *Journal of Clinical Oncology*; 2010. p. 15.
44. Vorst JR, Schaafsma BE, Verbeek FPR, Hutteman M, Mieog JSD, Lowik CWGM, et al. Randomized comparison of near-infrared fluorescence imaging using indocyanine green and 99(m) technetium with or without patent blue for the sentinel lymph node procedure in breast cancer patients. *Ann Surg Oncol*. 2012;4104–11.
45. Duggal CS, Madni T, Losken A. An Outcome Analysis of Intraoperative Angiography for Postmastectomy Breast Reconstruction. *Aesthetic Surg J*. 2014;34(1):61–5.