

## A Guide to Prepectoral Breast Reconstruction:

Vidya, Raghavan; Iqbal, Fahad Mujtaba

DOI:

[10.1016/j.clbc.2016.11.009](https://doi.org/10.1016/j.clbc.2016.11.009)

License:

Creative Commons: Attribution-NonCommercial-NoDerivs (CC BY-NC-ND)

*Document Version*

Peer reviewed version

*Citation for published version (Harvard):*

Vidya, R & Iqbal, FM 2017, 'A Guide to Prepectoral Breast Reconstruction: A New Dimension to Implant-based Breast Reconstruction', *Clinical Breast Cancer*, vol. 17, no. 4, pp. 266-271.  
<https://doi.org/10.1016/j.clbc.2016.11.009>

[Link to publication on Research at Birmingham portal](#)

### General rights

Unless a licence is specified above, all rights (including copyright and moral rights) in this document are retained by the authors and/or the copyright holders. The express permission of the copyright holder must be obtained for any use of this material other than for purposes permitted by law.

- Users may freely distribute the URL that is used to identify this publication.
- Users may download and/or print one copy of the publication from the University of Birmingham research portal for the purpose of private study or non-commercial research.
- User may use extracts from the document in line with the concept of 'fair dealing' under the Copyright, Designs and Patents Act 1988 (?)
- Users may not further distribute the material nor use it for the purposes of commercial gain.

Where a licence is displayed above, please note the terms and conditions of the licence govern your use of this document.

When citing, please reference the published version.

### Take down policy

While the University of Birmingham exercises care and attention in making items available there are rare occasions when an item has been uploaded in error or has been deemed to be commercially or otherwise sensitive.

If you believe that this is the case for this document, please contact [UBIRA@lists.bham.ac.uk](mailto:UBIRA@lists.bham.ac.uk) providing details and we will remove access to the work immediately and investigate.

# Accepted Manuscript

A guide to pre-pectoral breast reconstruction: a new dimension to implant based breast reconstruction

R. Vidya, F.M. Iqbal



PII: S1526-8209(16)30350-0

DOI: [10.1016/j.clbc.2016.11.009](https://doi.org/10.1016/j.clbc.2016.11.009)

Reference: CLBC 562

To appear in: *Clinical Breast Cancer*

Received Date: 9 October 2016

Accepted Date: 8 November 2016

Please cite this article as: Vidya R, Iqbal F, A guide to pre-pectoral breast reconstruction: a new dimension to implant based breast reconstruction, *Clinical Breast Cancer* (2017), doi: 10.1016/j.clbc.2016.11.009.

This is a PDF file of an unedited manuscript that has been accepted for publication. As a service to our customers we are providing this early version of the manuscript. The manuscript will undergo copyediting, typesetting, and review of the resulting proof before it is published in its final form. Please note that during the production process errors may be discovered which could affect the content, and all legal disclaimers that apply to the journal pertain.

A guide to pre-pectoral breast reconstruction: a new dimension to implant based breast reconstruction

Vidya R<sup>1</sup>, Iqbal FM<sup>2</sup>

1. Miss Raghavan Vidya (corresponding author), Honorary senior Lecturer at Birmingham University & Consultant Oncoplastic Breast Surgeon, New Cross Hospital, Wolverhampton, Wednesfield Road, Wolverhampton WV10 0QP, UK  
raghavan.vidya@nhs.net  
Tel: 01902 695969  
Fax: 01902 695754
2. Fahad Mujtaba Iqbal, Final Year Medical Student, Keele University, David Weatherall Building, Keele University, Stoke-on-Trent, Staffordshire ST5 5BG, UK  
fahad.iqbal@kclalumni.net

**CONFLICT OF INTEREST:**

The authors report no conflicts of interest.

**ABSTRACT**

Acellular dermal matrix (ADM) has revolutionised implant based breast reconstruction. Breast reconstruction has evolved from the traditional sub-muscular to the new pre-pectoral implant based (also known as muscle-sparing) reconstruction. The new technique is emerging as a highly popular surgery due to its more minimal approach. We conducted a narrative review to guide pre-pectoral breast reconstruction highlighting the technique, need for appropriate patient selection, and areas for further research. We show that pre-pectoral breast reconstruction is safe, feasible, and has excellent short term outcomes (cosmesis and patient satisfaction). Its main advantages are that it avoids animation deformity, prevents shoulder dysfunction, and has a lower incidence of capsular contracture. Selection for the pre-pectoral technique is dependent on patient factors (e.g. BMI, lifestyle), breast size, flap assessment, and adjuvant radiotherapy. Whilst the initial short-term results are promising, long-term outcomes are yet to be reported and is an area that requires further research.

**Keywords:** acellular dermis; Breast; Breast Implants; mastectomy; pectoralis muscles.

**BACKGROUND: EVOLUTION OF PRE-PECTORAL BREAST RECONSTRUCTION**

Breast cancer is the most common malignancy in women in the United Kingdom (UK), with four in ten women undergoing a mastectomy as their primary therapeutic procedure.<sup>1</sup> Implant-based breast reconstructions account for 40-60% of all breast reconstructions performed in the UK and approximately 75% in the United States (US).<sup>2-4</sup>

A variety of options are available for breast reconstruction: autologous, prosthetic (implant-based), or a hybrid of the two. Implant-based reconstruction is the most common pathway with approximately 70% of all breast reconstructions being prosthetic based, often as a single stage process in the UK & Europe or as a two-staged process in the US: the first stage involving a tissue expander and a second stage where the expander is exchanged for a prosthetic breast implant.<sup>5-7</sup>

In 1882, the Halstead radical mastectomy was pioneered; since then, a more conservative approach is being favoured in which the skin and/or nipple are spared.<sup>8,9</sup> The native breast envelope and inframammary fold is favoured, allowing reconstruction at the time of mastectomy with a highly favourable cosmesis.<sup>10,11</sup> Whilst some believed a more conservative approach compromised oncological safety, further studies have shown this not to be the case.<sup>11,12</sup>

Indeed, over time, oncologic therapies as well as the reconstructive tools and principles have evolved: tissue expanders, prosthetic implant devices, implements for flap perfusion assessment, bioprotheses, and the combination of reconstruction techniques with fat grafting have all been refined, allowing for improved surgical outcomes.<sup>13</sup>

Over the last decade, the introduction of meshes has revolutionised breast reconstruction. A wide variety of biological and synthetic meshes are available;<sup>14-16</sup> a biological mesh, referred to as an acellular dermal matrix (ADM), is a scaffold of dermis from either cadaveric human (Alloderm®, Allomax®, FlexHD®, DermaCell®), porcine (Strattice®, Permacol™, Braxon®), bovine (SurgiMend®), or bovine pericardium (Veritas®) tissue. They are made devoid of their cell content and sterilised; as such, are considered to be non-inflammatory. The biological scaffold allows rapid host revascularisation and cell repopulation arguably facilitating a good surgical outcome.

Most studies have reviewed biological matrices in implant-based reconstruction, acting as an extension of the pectoralis major.<sup>17,18</sup> It is attached to the inferior-lateral pole of the muscle, the mesh expands the space available for the insertion of an implant, filling the void left between the muscle and fascia, creating a natural infra mammary fold (Figure 1a).<sup>19</sup> This technique provides additional cover and support inferiorly, enabling faster tissue expansion, larger implant volumes, and improvement of lower pole projection.<sup>20</sup>

Synthetic matrices are also being used in breast reconstruction as an alternative to ADMs.<sup>19</sup> These are made from plastic-like material: absorbable (Vicryl), long-term

absorbable (TIGR®), or non-absorbable (titanium-coated polypropylene mesh (TiLOOP®).

In the traditional sub-muscular breast reconstruction, the technical employment is based on the principle of implant lower lateral pole coverage in a hammock-like fashion after pectoralis major detachment.<sup>21</sup> However, its disadvantaged by the potential impairment to shoulder dysfunction and animation deformity due to its detachment.<sup>22</sup> As such, a more novel pre-pectoral approach is being employed more often to avoid such a complication.

Pre-pectoral breast reconstruction involves creating a new breast (Figure 1b), constructed ex-vivo by covering the implant with the mesh and subsequently attaching it over the chest wall, thereby keeping the pectoralis major and serratus anterior undisturbed. It ensures that the breast remains in its anatomical plane, minimising morbidity, achieving the desired cosmesis, and maintaining shoulder functionality.

### **PATIENT SELECTION**

Appropriate patient selection is vital for a good outcome of pre-pectoral breast reconstruction particularly during the initial learning curve. The senior author of this paper in her series of pre-pectoral breast reconstruction<sup>23</sup> selected patients in accordance to the Joint guidelines by the Association of Breast Surgeons (ABS) and the British Association of Plastic, Reconstruction and Aesthetic surgeons (BAPRAS).<sup>24</sup> Patients with minimal comorbidity, an active lifestyle, small to medium sized breasts, good intra-operative tissue perfusion would be good candidates for this surgery (Figure 2). Important selection criteria include:

- Pre-operative selection is important: patients with a low BMI ( $< 35\text{kg/m}^2$ ), non- or ex- smokers, grade 1 or 2 ptosis, or anticipated breast volume of resection less than 500 grams would be more ideal to minimise complications and achieve the desired outcome.
- Patient lifestyle should be taken into consideration, particularly athletes who require extensive pectoralis major use and require preserved shoulder functionality.
- Tumour histopathology would dictate the requirement for adjuvant therapy. There is currently limited data on toleration of adjuvant radiotherapy and its impact on meshes; it would be ideal to avoid the pre-pectoral technique in patients who require immediate post-operative radiotherapy. However in our experience the tolerability of post-operative radiotherapy was good, although our sample size was very small.
- Intra-operative assessment of tissue perfusion is crucial, good perfusion of the mastectomy flaps is required for mesh integration. .

## INDICATIONS

The main indications for this technique are tabulated in Table 1, pre-pectoral based implant reconstruction following immediate mastectomy is likely to be the most common indication. It can also be used to treat undesirable outcomes following reconstructions including animation deformity, capsular contracture and breast deformity.

## SURGICAL TECHNIQUE

Pre-operatively, the patient should undergo normal counselling (diagnosis and potential treatments and the associated risks & benefits). During the operation, the type of scar would be influenced by the tumour location, surgeon's preference and breast morphology. The common incisions for nipple sparing or skin sparing mastectomy include inframammary, vertical or a lateral approach; non-nipple sparing includes the classic elliptical approach. A good quality mastectomy flap is important for the success of the surgery. In some centres, a close working relationship between the mastectomy and the reconstructive surgeon is successfully used to achieve this.

Assessment of the vascularity and perfusion of the mastectomy flap can be done with clinical judgement or certain devices (e.g SPY system) . If the area is small it can be excised, otherwise consideration to alternatives needs to be given.

The type of implants used can be fixed volume silicone or saline, anatomical or round depending on the need to match symmetry. If pressure on the skin flaps is possible then an adjustable flat expander implant can be used. The implant is placed under-filled, ensuring that there is no increased pressure to the flaps and expanded at a later date once viability of the flaps is confirmed.

Drains, closure of the wound, and dressings can be placed according to local surgical practice. The senior author used absorbable 2-0 vicryl for subcutaneous and 3-0 monocryl for subcuticular skin closure in her series.<sup>23</sup>

## TYPES OF MESHES: PRE-PECTORAL BREAST RECONSTRUCTION

Biological and non-biological meshes have been tabulated in Table 2. It is vital that the biological meshes have intimate contact with the vascularised tissue to promote remodelling of the collagen membrane and integrate into the tissues.<sup>25-27</sup>

The only ADM mesh that is pre-shaped is Braxon® (Decomed S.r.l., Venezia, Italy). The other meshes are available as flat sheets, which are wrapped around the implant. These flat meshes are commonly used for sub-muscular reconstruction but are now being used in pre-pectoral breast reconstruction.

### **COMPLETE WRAP WITH A PRE-SHAPED MESH**

Braxon® is a pre-shaped, 0.6 mm thick, porcine, non-cross-linked ADM which requires hydration in saline; it is designed to wrap around implants ranging up to 500 cc. The selected implant is placed and wrapped within the matrix with the edges suturing together with either continuous or interrupted absorbable sutures (2-0 Vicryl) to form a tight pocket (Figure 3). This is subsequently placed onto the pectoralis without its detachment and anchored with apical, medial and lateral absorbable sutures directly on to the chest wall, allowing for neovascularisation to occur and incorporating the biomaterial into the surrounding tissues for a stable, permanent cover.

### **COMPLETE WRAP WITH FLAT SHEET MESH**

The wrap-around of the mesh is carried using either a single large piece (if available) or two pieces of mesh anchored using sutures (Figure 4). The mesh forms a complete 360 degree wrap around the implant and the mesh edges are sutured to form a pocket using an absorbable suture (e.g. 2-0 Vicryl or PDS). The mesh implant pocket is secured to the chest wall and, if needed, to the inframammary fold. This enables an adequate anchorage and control of the breast shape and ptosis, avoiding implant displacement.

### **ANTERIOR WRAP WITH FLAT SHEET MESH**

An alternative option would be to undergo an anterior wrap of the mesh, covering the implant with subsequent fixation to the chest wall. However, the literature reporting outcomes for this technique is very limited. It is also associated with implant displacement and implant herniation through the mesh due to the lack of posterior cover, and an inability to control the nipple position. It may also be associated with an increased risk of capsular contracture as a complete wrap of ADM has shown to treat capsular contracture and lessen the chance of its occurrence.<sup>28</sup>

### **EXTENSION OF THE TECHNIQUE**

The technique can be extended to patients with large, ptotic breasts (preferably once crossing the learning curve) with or without incorporating the dermal flap. The dermal flap provides additional soft tissue coverage and can enhance the volume of the reconstructed breast. The dermal flap along with the mesh forms a pocket for the implant, which is placed pre-pectorally. Caputo et al demonstrated this technique in 27 patients (33 breasts) and observed no implant loss with a low number of skin necroses.<sup>29</sup>



## **COST**

The cost of the meshes varies across countries and in Europe. On average, biological ADM meshes cost:

- 8x16cm piece (128 cm<sup>2</sup>): £1,600 - £1,800
- 10x18cm piece (180 cm<sup>2</sup>): £2,200 - £2,500
- the pre-shaped Braxon<sup>®</sup> mesh 30x20cm (600 cm<sup>2</sup>): £2,100
- Biological allograft meshes in the US appropriately cost: \$3000

Synthetic meshes are cheaper with 20x16cm at approximately €500 (~£400) but usually two meshes are required to form a complete wrap.

## **MESH INTEGRATION**

The biological mesh gets integrated through collagen remodelling and this ultimately integrates with the host tissues and get vascularised.<sup>26</sup> Biological grafts have collagen matrix, which aids in remodelling and new collagen deposition.<sup>30</sup> The characteristics of the material are dictated by the origin of the tissue derived. The chemical processing would influence its inert nature and the host response. The nature of biological meshes integration is believed to generate minimal foreign body reaction.

The synthetic meshes create a scaffold and promote fibrous tissue growth. The integration is influenced by the porosity, elasticity and the type of material. Our knowledge, extrapolated from hernia surgery, revealed that knitted meshes are more porous while woven ones are stronger. The synthetic meshes integrate with a fibroblastic reaction; the microscopic appearance of the titanium-coated synthetic mesh integration within a capsule (titanium-coated polypropylene mesh) alongside a mild chronic inflammatory response; all of which are completely integrated within fibroblastic tissue.<sup>29</sup>

## **WHICH MESH TO CHOOSE?**

The choice is mesh will largely depend on the surgeon's choice, its availability, and cost. The latter being a major factor in an era of financial constraint. However, due to the heterogeneous nature of the products, direct comparisons are difficult. Consequently, a good understanding of the products is essential to inform choice in clinical practice.

One should also consider that biological meshes integrate through collagen remodelling and this property of neo-tissue formation results in effective implant cover; indeed, this may offset the higher cost when compared to synthetic meshes.

## DISCUSSION

The use of a whole muscular pocket for prosthesis coverage to prevent wound dehiscence and implant exposure has been the preferred choice until recently.<sup>30</sup> However, the field of implant-based breast reconstruction has been radically changed since the introduction of meshes, resulting in adoption of new techniques.

One stage mesh based sub-muscular breast reconstruction offers a major advantage with immediate reconstruction. However the problems associated with shoulder dysfunction, postoperative pain, and animation deformity has led to the emergence of the novel pre-pectoral (muscle sparing) technique.

The effectiveness of muscle-sparing breast reconstruction technique using a complete ADM implant coverage has been demonstrated in a large series by the senior author in her series.<sup>23</sup> While other authors have shown its effectiveness using either partial ADM breast implant cover or complete coverage using synthetic meshes<sup>20,25</sup>. This technique preserved the natural anatomy, provided complete cover and avoided direct implant contact with the mastectomy flaps.

In 2015, a non-randomised prospective trial compared the long-term outcomes for retropectoral and pre-pectoral breast reconstructions (n=63) for a median follow-up of 26 (range: 16-42) months and 25 (16-40) months, respectively.<sup>32</sup> They reported similar results with no differences in terms of short- or long- term surgical complications or sexual well-being but did report a greater satisfaction with outcome in the pre-pectoral group (p=0.03) (again, with BREAST-Q).<sup>32</sup> Indeed, the small sample size and non-randomisation nature of the study means that the results should be interpreted cautiously; nevertheless, it is one of the few studies to compare the two techniques.

The pre-pectoral technique using the Braxon<sup>®</sup> ADM was performed by the senior author in her series.<sup>23</sup> It was associated with low rate of complications which could be due to appropriate patient selection and surpassing the learning curve associated with meshes. The advantage of using the pre-shaped ADM matrix included adoption of a standard technique with a short learning curve and a favourable outcome. Perhaps this is because pre-pectoral placement of the implant simulates the natural position of the removed breast tissue, leading to a more natural feel.

In 2015, a non-randomised prospective trial compared the long-term outcomes for retropectoral and pre-pectoral breast reconstructions (n=63) for a median follow-up of 26 (range: 16-42) months and 25 (16-40) months, respectively.<sup>32</sup> They reported similar results with no differences in terms of short- or long- term surgical complications or sexual well-being but did report a greater satisfaction with outcome in the pre-pectoral group (p=0.03) (again, with BREAST-Q).<sup>32</sup> Indeed, the small sample size and non-randomisation nature of the study means that the results should be interpreted cautiously; nevertheless, it is one of the few studies to compare the two techniques.

The incidence of capsular contracture reported varies between 2.8 to 15.9 % with an increase in incidence following adjuvant radiotherapy. A technique has been described using ADM coverage to treat and prevent capsular contracture with no recurrence in capsular contracture (n=11) over an average follow-up of 9.2 (range: 2.4-18.8) months.<sup>33</sup> Previous partial implant coverage using ADM has showed to result in a recurrence rate of 6.3% However, the observational nature and small sample size limit this study. However, the pre-pectoral technique with complete cover may be useful in preventing and treating capsular contracture.

Rippling could be a problem associated with the pre-pectoral technique. Lipomodelling can be used to successfully treat rippling, as shown by Becker et al. where it was used successfully in 6.4% of his patients.<sup>34</sup> He also observed that rippling was due to the use of saline implants which were changed to silicone in 9 patients (29%). The senior author observed no major rippling requiring intervention in her series with a mean follow up of 13.9 (range: 8.5-20.7) months.<sup>23</sup>

Thus, the muscle-sparing reconstructive technique preserves the natural anatomy thereby avoiding the adverse effects associated with sub-muscular reconstruction. These include preservation of shoulder function, minimising postoperative pain and the lack of animation deformity.<sup>29</sup> It is evident that implant based reconstruction constitutes a majority of the reconstruction practice in the US, UK and Europe and the pre-pectoral technique adds a whole new dimension.

## CONCLUSION

It seems, then, that the pre-pectoral breast reconstruction is safe and feasible. Its main advantages are that it avoids animation deformity, prevents shoulder dysfunction, and has a lower incidence of capsular contracture. However, it may cause rippling which can require further intervention (e.g. lipomodelling) although this is not specific to the pre-pectoral technique. With its relatively short learning curve and promising short-term outcomes, it seems to be a promising technique, however, further research looking at the long term follow-up is required to assess the aesthetic outcomes and long term morbidity that it may be associated with.

**Acknowledgements:** nil

## REFERENCES

1. Cancer Research UK. Breast Cancer Statistics. <http://www.cancerresearchuk.org/health-professional/cancer-statistics/statistics-by-cancer-type/breast-cancer>. Accessed April 13, 2016.
2. Jeevan R, Cromwell D, Browne J, et al. The National Mastectomy and Breast Reconstruction Audit. A national audit of provision and outcomes of mastectomy and breast reconstruction surgery for women in England. *Second Annu Rep.* 2009.
3. ASoP Surgeons. Plastic surgery statistics report. *Am Soc Plast Surg Arlingt Height.* 2012.
4. Ho G, Nguyen TJ, Shahabi A, Hwang BH, Chan LS, Wong AK. A systematic review and meta-analysis of complications associated with acellular dermal matrix-assisted breast reconstruction. *Ann Plast Surg.* 2012;68(4):346-356.
5. Serletti JM, Fosnot J, Nelson JA, Disa JJ, Bucky LP. Breast reconstruction after breast cancer. *Plast Reconstr Surg.* 2011;127(6):124e-35e. doi:10.1097/PRS.0b013e318213a2e6.
6. Wexelman B, Schwartz JA, Lee D, Estabrook A, Ma AMT. Socioeconomic and geographic differences in immediate reconstruction after mastectomy in the United States. *Breast J.* 20(4):339-346. doi:10.1111/tbj.12274.
7. Albornoz CR, Bach PB, Mehrara BJ, et al. A paradigm shift in U.S. Breast reconstruction: increasing implant rates. *Plast Reconstr Surg.* 2013;131(1):15-23. doi:10.1097/PRS.0b013e3182729cde.
8. McLaughlin SA. Surgical management of the breast: breast conservation therapy and mastectomy. *Surg Clin North Am.* 2013;93(2):411-428. doi:10.1016/j.suc.2012.12.006.
9. Akram M, Siddiqui SA. Breast cancer management: past, present and evolving. *Indian J Cancer.* 49(3):277-282. doi:10.4103/0019-509X.104486.
10. Moyer HR, Ghazi B, Daniel JR, Gasgarth R, Carlson GW. Nipple-sparing mastectomy: technical aspects and aesthetic outcomes. *Ann Plast Surg.* 2012;68(5):446-450. doi:10.1097/SAP.0b013e3182394bba.
11. Lanitis S, Tekkis PP, Sgourakis G, Dimopoulos N, Al Mufti R, Hadjiminis DJ. Comparison of skin-sparing mastectomy versus non-skin-sparing mastectomy for breast cancer: a meta-analysis of observational studies. *Ann Surg.* 2010;251(4):632-639. doi:10.1097/SLA.0b013e3181d35bf8.
12. Burdge EC, Yuen J, Hardee M, et al. Nipple skin-sparing mastectomy is feasible for advanced disease. *Ann Surg Oncol.* 2013;20(10):3294-3302. doi:10.1245/s10434-013-3174-4.
13. Harless C, Jacobson SR. Current strategies with 2-staged prosthetic breast reconstruction. *Gland Surg.* 2015;4(3):204-211. doi:10.3978/j.issn.2227-684X.2015.04.22.
14. Ibrahim AMS, Koolen PGL, Ashraf AA, et al. Acellular dermal matrix in reconstructive breast surgery: Survey of current practice among plastic surgeons. *Plast Reconstr Surg Glob Open.* 2015;3(4).
15. Gandhi A, Barr L, Johnson R. Bioprosthesis: Changing the landscape for breast

- reconstruction? *Eur J Surg Oncol*. 2013;39(1):24-25.
16. Macadam SA, Lennox PA. Acellular dermal matrices: Use in reconstructive and aesthetic breast surgery. *Can J Plast Surg*. 2012;20(2).
  17. Hartzell TL, Taghinia AH, Chang J, Lin SJ, Slavin SA. The use of human acellular dermal matrix for the correction of secondary deformities after breast augmentation: results and costs. *Plast Reconstr Surg*. 2010;126(5):1711-1720. doi:10.1097/PRS.0b013e3181ef900c.
  18. Becker S, Saint-Cyr M, Wong C, et al. AlloDerm versus DermaMatrix in immediate expander-based breast reconstruction: a preliminary comparison of complication profiles and material compliance. *Plast Reconstr Surg*. 2009;123(1):1-6-8. doi:10.1097/PRS.0b013e3181904bff.
  19. Tessler O, Reish RG, Maman DY, Smith BL, Austen WG. Beyond biologics: absorbable mesh as a low-cost, low-complication sling for implant-based breast reconstruction. *Plast Reconstr Surg*. 2014;133(2):90e-9e. doi:10.1097/01.prs.0000437253.55457.63.
  20. Forsberg CG, Kelly DA, Wood BC, et al. Aesthetic outcomes of acellular dermal matrix in tissue expander/implant-based breast reconstruction. *Ann Plast Surg*. 2014;72(6):S116-S120.
  21. Spear SL, Parikh PM, Reisin E, Menon NG. Acellular dermis-assisted breast reconstruction. *Aesthetic Plast Surg*. 2008;32(3):418-425.
  22. Sbitany H, Serletti JM. Acellular dermis-assisted prosthetic breast reconstruction: a systematic and critical review of efficacy and associated morbidity. *Plast Reconstr Surg*. 2011;128(6):1162-1169.
  23. Vidya R, Cawthorn S, Mausia J, et al. European prospective study on ninety muscle-sparing implant based breast reconstructions with pre-shaped acellular dermal matrix. *Breast J Press*. 2016.
  24. Martin L, O'Donoghue JM, Horgan K, Thrush S, Johnson R, Gandhi A. Acellular dermal matrix (ADM) assisted breast reconstruction procedures: joint guidelines from the Association of Breast Surgery and the British Association of Plastic, Reconstructive and Aesthetic Surgeons. *Eur J Surg Oncol*. 2013;39(5):425-429.
  25. Reitsamer R, Peintinger F. Prepectoral implant placement and complete coverage with porcine acellular dermal matrix: a new technique for direct-to-implant breast reconstruction after nipple-sparing mastectomy. *J Plast Reconstr Aesthetic Surg*. 2015;68(2):162-167.
  26. Schmitz M, Bertram M, Kneser U, Keller AK, Horch RE. Experimental total wrapping of breast implants with acellular dermal matrix: a preventive tool against capsular contracture in breast surgery? *J Plast Reconstr Aesthetic Surg*. 2013;66(10):1382-1389.
  27. Iqbal FM, Bhatnagar A, Vidya R. Host Integration of an Acellular Dermal Matrix: Braxon Mesh in Breast Reconstruction. *Clin Breast Cancer*. 2016.
  28. Cheng A, Lakhiani C, Saint-Cyr M. Treatment of capsular contracture using complete implant coverage by acellular dermal matrix: a novel technique. *Plast Reconstr Surg*. 2013;132(3):519-529.
  29. Caputo GG, Marchetti A, Dalla Pozza E, et al. Skin-Reduction Breast Reconstructions with Prepectoral Implant. *Plast Reconstr Surg*. 2016;137(6):1702-1705.

30. Casella D, Calabrese C, Bianchi S, Meattini I, Bernini M. Subcutaneous Tissue Expander Placement with Synthetic Titanium-Coated Mesh in Breast Reconstruction: Long-term Results. *Plast Reconstr Surg Glob Open*. 2015;3(12).
31. Casella D, Bernini M, Bencini L, et al. TiLoop® Bra mesh used for immediate breast reconstruction: comparison of retropectoral and subcutaneous implant placement in a prospective single-institution series. *Eur J Plast Surg*. 2014;37(11):599-604.
32. Bernini M, Calabrese C, Cecconi L, et al. Subcutaneous Direct-to-Implant Breast Reconstruction: Surgical, Functional, and Aesthetic Results after Long-Term Follow-Up. *Plast Reconstr Surg Glob Open*. 2015;3(12).
33. Becker H, Lind JG, II EGH. Immediate Implant-based Prepectoral Breast Reconstruction Using a Vertical Incision. *Plast Reconstr Surg Glob Open*. 2015;3(6).

## TABLES:

*Table 1: Indications for pre-pectoral breast reconstruction*

---

<b>Pre-pectoral breast reconstruction: indications</b>
<ul style="list-style-type: none"><li>• Immediate breast reconstruction</li><li>• Immediate delayed breast reconstruction</li><li>• Breast revision surgery for<ul style="list-style-type: none"><li>○ Animation deformity</li><li>○ Capsular contracture</li><li>○ Breast deformity</li></ul></li></ul>

---

ACCEPTED MANUSCRIPT

Table 2: Types of meshes

Type of Mesh	Types	Form	Availability
<b>ADM: Porcine</b>			
<ul style="list-style-type: none"> <li><b>Braxon® (Decomed S.r.l., Venezia, Italy)</b></li> </ul>	Porcine derived	Pre-shaped ADM	UK, Europe
<ul style="list-style-type: none"> <li><b>Strattice™ (Lifecell, Branchburg, New Jersey, USA)</b></li> </ul>		Flat sheet	UK, Some part of Europe, US
<b>ADM: Foetal Bovine</b>			
<ul style="list-style-type: none"> <li><b>SurgiMend (TEI Biosciences, Boston, Massachusetts, USA)</b></li> </ul>	Bovine derived	Flat sheet	UK, Some part of Europe, US
<b>Synthetic mesh</b>			
<ul style="list-style-type: none"> <li><b>TiLOOP Bra (PFM Medical, Cologne, Germany)</b></li> </ul>	Titanium coated polypropylene mesh	Flat sheet	Mainly in UK, Europe
<ul style="list-style-type: none"> <li><b>TIGR Matrix Surgical Mesh (Novus Ltd, Singapore)</b></li> </ul>	copolymer of glycolide and trimethylene carbonate	Flat sheet	Mainly in UK, Europe
<ul style="list-style-type: none"> <li><b>Knitted Vicryl Mesh (Vicryl, Ethicon, New Jersey, USA)</b></li> </ul>	Polyglactin 910	Flat sheet	Mainly in US, and some part of Europe
ADM: acellular dermal matrix			



## FIGURES

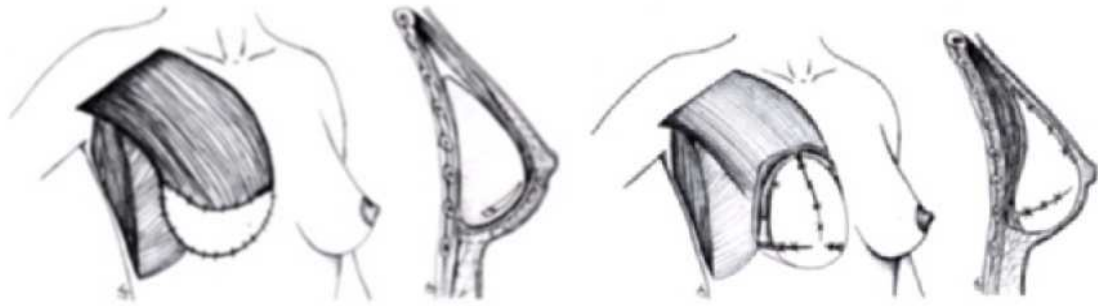


Figure 1a (left): demonstrates the pectoral muscle and the mesh which forms the pocket for the implant which is placed sub-pectorally; 1b (right): demonstrates the mesh which forms the pocket for the implant which is placed pre-pectorally.

ACCEPTED MANUSCRIPT

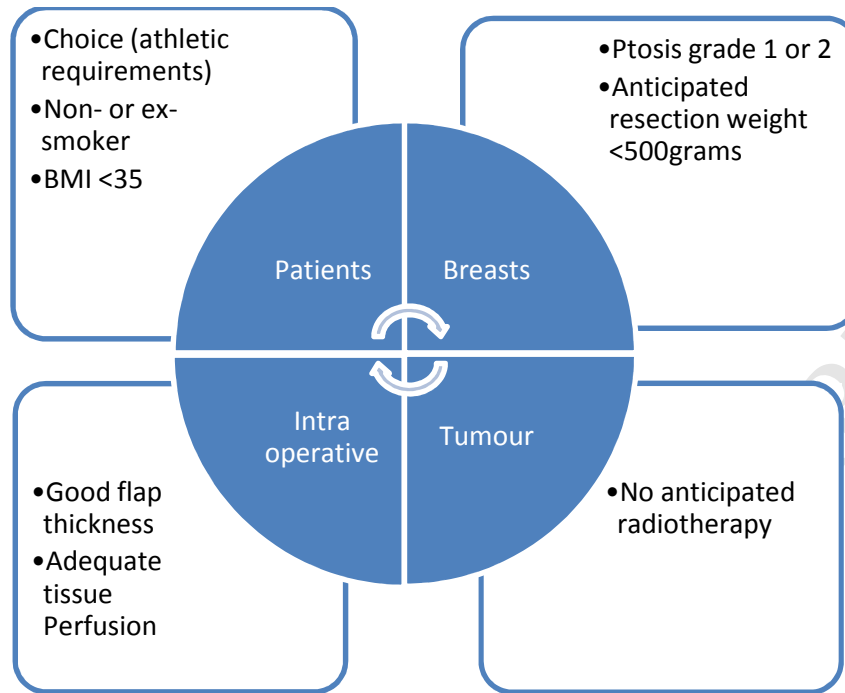
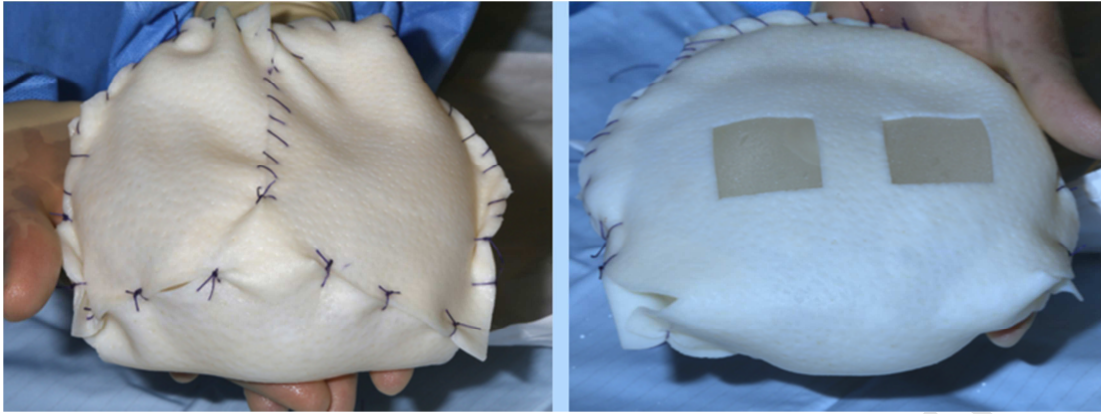


Figure 2: Patient selection criteria



*Figure 3: Pre-shaped Braxon® mesh wrapped around the implant*

ACCEPTED MANUSCRIPT

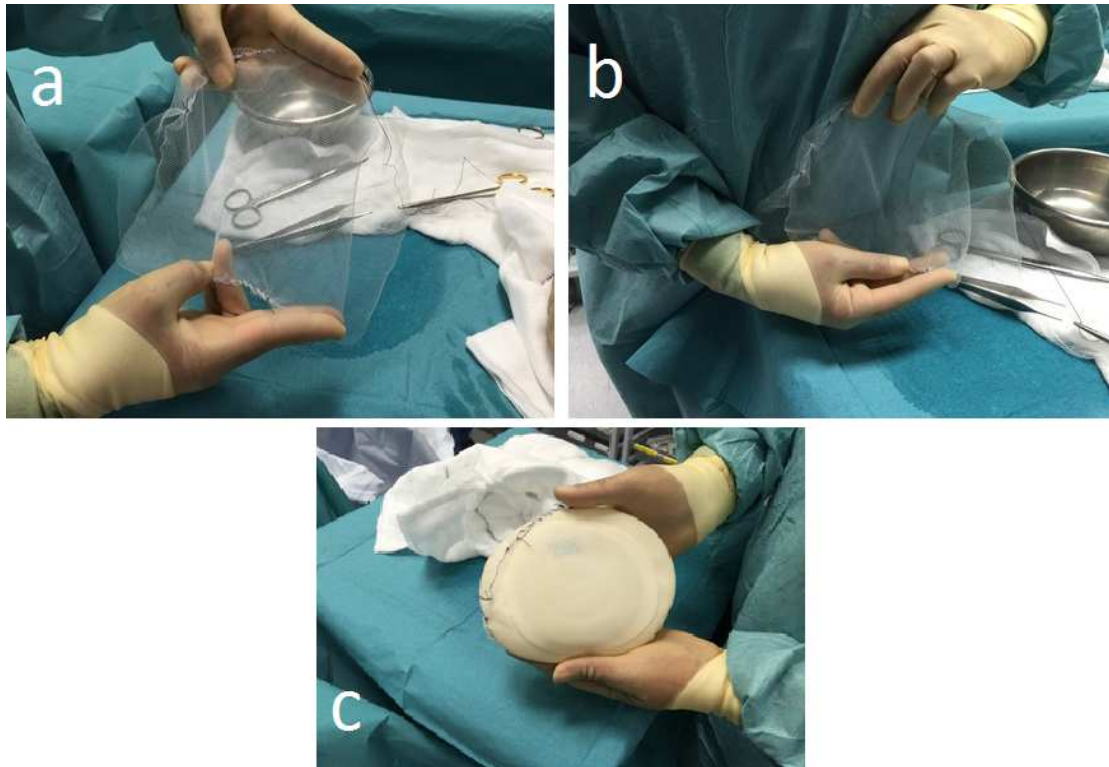


Figure 4: Mesh cover for the implant with synthetic mesh (Tilloop®): a) flat mesh; b) edges of the mesh are sutured; c) implant covering with the mesh as the mesh forms a close fitting wrap