

Breathlessness and neck swelling after a rugby game

Gittoes, Oliver; Gittoes, Neil

DOI:

[10.1136/bmj.j311](https://doi.org/10.1136/bmj.j311)

License:

Other (please specify with Rights Statement)

Document Version

Publisher's PDF, also known as Version of record

Citation for published version (Harvard):

Gittoes, O & Gittoes, N 2017, 'Breathlessness and neck swelling after a rugby game', *BMJ*, vol. 356, j311.
<https://doi.org/10.1136/bmj.j311>

[Link to publication on Research at Birmingham portal](#)

Publisher Rights Statement:

Published by the BMJ Publishing Group Limited. For permission to use (where not already granted under a licence) please go to <http://group.bmj.com/group/rights-licensing/permissions>

General rights

Unless a licence is specified above, all rights (including copyright and moral rights) in this document are retained by the authors and/or the copyright holders. The express permission of the copyright holder must be obtained for any use of this material other than for purposes permitted by law.

- Users may freely distribute the URL that is used to identify this publication.
- Users may download and/or print one copy of the publication from the University of Birmingham research portal for the purpose of private study or non-commercial research.
- User may use extracts from the document in line with the concept of 'fair dealing' under the Copyright, Designs and Patents Act 1988 (?)
- Users may not further distribute the material nor use it for the purposes of commercial gain.

Where a licence is displayed above, please note the terms and conditions of the licence govern your use of this document.

When citing, please reference the published version.

Take down policy

While the University of Birmingham exercises care and attention in making items available there are rare occasions when an item has been uploaded in error or has been deemed to be commercially or otherwise sensitive.

If you believe that this is the case for this document, please contact UBIRA@lists.bham.ac.uk providing details and we will remove access to the work immediately and investigate.



ENDGAMES

SPOT DIAGNOSIS

Breathlessness and neck swelling after a rugby game

Oliver M J Gittoes *student*¹, Neil J L Gittoes *consultant and honorary professor*²

¹Bromsgrove School, Bromsgrove, Worcestershire, UK; ²Centre for Endocrinology, Diabetes and Metabolism, Heritage Building, Queen Elizabeth Hospital, Edgbaston, Birmingham, UK

A 16 year old boy presented to the emergency department with breathlessness and painful neck swelling after playing in a game of rugby. He had not sustained any trauma to the neck or chest. He had a history of asthma and had recently had an upper respiratory tract infection. His breathlessness was not helped by his salbutamol and he described the neck swelling and breathlessness progressively worsening since the match. What abnormalities are identified in the radiograph (fig 1) and what do they signify as the underlying diagnosis?

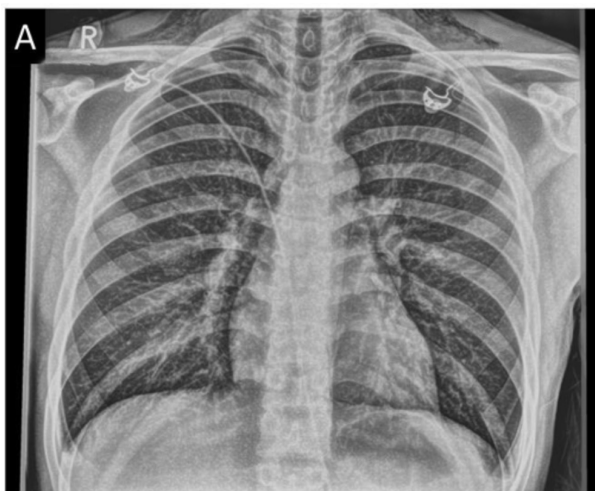


Fig 1 Posteroanterior chest radiograph

around the cardiac silhouette in association with air in the soft tissues in the neck confirmed a pneumomediastinum (fig 2). Nasendoscopy with a computed tomography (CT) scan revealed no evidence of disruption to the trachea or oesophagus (fig 3). By exclusion, a diagnosis of spontaneous pneumomediastinum was made. Symptoms and signs abated within 72 hours and the patient made a full recovery, returning to full play three weeks later.

Short answer

The radiograph shows air in the mediastinum with surgical emphysema.

Discussion

The patient came to medical attention after describing swelling. Surgical emphysema was suspected clinically after he presented with a “crackling and crunching” sensation in his neck. No pneumothorax was seen on the radiograph, but a thin rim of air

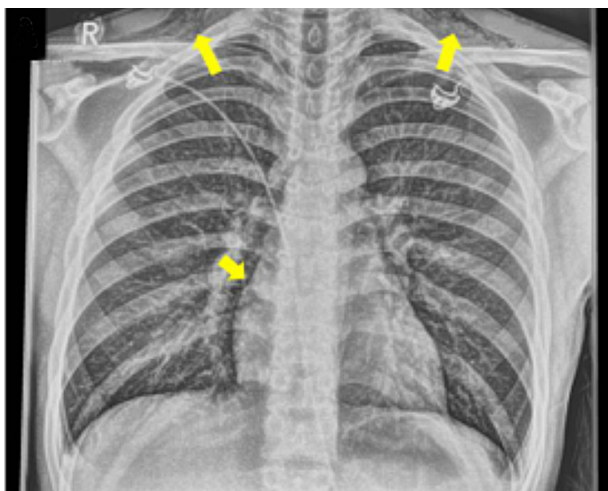


Fig 2 Air around the cardiac silhouette (arrows), with air in soft tissue in the supraclavicular regions

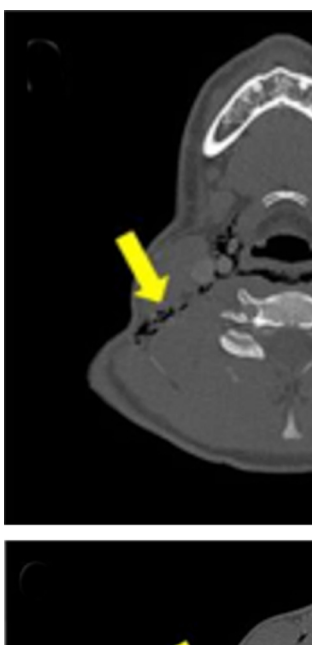


Fig 3 Computed tomography (CT) images of the neck (A, B) and chest (C) show air diffusely throughout mediastinum and interspersed between mediastinal structures. The CT scan showed no evidence of tracheal or oesophageal abruption

Spontaneous pneumomediastinum is associated with poorly controlled asthma, upper respiratory tract infections, and forced Valsalva manoeuvres.¹ The condition predominantly affects teenagers and younger adults.

Spontaneous pneumomediastinum usually resolves quickly with supportive care during the acute episode (control of underlying asthma, analgesia, rest, and oxygen therapy where necessary).^{2,3} There is no requirement for prophylactic antibiotics unless there is evidence of oesophageal rupture. Although not usually recurrent, emphasis should be on achieving optimal control of any underlying causal factors such as poorly controlled asthma. Clinical signs may not be overt unless there is palpable surgical emphysema.⁴

Learning points

Spontaneous pneumomediastinum is a diagnosis of exclusion.

Careful history and physical examination, with a high index of clinical suspicion supported by plain chest radiograph can reveal the diagnosis. Supportive care is appropriate and the focus should be on treating any underlying predisposing factors.

The authors have read and understood BMJ policy on declaration of interests and declare no competing interests.

Patient consent obtained.

- 1 Gasser CR, Pellaton R, Rochat CP. Pediatric Spontaneous Pneumomediastinum: Narrative Literature Review. *Pediatr Emerg Care* 2016; [Epub ahead of print]. doi:10.1097/PEC.0000000000000625 pmid:26855340.
- 2 Sahni S, Verma S, Grullon J, Esquire A, Patel P, Talwar A. Spontaneous pneumomediastinum: time for consensus. *N Am J Med Sci* 2013;356:460-4.. doi:10.4103/1947-2714.117296 pmid:24083220.
- 3 Fitzwater JW, Silva NN, Knight CG, Malvezzi L, Ramos-Irizarry C, Burnweit CA. Management of spontaneous pneumomediastinum in children. *J Pediatr Surg* 2015;356:983-6.. doi:10.1016/j.jpedsurg.2015.03.024 pmid:25840604.
- 4 Richer EJ, Sanchez R. Are esophagrams indicated in pediatric patients with spontaneous pneumomediastinum? *J Pediatr Surg* 2016;356:1778-81.. doi:10.1016/j.jpedsurg.2016.05.024 pmid:27320840.

Published by the BMJ Publishing Group Limited. For permission to use (where not already granted under a licence) please go to <http://group.bmj.com/group/rights-licensing/permissions>