

# The role of hysteroscopy in diagnosis of menstrual disorders

Mahmud, Ayesha; Smith, Paul; Clark, Justin

DOI:

[10.1016/j.bpobgyn.2015.03.023](https://doi.org/10.1016/j.bpobgyn.2015.03.023)

License:

Creative Commons: Attribution-NonCommercial-NoDerivs (CC BY-NC-ND)

*Document Version*

Peer reviewed version

*Citation for published version (Harvard):*

Mahmud, A, Smith, P & Clark, J 2015, 'The role of hysteroscopy in diagnosis of menstrual disorders', *Best Practice & Research: Clinical Obstetrics & Gynaecology*. <https://doi.org/10.1016/j.bpobgyn.2015.03.023>

[Link to publication on Research at Birmingham portal](#)

## **Publisher Rights Statement:**

Eligibility for repository: checked 26/08/15

## **General rights**

Unless a licence is specified above, all rights (including copyright and moral rights) in this document are retained by the authors and/or the copyright holders. The express permission of the copyright holder must be obtained for any use of this material other than for purposes permitted by law.

- Users may freely distribute the URL that is used to identify this publication.
- Users may download and/or print one copy of the publication from the University of Birmingham research portal for the purpose of private study or non-commercial research.
- User may use extracts from the document in line with the concept of 'fair dealing' under the Copyright, Designs and Patents Act 1988 (?)
- Users may not further distribute the material nor use it for the purposes of commercial gain.

Where a licence is displayed above, please note the terms and conditions of the licence govern your use of this document.

When citing, please reference the published version.

## **Take down policy**

While the University of Birmingham exercises care and attention in making items available there are rare occasions when an item has been uploaded in error or has been deemed to be commercially or otherwise sensitive.

If you believe that this is the case for this document, please contact [UBIRA@lists.bham.ac.uk](mailto:UBIRA@lists.bham.ac.uk) providing details and we will remove access to the work immediately and investigate.

# Accepted Manuscript

The role of hysteroscopy in diagnosis of menstrual disorders

Ayesha Mahmud, Dr. Paul Smith, Justin Clark

PII: S1521-6934(15)00109-1

DOI: [10.1016/j.bpobgyn.2015.03.023](https://doi.org/10.1016/j.bpobgyn.2015.03.023)

Reference: YBEOG 1517


To appear in: *Best Practice & Research Clinical Obstetrics & Gynaecology*

Received Date: 3 March 2015

Accepted Date: 18 March 2015

Please cite this article as: Mahmud A, Smith P, Clark J, The role of hysteroscopy in diagnosis of menstrual disorders, *Best Practice & Research Clinical Obstetrics & Gynaecology* (2015), doi: 10.1016/j.bpobgyn.2015.03.023.

This is a PDF file of an unedited manuscript that has been accepted for publication. As a service to our customers we are providing this early version of the manuscript. The manuscript will undergo copyediting, typesetting, and review of the resulting proof before it is published in its final form. Please note that during the production process errors may be discovered which could affect the content, and all legal disclaimers that apply to the journal pertain.



## **The role of hysteroscopy in diagnosis of menstrual disorders**

Ayesha Mahmud<sup>1,2</sup>, Paul Smith<sup>1,2</sup>, Justin Clark<sup>1,2</sup>

Affiliations:

1. Birmingham Women's NHS Foundation Trust, Mindelsohn way, Edgbaston, B15 2TG
2. University of Birmingham.

Corresponding author:

Dr. Paul Smith  
Birmingham Women's Hospital  
Department of Obstetrics and Gynaecology  
Metchley Lane  
Birmingham B16 0EP  
United Kingdom  
E-mail: [paul.smith@doctors.net.uk](mailto:paul.smith@doctors.net.uk)

# Abstract (150 words)

Menstrual disorders affect up to 30% of women of reproductive age and can have a significant impact on their quality of life. Hysteroscopy is frequently used to assess and treat endometrial pathology, which can cause abnormal uterine bleeding. There is growing evidence that hysteroscopy is an essential tool in outpatient management of patients. This chapter will deal with the evidence surrounding the role of hysteroscopy in a range of menstrual disorders.

Key words: Menstrual disorders; abnormal uterine bleeding; hysteroscopy; office; outpatient

## INTRODUCTION

### Background

Hysteroscopy is the corner stone of modern day outpatient endoscopic treatments in gynecology. The first successful diagnostic and operative hysteroscopy was performed by DC Pantaleoni of Ireland, in 1869[1]. He utilized a modified cystoscope and reflected candlelight to examine and treat a polyp in a patient with post-menopausal bleeding (PMB). This paved the way forward for urologists and gynecologists to develop and achieve advancements in endoscopic procedures. Charles David in 1907 was the first to describe a lens system that would allow uterine cavity visualization[2]. Nevertheless, it wasn't until 1943 when, the combination of a cold light source developed by Forestiere[3] and a rod lens system developed by Professor Hopkins[4], revolutionized uterine cavity assessment and formed the basis of modern day out patient and in patient gynecologic endoscopy.

Initially, hysteroscopy was developed as an inpatient procedure, which was done under general anesthetic. Advances in technology and in particular miniaturization of optics, has increasingly allowed both diagnostic and minor hysteroscopic surgical procedures to be performed in the outpatient setting [5–8]. Outpatient hysteroscopy has been shown to be safe and acceptable to

women. Research has shown that the outpatient approach is more cost-effective and patients value the convenience of an immediate diagnosis [9,10]. This allows women to be counseled about their treatment options thus avoiding lengthy follow-up appointments. Moreover, in some cases treatment can be started immediately in what is known as a 'one-stop' service. Hence, office hysteroscopy is a well-accepted, convenient, cost-effective and rapid access 'see and treat' solution for several menstrual disorders [9–11].

### **Menstrual disorders**

Menstrual disorders are problems that affect the normal menstrual cycle and commonly present as abnormal uterine bleeding (AUB) (Figure 1). These are fairly common amongst women of childbearing age with a reported incidence of about 9-14% and can have a major impact on the quality of life, of women of all ages [12].

<<Figure 1 here >>

Whilst, these irregularities can present as disorders of menstrual flow, timing and duration, there are several organic and non-organic causes for this disruption. NICE describes the term dysfunctional uterine bleeding (DUB) as abnormal uterine bleeding (AUB) in the absence of organic disease [13].

In 2011, the International Federation of Gynecology and Obstetrics (FIGO) approved the PALM-COEIN classification as a FIGO classification system for the purpose of standardizing nomenclature for the causes of abnormal uterine

bleeding (Figure 2)[14]. This new classification was introduced to facilitate clinicians, researchers and patients in their interaction, communication, and reporting to provide clinically effective care.

It is known that abnormal uterine bleeding can affect the quality of life of the individual concerned and can also represent an early warning sign of uterine malignancy, especially if occurring once menopause ensues. In these cases, careful clinical evaluation and assessment for treatment is merited. Hysteroscopy allows rapid assessment and treatment of conditions that cause abnormal uterine bleeding.

<<Figure 2 here>>

This chapter provides an overview of existing evidence and good practice in relation to the role of hysteroscopy in the diagnosis of menstrual disorders presenting as AUB in non-pregnant women.

### **Approach to clinical evaluation in menstrual disorders**

Women with menstrual disorders may present with a wide range of variable symptoms with different etiologies. It is estimated that a quarter of women are referred to gynecology clinics with AUB [15]. In women below the age of 40 years endometrial cancer is rare, however, it's incidence rises steeply beyond ages 45 and 50+ years. Up to 10% of women with post menopausal bleeding (PMB) will have endometrial cancer [16]. Therefore, it is pertinent to adopt a structured approach to clinical evaluation before recommending diagnostic

imaging or treatment options. A suggested approach is summarized in Table 1 below.

History	<p>Menstrual history:</p> <ul style="list-style-type: none"> <li>• Age group: Pre-pubertal, Reproductive, Post-menopausal</li> <li>• Last menstrual bleeding</li> <li>• Cycle intervals, quantity and duration of flow</li> <li>• Pre-menstrual symptoms</li> <li>• Post-coital bleeding</li> <li>• Inter-menstrual bleeding</li> <li>• Cervical smear</li> <li>• Trauma or foreign body</li> <li>• Sexually transmitted infections</li> </ul> <p>Associated symptoms:</p> <ul style="list-style-type: none"> <li>• Pain (dysmenorrhea, dyspareunia)</li> <li>• Vaginal discharge</li> <li>• Fever</li> <li>• Symptoms of fatigue</li> <li>• Changes in bowel and bladder function</li> <li>• Impact on quality of life</li> </ul> <p>Medical History:</p> <ul style="list-style-type: none"> <li>• Personal or family history of hematological disorders: coagulopathy, leukemia, von Willebrand disease, platelet disorders</li> </ul>
---------	--

	<ul style="list-style-type: none"> <li>• Changes in body weight, loss of appetite</li> <li>• Medication: Anti-coagulants, tamoxifen, anti-depressants, corticosteroids, thyroxine, contraceptives, hormone replacement therapy</li> <li>• Hyperestrogenic state: Diabetes, Polycystic ovarian syndrome</li> <li>• Liver disease, Thyroid dysfunction, Renal disease, Pituitary dysfunction</li> <li>• Smoking</li> <li>• Family history of gynecological malignancy</li> </ul>
Examination	<p>General Physical examination:</p> <ul style="list-style-type: none"> <li>• Pallor</li> <li>• Signs of systemic illness (Thyroid disease, liver disease, bleeding disorders)</li> <li>• BMI</li> <li>• Abdominal mass</li> <li>• Signs of hyperandrogenism: acne, hirsutism, male pattern baldness</li> </ul> <p>Gynecological examination:</p> <ul style="list-style-type: none"> <li>• Assess perineum for any signs of atrophy, ulceration, infection, mass or lesion</li> <li>• Speculum examination: Rule out cervical pathology, pap smear and swabs for infection screening (Chlamydia and Gonorrhea nucleic acid amplification test) if indicated</li> </ul>

- Bi-manual examination: Assess uterine size, mobility, consistency and assess for adnexal masses
- Per-rectal examination: If suspicion of non-genital bleeding or malignancy involving parametrium or rectum.

Table 1: Clinical evaluation in AUB

A thorough history and examination provides insight in to the possible causes of AUB. From this point on it is necessary to ascertain whether the suspected cause warrants immediate evaluation i.e. within two weeks or a more routine approach with evaluation in six weeks or more. In cases where a high risk of malignancy is possible (PCOS, diabetes, tamoxifen, unopposed estrogen therapy, palpable abdominal mass, cervical or vulvo-vaginal mass on examination or post-menopausal bleeding, non-cyclical bleeding in women on HRT) immediate referral to a specialist clinic for further evaluation is warranted. Whereas cases where the bleeding may be secondary to more benign causes local routine referral pathways should be followed.

### **Approach to diagnostics in menstrual disorders**

Historically, various diagnostic approaches have been suggested for preliminary investigation of menstrual disorders. Basic blood testing such as a full blood count allows evaluation of degree of anemia. Other tests; such as coagulation screening, renal function tests, prolactin, androgen levels and thyroid function tests etc are undertaken based on history-defined suspicion of disease.

The most commonly used investigation method in gynecological imaging is the pelvic transvaginal ultrasound (TVUS); this combined with endometrial biopsy and/or office hysteroscopy provides an invaluable diagnostic combination for assessment of AUB. Other imaging methods that have been suggested are saline infusion sonography (SIS) and special modalities such as CT and MRI (used when malignancy is suspected). These methods are complementary assessment tools. It is also important to note that dilatation and curettage (D&C) is now only used in exceptional circumstances, as it requires general anesthesia, and has been largely replaced by outpatient endometrial biopsy.

### **Pelvic transvaginal ultrasound (TVUS)**

With the use of TVUS, it is possible to visualize and assess the uterine cavity and the adjacent adnexa, when planning further treatment options. This provides valuable information such as endometrial thickness (ET) and the presence or absence of structural abnormalities such as polyps or fibroids. TVUS is also minimally invasive and widely acceptable to women and helps triage women requiring further treatment. The sensitivity and specificity of TVUS for detection of fibroids and polyps alongside ET is 80% and 69% respectively [17]. Therefore, to prevent endometrial lesions being missed, it is increasingly being suggested that hysteroscopy or SIS is recommended to further evaluate the endometrium[18]. In pre-menopausal women ET is best assessed on day four to six of the menstrual cycle as this is the time when the endometrium should be at its thinnest. If uterine cavity pathology is suspected then further investigation is merited. Furthermore, in cases where medical treatment has been unsuccessful

in premenopausal women hysteroscopy should be performed as there may be underlying pathology, which may not be visible on TVUS.

In post-menopausal women with PMB endometrial cancer is a major concern. Measuring ET on TVUS is valuable in triaging women who are at greater risk of endometrial cancer. A suggested threshold of  $\leq 4\text{mm}$  for ET with a regular endometrial lining and no fluid within the cavity reduces the possibility of malignancy to  $<1\%$  in postmenopausal women [19,20]. An ET measuring  $>4\text{mm}$  warrants endometrial sampling as the risk of malignancy is higher [19,20]. TVUS thus allows adequate sensitivity for this threshold with a false-negative rate of 0.25-0.50% and without excessive false-positive rates [21]. If clinical suspicion of malignancy persists, especially in symptomatic or high risk cases, then it is advisable to perform hysteroscopic evaluation as some endometrial pathology may be missed. The risk factors for endometrial cancer are obesity, diabetes, nulliparity, history of PCOS, and family history of hereditary non-polyposis colorectal cancer.

### **Saline infusion sonography**

Compared to TVUS, saline infusion sonography (SIS) provides more information regarding intra-cavity uterine pathology, especially in cases where AUB persists despite a normal endometrial measurement on TVUS. This applies to women of all ages with AUB. Studies suggest that SIS has similar sensitivity and specificity for some endometrial lesions when compared to hysteroscopy.<sup>21</sup> However, hysteroscopy can allow simultaneous treatment in the form of removal of the endometrial lesions such as polyps and small submucous fibroids. Table 2

provides a summary of the sensitivity and specificity information of SIS for endometrial pathology as reported in a recent systematic review and meta-analysis [22].

Technique	Pathology	Sensitivity (95% CI)	Specificity (95% CI)	Evidence Source
SIS	Endometrial Polyps	0.82 (0.76-0.86)	0.96 (0.95-0.98)	Seshadri et al 2014 (Systematic review and meta-analysis)
	Submucous fibroids	0.82 (0.69-0.92)	1.00 (0.98-1.00)	
	Intrauterine adhesions	0.82 (0.65-0.93)	0.99 (0.98-1.00)	
	All intrauterine pathology	0.88 (0.85-0.90)	0.94 (0.93-0.96)	

Table 2: Sensitivity and specificity of Saline infusion sonography for endometrial pathology

### Hysteroscopy

Hysteroscopic equipment and associated technologies have rapidly advanced in recent years increasing the feasibility and range of hysteroscopic and surgical techniques for the treatment of women with AUB. In particular the miniaturization of hysteroscopic equipment has facilitated one of the biggest recent changes in hysteroscopic practice, which is the establishment of outpatient diagnostic and therapeutic services. The development of the miniature ancillary mechanical and electrosurgical equipment has allowed intrauterine pathologies such as polyps and small submucous fibroids to be removed in the outpatient setting. During the visit the patient can also be fitted with a levonorgestrol-releasing intrauterine system (LNG-IUS) to treat HMB. This has led to contemporary models of care for women moving to 'one-stop'

ambulatory clinics, rather than traditional models which involve multiple hospital visits to review results.

The 'one-stop' ambulatory hysteroscopy clinics have potential benefits for clinicians, patients and health services. Outpatient hysteroscopy has the advantage of providing a real time diagnosis that avoids anxiety, inconvenience and costs associated with follow-up appointments. Different treatment options can be discussed and in some cases they can be initiated, avoiding morbidity associated with delays in initiating treatment. The use of expensive theatre resources and inpatient hospital beds are substantially reduced, increasing service capacity [9,11].

The adoption of 'one-stop' hysteroscopy clinics is further supported by a recent cost-effectiveness analysis examining the use of TVS, endometrial biopsy and SIS for the investigation of heavy menstrual bleeding. The results of the study showed that outpatient hysteroscopy or outpatient hysteroscopy with endometrial biopsy were the most cost-effective options [9]. Several studies have reported on the diagnostic accuracy of hysteroscopy the results of a recent meta-analysis are shown in Table 3 [23].

Technique	Pathology	Sensitivity (95% CI)	Specificity (95% CI)	Evidence Source
Hysteroscopy	Endometrial Polyps	95.4% (87.4-98.4)	96.4% (93.7-98.0)	Gkrozou et al 2014 (Meta-analysis)
	Submucous fibroids	97.0% (89.8-99.2)	98.9% (93.3-99.8)	
	Endometrial Cancer	82.6% (66.9-91.8)	99.7% (98.1-99.9)	
	Endometrial hyperplasia	75.2% (55.4-88.1)	91.5% (85.7-95.0)	

Table 3: Sensitivity and specificity of hysteroscopy for endometrial pathology

## **Post menopausal bleeding**

Most guidelines suggest that TVUS is used as the first line investigation for women presenting with PMB[24,25]. When the endometrium is smooth and the thickness is  $\leq 4\text{mm}$  with no free fluid in the endometrial cavity the incidence of malignancy is  $<1\%$  and in this situation no further investigation is required. Otherwise it is recommended that further investigation in the form of an endometrial biopsy is performed [19,20].

When the TVUS shows endometrial irregularities it is important to investigate with a modality that can identify discrete pathology, like hysteroscopy or SIS. Moreover, a study looking at those with recurrent PMB after previous normal investigation showed a higher incidence of endometrial polyps suggesting these women should also be investigated with hysteroscopy or SIS [18]. Although outpatient hysteroscopy is more uncomfortable than TVUS, outpatient hysteroscopy is acceptable and very well tolerated [26]. Furthermore, there is evidence from structured interviews of patients that women are willing to undergo more invasive investigations, in the form of hysteroscopy, for the extra reassurance it provides [11].

## **Endometrial biopsy**

Outpatient endometrial biopsy is a blind procedure often undertaken with a pipelle device. Although, such a biopsy is convenient, quick, safe and acceptable to most women, a large proportion of these biopsies may be reported as being insufficient or inadequate. Furthermore, it has a lower sensitivity for picking up

focal and pedunculated lesions, such as a polyp or fibroid, which may be completely missed [27].

### **Approach to management of menstrual disorders**

Management of menstrual disorders depends entirely on initial clinical evaluation, investigations and patient preference of treatment options. Both pharmacological and surgical approaches (minimally-invasive and open techniques) are suitable options.

### **Pharmacological approach**

In most cases of AUB with anovulation pharmacological treatment is appropriate, while in cases of AUB due to structural causes, surgical intervention is indicated. Some commonly prescribed medical treatments are listed below (Table 4).

<b>Pharmacological treatment options</b>
<b>Oral contraceptive pills</b>
<b>Gonadotrophin-releasing hormone (GnRH) agonists</b>
<b>levonorgestrel-releasing intrauterine system (LNG-IUS)</b>
<b>Non-steroidal Anti-inflammatory Drugs (NSAIDs)</b>
<b>Progesterone therapy</b>
<b>Tranexamic acid</b>

**Desmopressin acetate (DDAVP in von Willebrand disease)**

Table 4: Pharmacological treatment options in menstrual disorders

When considering treatment options individual patient factors such as age, body mass index, contraindications to therapy and treatment expectations should be kept in mind.

**Surgical approach**

Structural abnormalities require surgical treatment in most cases of AUB. These days most cases are managed using minimal-invasive techniques such as hysteroscopy and laparoscopy. Open-techniques such as laparotomy for myomectomy or hysterectomy are become less common and are used only in selected cases.

**Specific Role of hysteroscopy in evaluation of uterine cavity**

Office hysteroscopy is the main stay of modern day out patient management of AUB. It also remains a 'gold standard' tool for uterine cavity assessment and treatment of intra-uterine pathology such as polyps, submucous fibroids and endometrial pathology. It's high sensitivity and specificity, safety and acceptability allows accurate diagnosis. Therefore, hysteroscopy is useful in diagnosis and treatment of menstrual disorders [28].

## **Polyps**

Endometrial polyps arise from the endometrium and can present with asymptomatic women or in symptomatic women with post-coital or inter-menstrual bleeding. 10% of women with infertility and between 25-60% of women with AUB may present with endometrial polyps [29,30]. A polyp is usually diagnosed using TVUS, SIS or at time of diagnostic hysteroscopy. The usual appearance of a polyp is that of a pedunculated fleshy pink lump or growth arising from the uterine endometrium with a narrow or broad stalk at the base. Most polyps are benign and have no consequence. However, some may be associated with endometrial hyperplasia with or without atypia and others with endometrial cancer. Therefore, hysteroscopic polypectomy is advised for symptom relief and to rule out malignancy, especially in the post-menopausal age group. The traditional approach to polypectomy was blind avulsion, but this led to issues with recurrence of symptoms and missed histological diagnosis of endometrial cancer [31]. Increasingly, polypectomy is now done under direct vision in the outpatient setting without general anesthesia [8]. A recently completed large RCT comparing inpatient to outpatient polypectomy for abnormal uterine bleeding showed there was no difference in efficacy but a significant reduction in cost [32]. Further improvements in speed, acceptability, pain scores and failure rates have been made by using the new morcellator technologies [33].

## **Fibroids**

Submucous fibroids can distort the uterine cavity and present as a pedunculated mass with symptoms of pain and heavy menstrual bleeding. They can also lead to infertility and recurrent miscarriage. Therefore, most cases warrant fibroid resection.

The depth of invasion of the myometrium dictates the type and treatment options of the fibroids. Submucous fibroids are generally classified according to the European Society of Gynaecological Endoscopy (ESGE) into three types (Table 5). Type 0 and 1 are suitable for hysteroscopic resection. Smaller fibroids may be resected in an outpatient setting. Fibroid resection in these cases is both curative and therapeutic. Moreover, fibroid resection improves fertility [34].

Fibroids are easily identifiable on TVUS, but intramural fibroids may be wrongly diagnosed as submucosal and vice-versa. This can have a significant impact on the management of women because the depth of myometrial invasion dictates the type of treatment available. Outpatient diagnostic hysteroscopy can help with the grading of fibroids and the formulation of a management plan with the best technique, setting and preparation. Some small submucous fibroids may be amenable to resection in the outpatient setting.

Type 0- whole of submucosal fibroid inside the uterine cavity.

Type 1- <50% extension of submucous fibroid into myometrium.

Type 2- >50% extension into myometrium.

Table 5: ESGE classification of Submucosal fibroids

### **Endometrial pathology**

Endometrial hyperplasia is the precursor for endometrial cancer. Endometrial cancer has innumerable appearances; with a combination of any of these features, i.e. thickened, irregular endometrium, friable cells with hemorrhagic appearances of the endometrial cavity.

Although both cancerous and pre-cancerous endometrial disease can be identified by direct visualization, the 'gold-standard' for diagnosis is still histological sampling. However, hysteroscopy can be beneficial by allowing directed biopsies, as endometrial hyperplasia and cancer may be localized or global.

A technique known as vaginoscopy which involves the insertion of a hysteroscope in to the uterine cavity without the use of a speculum or genital tract instrumentation can help histological sampling when access is limited, for example in cases of vaginal stenosis [35].

### **Intra-uterine adhesions**

Intrauterine adhesions, or Asherman's syndrome, can present with amenorrhoea or irregular menstrual bleeding [26]. It is thought that scarring occurs when there is damage to the basilar layer of the endometrium. Removal of adhesions is associated with resolution of bleeding symptoms and has been shown to increase clinical pregnancy rates in those with recurrent implantation failure following in vitro fertilization [36].

Traditionally, intrauterine adhesions were diagnosed with hysterosalpinography, but now hysteroscopy is the established technique diagnosing intrauterine adhesions [26]. The usual appearance of intrauterine adhesions is that of greyish-white fibrous bands (fine to dense) extending across the uterine cavity in a haphazard manner, which is frequently associated with obliteration of the uterine cavity. Compared with radiological investigations hysteroscopy can more accurately confirm the presence, location and extent of scarring, although hysterosalpingography (HSG) is useful for determining tubal patency. Hysteroscopy also has the advantage of being able to treat scar tissue with blunt, sharp or electrical dissection using miniature scissors and bipolar electrosurgical equipment that can be passed down the operating port of the hysteroscope.

Filmy adhesions may be treated in the outpatient setting, but dense fibrous myometrial bands, which appear as pale patches, are normally removed with a general or regional anesthetic. Outpatient hysteroscopy is also useful for a second look after treatment to ensure that scar tissue has not reformed.

## Summary

Menstrual disorders presenting with abnormal uterine bleeding are a significant problem amongst both women of reproductive age and those who have undergone menopause. Hysteroscopy continues to have a well-recognized role in the diagnosis and management of abnormal uterine bleeding especially structural causes.

**Practice points**

- A clear approach to clinical history and examination is often sufficient to indicate the underlying cause for AUB and the need for further testing.
- Imaging should be undertaken where examination suggests a structural cause, where conservative management has failed or where there is a higher suggestive risk of malignancy.
- Outpatient hysteroscopy is a quick, cost-effective and practical 'See and treat' approach to management of AUB.
- SIS, TVUS and hysteroscopy all have comparable sensitivity and specificity for identification of uterine pathology. However, hysteroscopy remains the gold standard for uterine cavity assessment and treatment.
- Newer techniques such as vaginoscopy in hysteroscopy are particularly useful in managing difficult cases such as vaginal stenosis where access to the uterine cavity is difficult.
- Histological diagnosis remains the main stay of definitive diagnosis in cases of AUB.
- Outpatient hysteroscopy is well accepted by patients and is the future of management of AUB in an outpatient setting.

**Research agenda**

- Further research is needed to decrease the pain and increase the acceptability of outpatient hysteroscopy.

- More research should be aimed at determining the cost-effectiveness and efficacy of different diagnostic strategies.

#### Conflict of Interest:

T. Justin Clark has received honoraria from Hologic, Gynecare, Smith & Nephew and Ethicon to run training workshops in office hysteroscopic techniques. Paul Smith has received honoraria from Smith and Nephew to present data in office hysteroscopic techniques. Ayesha Mahmud did not report any potential conflicts of interest.

#### References

- 1 Pantaleoni D. On endoscopic examination of the cavity of the womb. *Med Press Circ* 1869;**8**:26–7.
- 2 David J. De l'endoscopie de l'uterus ares avortement et dans es suites de couches a l'etat pathologique. *Bull Soc Obstet* 1907.
- 3 Forestier M, Gladu A, Vulmiere J. Perfectionments de l'endoscope medicale. *Presse Med* 1943;**5**:46–7.
- 4 Hopkins H. On the diffraction theory of optical images. *Proc R Soc Lond* 1953;**217**:408–32.
- 5 Kremer C, Duffy S, Moroney M. Patient satisfaction with outpatient hysteroscopy versus day case hysteroscopy: randomised controlled trial. *BMJ* 2000;**320**:279–82.
- 6 Clark TJ, Bakour SH, Gupta JK, *et al*. Evaluation of outpatient hysteroscopy and ultrasonography in the diagnosis of endometrial disease. *Obstet Gynecol* 2002;**99**:1001–7.
- 7 Clark TJ, Gupta JK. *Handbook of outpatient hysteroscopy: a complete guide to diagnosis and therapy*. CRC Press 2005.
- 8 Clark TJ, Cooper NA, Kremer C. Best practice in outpatient hysteroscopy.

- 9 Cooper NAM, Clark TJ. Cost-effectiveness of diagnostic strategies for the management of abnormal uterine bleeding (heavy menstrual bleeding and postmenopausal bleeding): Systematic reviews, IPD meta-analysis and model based economic evaluation. <http://www.hta.ac.uk/2145> (accessed 27 Sep2013).
- 10 Moawad NS, Santamaria E, Johnson M, *et al.* Cost-effectiveness of office hysteroscopy for abnormal uterine bleeding. *JSLS J Soc Laparoendosc Surg Soc Laparoendosc Surg* 2014;**18**. doi:10.4293/JSLS.2014.00393
- 11 Timmermans A, Opmeer BC, Veersema S, *et al.* Patients' preferences in the evaluation of postmenopausal bleeding. *BJOG Int J Obstet Gynaecol* 2007;**114**:1146–9. doi:10.1111/j.1471-0528.2007.01424.x
- 12 Sweet MG, Schmidt-Dalton TA, Weiss PM, *et al.* Evaluation and management of abnormal uterine bleeding in premenopausal women. *Am Fam Physician* 2012;**85**:35–43.
- 13 CG44 N. *Heavy Menstrual Bleeding. Clinical Guideline No. 44. National Collaborating Centre for Women's and Children's Health Commissioned by the National Institute for Health and Clinical Excellence.* RCOG Press 2007.
- 14 Munro MG, Critchley HOD, Fraser IS. The FIGO systems for nomenclature and classification of causes of abnormal uterine bleeding in the reproductive years: who needs them? *Am J Obstet Gynecol* 2012;**207**:259–65. doi:10.1016/j.ajog.2012.01.046
- 15 Hatasaka H. The evaluation of abnormal uterine bleeding. *Clin Obstet Gynecol* 2005;**48**:258–73.
- 16 Bachmann LM, ter Riet G, Clark TJ, *et al.* Probability analysis for diagnosis of endometrial hyperplasia and cancer in postmenopausal bleeding: an approach for a rational diagnostic workup. *Acta Obstet Gynecol Scand* 2003;**82**:564–9.
- 17 Breitkopf DM, Frederickson RA, Snyder RR. Detection of benign endometrial masses by endometrial stripe measurement in premenopausal women. *Obstet Gynecol* 2004;**104**:120–5. doi:10.1097/01.AOG.0000130065.49187.c8
- 18 Smith PP, O'Connor S, Gupta J, *et al.* Recurrent postmenopausal bleeding: a prospective cohort study. *J Minim Invasive Gynecol* 2014;**21**:799–803. doi:10.1016/j.jmig.2014.03.007
- 19 Gupta JK, Chien PFW, Voit D, *et al.* Ultrasonographic endometrial thickness for diagnosing endometrial pathology in women with postmenopausal bleeding: a meta-analysis. *Acta Obstet Gynecol Scand* 2002;**81**:799–816.
- 20 Smith-Bindman R, Kerlikowske K, Feldstein VA, *et al.* Endovaginal ultrasound to exclude endometrial cancer and other endometrial abnormalities. *JAMA J Am Med Assoc* 1998;**280**:1510–7.

- 21 Dimitraki M, Tsikouras P, Bouchlariotou S, *et al.* Clinical evaluation of women with PMB. Is it always necessary an endometrial biopsy to be performed? A review of the literature. *Arch Gynecol Obstet* 2011;**283**:261–6.  
doi:10.1007/s00404-010-1601-3
- 22 Seshadri S, El-Toukhy T, Douiri A, *et al.* Diagnostic accuracy of saline infusion sonography in the evaluation of uterine cavity abnormalities prior to assisted reproductive techniques: a systematic review and meta-analyses. *Hum Reprod Update* Published Online First: 10 December 2014.  
doi:10.1093/humupd/dmu057
- 23 Gkrozou F, Dimakopoulos G, Vrekoussis T, *et al.* Hysteroscopy in women with abnormal uterine bleeding: a meta-analysis on four major endometrial pathologies. *Arch Gynecol Obstet* Published Online First: 19 December 2014.  
doi:10.1007/s00404-014-3585-x
- 24 NVOG (Dutch Society of Obstetrics and Gynaecology). NVOG Guideline: Abnormal Vaginal Bleeding During the Postmenopause. 1997.
- 25 Scottish Intercollegiate Guidelines Network. Investigation of postmenopausal bleeding 1st edn. 2002.www.sign.ac.uk
- 26 Clark TJ. Outpatient hysteroscopy and ultrasonography in the management of endometrial disease. *Curr Opin Obstet Gynecol* 2004;**16**:305–11.
- 27 Svirsky R, Smorgick N, Rozowski U, *et al.* Can we rely on blind endometrial biopsy for detection of focal intrauterine pathology? *Am J Obstet Gynecol* 2008;**199**:115–e1 – 3.
- 28 Clark TJ, Voit D, Gupta JK, *et al.* Accuracy of hysteroscopy in the diagnosis of endometrial cancer and hyperplasia: a systematic quantitative review. *JAMA J Am Med Assoc* 2002;**288**:1610–21.
- 29 Bakour SH, Khan KS, Gupta JK. The risk of premalignant and malignant pathology in endometrial polyps. *Acta Obstet Gynecol Scand* 2002;**81**:182–3.
- 30 Preutthipan S, Herabutya Y. Hysteroscopic polypectomy in 240 premenopausal and postmenopausal women. *Fertil Steril* 2005;**83**:705–9.  
doi:10.1016/j.fertnstert.2004.08.031
- 31 Annan JJ, Aquilina J, Ball E. The management of endometrial polyps in the 21st century. *Obstet Gynaecol* 2012;**14**:33–8. doi:10.1111/j.1744-4667.2011.00091.x
- 32 Cooper NAM, Clark TJ, Middleton L, *et al.* A randomised trial of outpatient versus inpatient uterine polyp treatment for abnormal uterine bleeding. *BMJ* 2015;**In Print**.

- 33 Smith PP, Middleton LJ, Connor M, *et al.* Hysteroscopic morcellation compared with electrical resection of endometrial polyps: a randomized controlled trial. *Obstet Gynecol* 2014;**123**:745–51. doi:10.1097/AOG.0000000000000187
- 34 Pritts EA, Parker WH, Olive DL. Fibroids and infertility: an updated systematic review of the evidence. *Fertil Steril* 2009;**91**:1215–23. doi:10.1016/j.fertnstert.2008.01.051
- 35 Cooper NAM, Smith P, Khan KS, *et al.* Vaginoscopic approach to outpatient hysteroscopy: a systematic review of the effect on pain. *BJOG Int J Obstet Gynaecol* 2010;**117**:532–9. doi:10.1111/j.1471-0528.2010.02503.x
- 36 Demirel A, Gurgan T. Effect of treatment of intrauterine pathologies with office hysteroscopy in patients with recurrent IVF failure. *Reprod Biomed Online* 2004;**8**:590–4.

Figures legend:

Figure 1: Menstrual disorders affecting women

Figure 2: FIGO Classification of Abnormal uterine bleeding

Figure 1

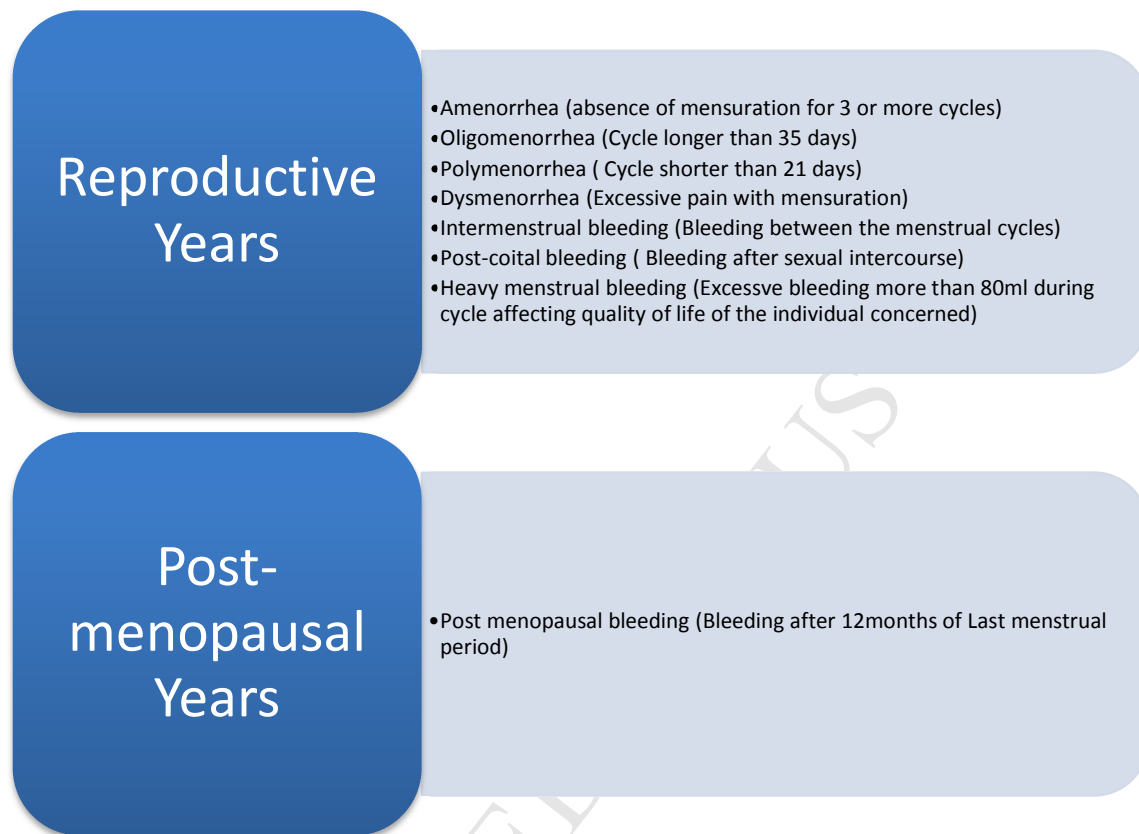


Figure 1: Menstrual disorders affecting women

Figure 2

<b>Structural Causes of AUB (PALM)</b>	<b>Non-Structural causes of AUB (COEIN)</b>
<b>Polyps (Endometrial or cervical)</b>	<b>Coagulopathy</b>
<b>Adenomyosis</b>	<b>Ovulatory dysfunction</b>
<b>Leiomyoma</b>	<b>Endometrial disorder (Primary)</b>
<b>Malignancy and hyperplasia</b>	<b>Iatrogenic</b>
	<b>Not yet classified</b>

Figure 2: FIGO Classification of Abnormal uterine bleeding

**Highlights**

- We examine the role of hysteroscopy in abnormal uterine bleeding.
- Outpatient hysteroscopy is cheaper and safer than procedures performed under anaesthetic.
- Both diagnosis and treatment can be implemented in one consultation ('one-stop' service).
- There is rapid development of technology to increase feasibility of outpatient hysteroscopy.