

Implication of bisphosphonate use in the treatment of SAPHO syndrome: Case report and discussion of current literature

Gorecki, Patricia; Stockmann, Philipp; Distler, Jörg H.w.; Wuest, Wolfgang; Schmidt, Daniela; Neukam, Friedrich Wilhelm; Nkenke, Emeka; Wehrhan, Falk

DOI:

[10.1016/j.jmhi.2015.04.002](https://doi.org/10.1016/j.jmhi.2015.04.002)

License:

Creative Commons: Attribution-NonCommercial-NoDerivs (CC BY-NC-ND)

Document Version

Publisher's PDF, also known as Version of record

Citation for published version (Harvard):

Gorecki, P, Stockmann, P, Distler, JHW, Wuest, W, Schmidt, D, Neukam, FW, Nkenke, E & Wehrhan, F 2015, 'Implication of bisphosphonate use in the treatment of SAPHO syndrome: Case report and discussion of current literature', *Journal of Medical Hypotheses and Ideas*, vol. 9, no. 2, pp. 72-78.
<https://doi.org/10.1016/j.jmhi.2015.04.002>

[Link to publication on Research at Birmingham portal](#)

Publisher Rights Statement:

Published under a Creative Commons Non-Commercial No Derivatives license: <http://creativecommons.org/licenses/by-nc-nd/4.0/>.

Eligibility for repository checked June 2015

General rights

Unless a licence is specified above, all rights (including copyright and moral rights) in this document are retained by the authors and/or the copyright holders. The express permission of the copyright holder must be obtained for any use of this material other than for purposes permitted by law.

- Users may freely distribute the URL that is used to identify this publication.
- Users may download and/or print one copy of the publication from the University of Birmingham research portal for the purpose of private study or non-commercial research.
- User may use extracts from the document in line with the concept of 'fair dealing' under the Copyright, Designs and Patents Act 1988 (?)
- Users may not further distribute the material nor use it for the purposes of commercial gain.

Where a licence is displayed above, please note the terms and conditions of the licence govern your use of this document.

When citing, please reference the published version.

Take down policy

While the University of Birmingham exercises care and attention in making items available there are rare occasions when an item has been uploaded in error or has been deemed to be commercially or otherwise sensitive.

If you believe that this is the case for this document, please contact UBIRA@lists.bham.ac.uk providing details and we will remove access to the work immediately and investigate.



Available online at www.sciencedirect.com

Journal of Medical Hypotheses and Ideas

journal homepage: www.elsevier.com/locate/jmhi



REGULAR ARTICLES

Implication of bisphosphonate use in the treatment of SAPHO syndrome: Case report and discussion of current literature



Patricia Gorecki ^{a,*}, Philipp Stockmann ^b, Jörg H.W. Distler ^c, Wolfgang Wuest ^d, Daniela Schmidt ^e, Friedrich Wilhelm Neukam ^f, Emeka Nkenke ^{b,g}, Falk Wehrhan ^b

^a Department of Oral Surgery, The School of Dentistry, University of Birmingham, UK

^b Department of Oral and Maxillofacial Surgery, University of Erlangen, Germany

^c Department of Rheumatology, University of Erlangen, Germany

^d Department of Radiology, University of Erlangen, Germany

^e Department of Nuclear Medicine, University of Erlangen, Germany

^f Head of Oral and Maxillofacial Surgery Department, University of Erlangen, Germany

^g Head of University Hospital for Cranio, Maxillofacial and Oral Surgery, Medical University of Vienna, Austria

Received 22 October 2014; accepted 18 April 2015

Available online 25 April 2015

KEYWORDS

SAPHO syndrome;
Diffuse sclerosing
osteomyelitis;
Spondyloarthropathy;
Bisphosphonates;
Zoledronate

Abstract Even though increasing knowledge is emerging about synovitis, acne, pustulosis, hyperostosis and osteitis (SAPHO) syndrome its pathogenesis remains enigmatic. Women are preferentially affected by SAPHO syndrome. Here we present the case of a 39-year-old woman suffering from this syndrome whose bone involvement was first interpreted as diffuse sclerosing osteomyelitis of the mandible. As treatment with clindamycin did not improve the symptoms, the decision was made to administer bisphosphonates intravenously. This treatment led to a rapid improvement in symptoms, which could be explained by the apparent tendency of bisphosphonates to exert a positive effect on the jaw. With this case report we attempt to offer an explanation for the influence of this group of medications on patients suffering from SAPHO syndrome with mandibular involvement.

© 2015 Tehran University of Medical Sciences. Published by Elsevier Ltd. This is an open access article under the CC BY-NC-ND license (<http://creativecommons.org/licenses/by-nc-nd/4.0/>).

* Corresponding author at: Department of Oral Surgery, The School of Dentistry, University of Birmingham, St Chad's Queensway, Birmingham B4 6NN, UK. Tel.: +44 1214665496 (work).

E-mail address: p.gorecki@bham.ac.uk (P. Gorecki).



2251-7294 © 2015 Tehran University of Medical Sciences. Published by Elsevier Ltd.

This is an open access article under the CC BY-NC-ND license (<http://creativecommons.org/licenses/by-nc-nd/4.0/>).

URL: www.tums.ac.ir/english/

doi:<http://dx.doi.org/10.1016/j.jmhi.2015.04.002>

Introduction

Synovitis, acne, pustulosis, hyperostosis and osteitis (SAPHO) syndrome was first described by Chamot et al. in 1987 [1]. To date its etiology has remained unknown [2–5] SAPHO syndrome is a rheumatic disease belonging to the group of spondyloarthropathies and combining osteomyelitis, osteitis, arthritis and skin disease [1,5–9]. Its diagnosis can be made with the aid of three diagnostic criteria classified by Kahn et al. [10] (Table 1).

The prevalence of SAPHO syndrome is approximately 1:10,000 and is more likely to occur in females [2,9]. It usually has an early onset, with the first symptoms mainly arising during childhood or young adulthood [2,3,9]: these symptoms manifest themselves as characteristic lesions of the bone, skin and skin appendages [1,3,8–10]. The most commonly affected bones are the clavicle and the sternum, but manifestations can also be seen on long tubular and tarsal bones, as well as the spine and ribs [2,3,8,9]. Involvement of the mandible has also been described in approximately 10% of cases [2,4,9,11]. However, as the bone and skin lesions, like palmoplantar pustulosis, do not necessarily emerge at the same time, making an appropriate diagnosis of the syndrome can be difficult and challenging [9,12].

In addition, the bone lesions can resemble those occurring in chronic recurrent multifocal osteomyelitis [13] or in diffuse sclerosing osteomyelitis of the mandible [13,14], causing SAPHO syndrome to easily be misdiagnosed as nonsuppurative chronic inflammation [14]. In its acute phase, the lesion can be indistinguishable from suppurative osteomyelitis [5,6,12]. Therefore, in both scenarios, patients are treated with antibiotics upon the first instance of the lesion and receive additional surgical therapy, such as decortication and partial resection of the affected bones. This treatment regime does not usually lead to the desired results and does not cure SAPHO syndrome in the long run [5,12,14].

Another group of pharmaceuticals, the nitrogen-containing bisphosphonates, has proved to be effective in easing pain and preventing progression in several recent publications [3,7,14–16]. Nevertheless, as only a limited number of patients suffer from SAPHO syndrome, to our knowledge no clinical long-term follow-up studies with a large patient population have been performed. Hence, no official guideline for drug treatment has been established to date. Recent studies demonstrated a relief of jaw symptoms after affected patients received bisphosphonates [3,7,14], an observation that may offer a possible explanation for the etiology of SAPHO syndrome.

The following case report describes a 39-year-old woman with SAPHO syndrome, which was initially suspected to be a diffuse sclerosing osteomyelitis of the right mandible and was therefore treated with antibiotics at the beginning. With this case report we describe the clinically successful treatment

of a SAPHO patient with bisphosphonates that led to reduction in pain and the accompanying swelling. Due to the localization of the affected tissues and the fast pain relief following administration of this medication, we also outline a possible hypothesis about the mechanism of this positive effect.

Case report

A 39-year-old woman presented at the Oral and Maxillofacial Surgery out-patient department of the University of Erlangen in June 2012 after being referred from the Rheumatology Department. She described a recurring swelling of the right sub- and paramandibular region accompanied by severe pain. Her ability to open her mouth was restricted during these periods. According to the patient, the mandibular pain started the year before, in May 2011 and she made an appointment with her dentist from whom she received an apicectomy of the lower right second premolar and lower right first molar in combination with antibiotic therapy. This treatment was not successful, as the patient had a relapse of symptoms.

The patient was then referred to another dentist, who diagnosed a myopathy and thus commenced with splint therapy. The complaints persisted, which led to her visiting another dentist at the beginning of 2012: the lower right second premolar, the lower right first molar and the lower right second molar were extracted and a bone biopsy was taken from the same region. As bacterial osteomyelitis was suspected, antibiotic therapy with clindamycin (1.2 g per day) was carried out for a month. This regime did not improve the symptoms, and neither did the administration of corticosteroids (30 mg per day, with slow tapering of dosage) for three months. Histological examination of the bone biopsy revealed chronic inflammation signs that were consistent with sterile osteomyelitis. This observation led to her referral to the Rheumatology Department of the University Hospital in Erlangen in June 2012, as the woman was known to have SAPHO syndrome.

The patient indicated that the initial symptoms of SAPHO syndrome arose when she was approximately 12 years of age as skin lesions in the form of palmoplantar psoriasis. A few years later, at the end of her teens, she noticed spinal pain on the left side, which was first thought to be of renal origin. This possibility was excluded by medical tests performed at that time. Approximately 10 years later, at the end of her twenties, the patient started complaining of pain in her sternal region. As a result of the bone manifestations and the palmoplantar lesions, SAPHO syndrome was diagnosed.

The Rheumatology Department referred the patient to our out-patient department in order to exclude any possible dental foci before initiating bisphosphonate therapy. No oral inflammatory or suppurative lesions were diagnosed clinically or radiologically. Two separate orthopantomograms were

Table 1 Diagnostic criteria for SAPHO syndrome according to Khan et al.

Chronic recurrent osteomyelitis	→ Sterile or with presence of <i>Propionibacterium acnes</i> → With or without skin lesions → Possible spine involvement
Acute, subacute or chronic arthritis	→ With any of the following skin lesions: palmoplantar pustulosis, acne or pustular psoriasis
Osteitis	→ With any of the following skin lesions: palmoplantar pustulosis, acne or pustular psoriasis

utilized for assessment. The first orthopantomogram was taken on 22nd November 2011 and showed apical radiolucencies of the lower right first molar and the lower right second premolar (Fig. 1a). A second orthopantomogram taken on 13th June 2012 after the previously described tooth extractions revealed slightly sclerotic extraction sockets in the right mandible (Fig. 1b). A Pain and Thermal Sensitivity Test [17] was performed, which demonstrated normal site-to-site variation in warm and cold sensation detection thresholds between the right and left mandibular nerves.

Since a histopathological examination had already been performed by the patient's dentist, and during our assessment we observed no pathologies clinically or radiologically, there was no indication for surgical intervention at that time. Bone scintigraphy was carried out to identify possible additional bone lesions and magnetic resonance imaging (MRI) was performed. Bone scintigraphy revealed signs of osteitis in the right mandible and in the sternum, as well as sacroiliitis, all of which are typical of SAPHO syndrome (Fig. 2). Fat-saturated T1-weighted MRI of the jaw showed decreased signal intensity, and fat-saturated T2-weighted MRI displayed increased signal intensity in and around the mandible along with an increased contrast medium uptake in the inflamed bone, which was interpreted as bone marrow edema (Fig. 3).

Due to these findings and non-effective antibiotic treatment, we initiated therapy with zoledronic acid, a bisphosphonate. The patient described fever-like symptoms, that lasted for two days and generalized aches and pains for four days after the initial intravenous dose of 5 mg; these are known side effects of bisphosphonate therapy [13,14,18]. After remission of these symptoms, the patient described nearly complete relief of mandibular complaints. One month after the first bisphosphonate administration, no relapse of previous clinical symptoms was observed. In contrast, skin manifestations did not change following bisphosphonate treatment. Follow-up MRI performed three weeks after therapy initiation showed no relevant changes, which was not in accordance with the clinical findings stated above (Fig. 4).

Hypotheses

The etiology of SAPHO syndrome remains unknown [2–4], and as result its treatment is empirical and symptomatic

[3,4,6,9]. Although various case reports have been published, no consensus has been reached concerning guidelines for ideal therapy [2,4,9,14].

First choice treatment includes non-steroidal anti-inflammatory drugs (NSAIDs) and other analgesics [4,6,13]. Unfortunately, their use is accompanied by limited efficacy [4,6,14], and thus other therapeutic agents need to be identified to achieve long-term relief for the affected.

Antibiotics have been tried in various studies. Due to the isolation of *Propionibacterium acnes* in bone biopsies of some SAPHO patients, this treatment option seems to be reasonable [4,6,19–22]. In most cases, antibiotics fail to achieve clinical improvement [4,6,8] and it has thus been assumed that *P. acnes* may act as an antigen that triggers an immunological response and leads to inflammation [4,6,20].

The administration of anti-tumor-necrosis-factor-alpha (anti-TNF-alpha) drugs seems promising. Although a positive effect has been reported in various studies, especially in refractory cases [6,23], their use is rather costly and many side effects have been described, including infections, worsening of heart disease and neuropathies [6,14].

In our case report, we administered another group of medication, bisphosphonates, which have been shown to display less severe side effects. Bisphosphonates are usually administered to patients suffering from various types of cancer, for example of the breast or prostate, to prevent bone metastasis or to patients suffering from osteoporosis. These pharmaceuticals appear to be a logical treatment option for SAPHO patients, as they exert both an anti-osteoclastic effect (by prompting apoptosis of osteoclasts) and an anti-inflammatory effect [3,7,18,24–26]. Osteoclastogenesis is promoted by pro-inflammatory cytokines such as interleukin-1 (IL-1) or tumor-necrosis-factor-alpha (TNF-alpha) by enhancing signaling of receptor activator of the nuclear factor κ B ligand (RANKL) [24–26]. Conversely, bisphosphonates induce an anti-inflammatory response by suppressing these cytokines, which results in less inflammation and decreased pain sensation [3,7,18]. A positive effect on various rheumatological conditions has already been confirmed [3,6,7,18].

Numerous studies have illustrated the impact of bisphosphonates on osteoblasts and osteoclasts by influencing gene function. One of the affected proteins is the neural crest-related and osteoproliferative transcription factor MSX-1, which is

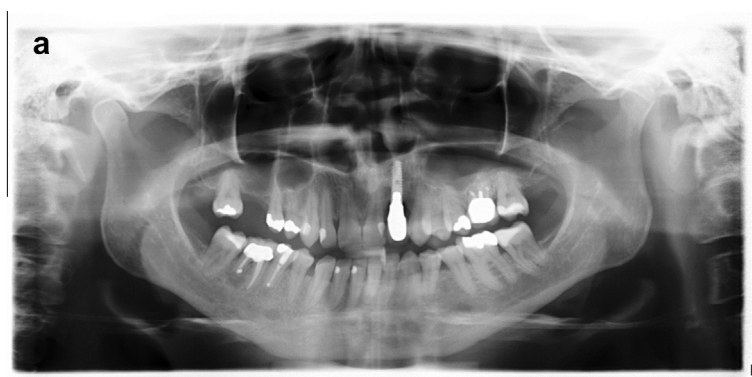

Fig. 1 Images of orthopantomograms performed on 22nd November 2011 (a) and 13th June 2012 (b). (a) The first examination revealed apical radiolucencies of the lower right first molar and the lower right second premolar. (b) The second orthopantomogram showed slightly sclerotic extraction sockets in the right mandible.

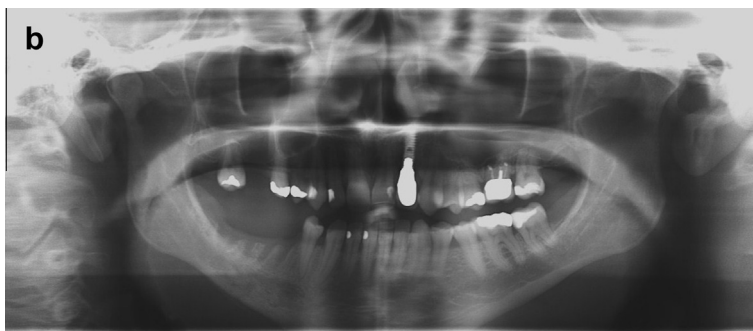

Fig 1. (continued)

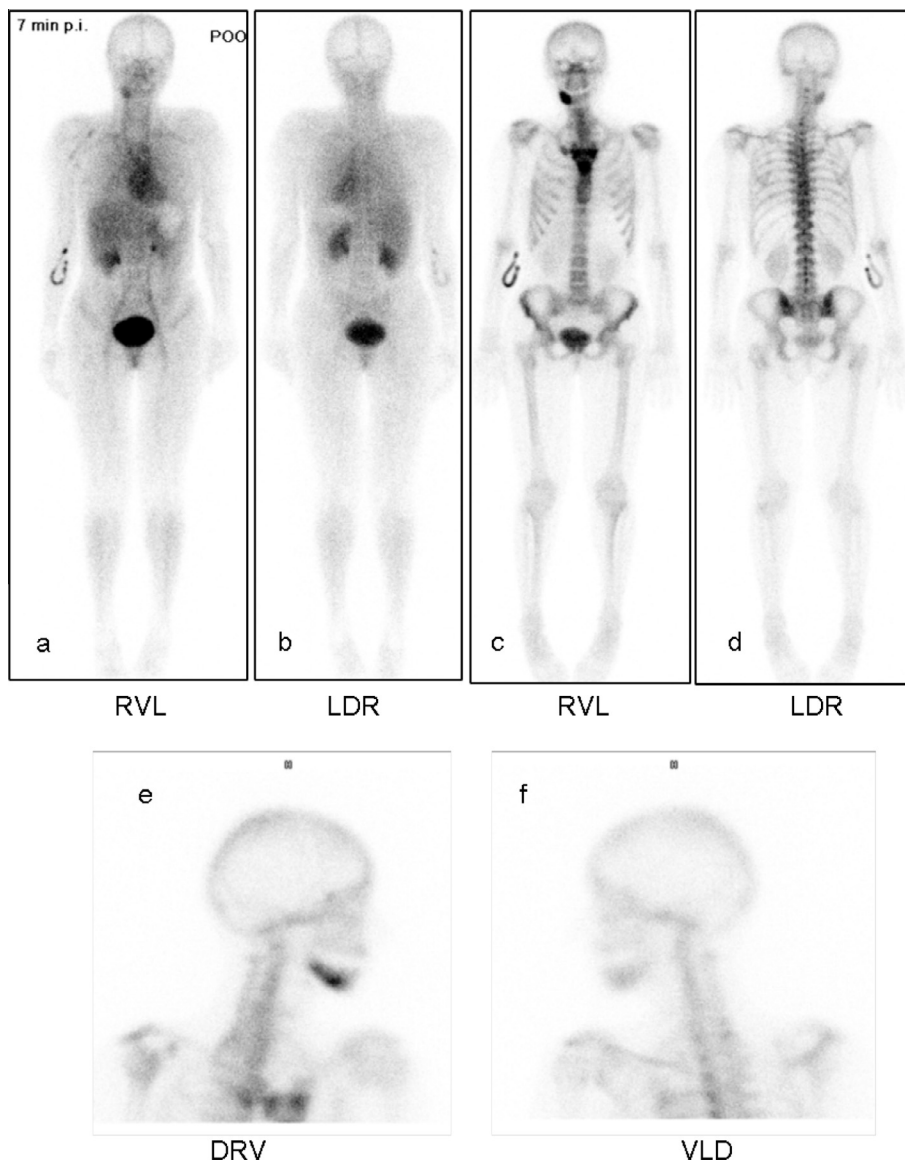


Fig. 2 Bone scintigraphy performed before initiation of treatment with bisphosphonates. Blood pool images of the whole body from ventral (a) and dorsal (b) views and delayed images of the whole body from ventral (c) and dorsal (d) views and of the skull from the left (e) and right (f) confirm signs of osteitis of the sternum, the sternoclavicular (SC) joint and the costosternal joint. These lesions can be interpreted as the so-called “bull head’s sign” and are characteristic of SAPHO syndrome. Highly increased tracer uptake in the right ventrolateral mandibular bone is recognizable, as well as slightly increased tracer uptake in both iliosacral joints.

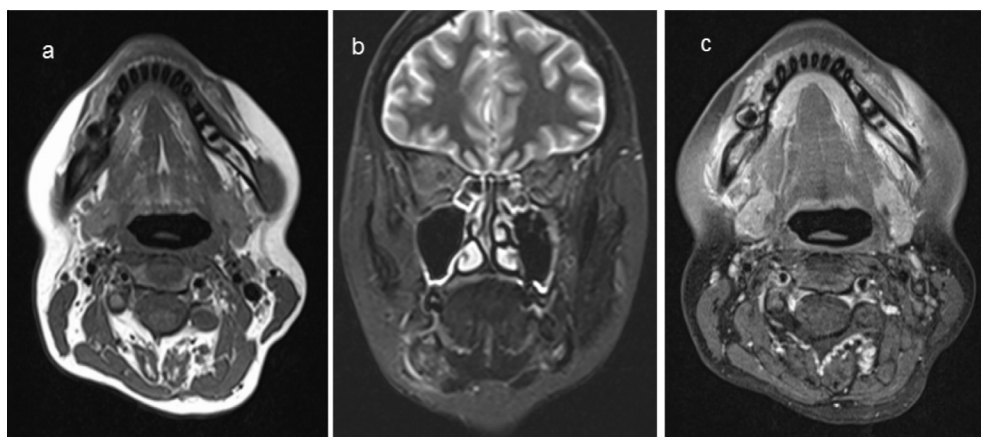


Fig. 3 MRI before initiation of bisphosphonate therapy with zoledronic acid. (a) Native axial T1-weighted MRI before the application of contrast medium. Bone marrow signal, which should be hyperintense on T1w images, exhibited decreased signal intensity in the right mandible compared to the other side. (b) Coronal fat-saturated T2-weighted MRI shows increased signal intensity in the right mandible. (c) Axial fat-saturated T1-weighted MRI after administration of a contrast agent reveals decreased signal intensity in the right mandible due to the application of fat suppression, as well as increased contrast medium uptake in the inflamed bone and the adjacent soft tissue.

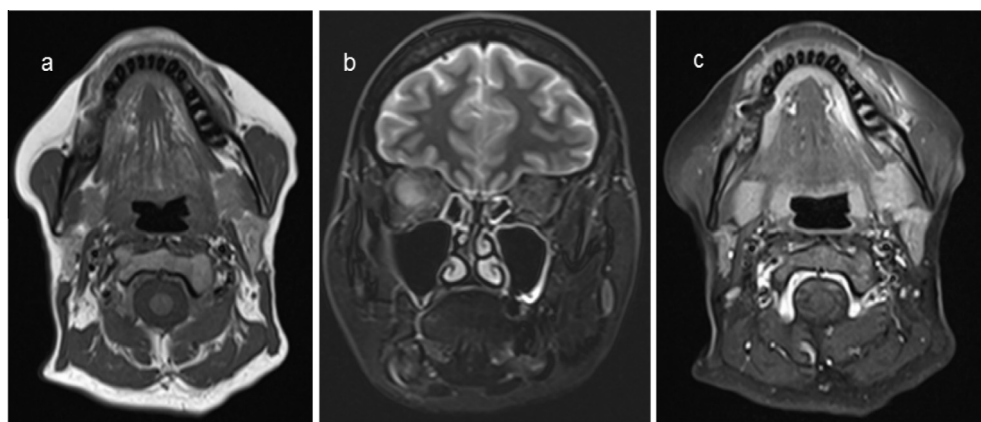


Fig. 4 Follow-up MRI one month after initiation of bisphosphonate therapy with zoledronic acid. (a) Native axial T1-weighted MRI before a contrast agent was applied. Bone marrow signal remained decreased. (b) Coronal fat-saturated T2-weighted MRI indicates increased signal intensity in the right mandible. (c) Axial fat-saturated T1-weighted MRI with contrast agent administration. The slice shows decreased signal intensity in the right mandible due to the application of fat suppression and increased contrast medium uptake in the inflamed bone and the adjacent soft tissue.

involved in the plasticity of neural crest cells and is permanently expressed in the jaw bone [27,28]; in contrast, MSX-1 downregulation in mesenchymal cell-derived tissues has been observed. Temporary reactivation of MSX-1 has been identified, for example during wound healing [15]. Impaired function and decreased expression of MSX-1 were previously demonstrated in tissues of bisphosphonate-related osteonecrosis of the jaw (BRONJ) *in vivo*, providing a possible explanation of why BRONJ is restricted to the jaw bone [27,28].

All tissues affected in SAPHO patients derive from neural crest cells; even the clavicle and the sternum originate partly from neural crest cells [29]. Therefore, bisphosphonates may modulate osteoblasts by influencing MSX-1, among other proteins, and contribute to relief of symptoms by exerting osteogenic effects and increasing bone density. Moreover, the relation between bisphosphonate administration and MSX-1

expression may help to identify a possible explanation for the etiology of SAPHO syndrome. Impaired function of transcription factors like MSX-1 may underlie the appearance of the syndrome and may lead to the identification of additional genes involved in the progress of SAPHO syndrome.

Evaluation of hypotheses

In accordance with this hypothesis, the use of bisphosphonates in SAPHO patients has achieved positive results to date. Amital et al. [7], Kerrison et al. [16], Solau-Gervais et al. [30] and Colina et al. [31] effectively treated patients with pamidronate. Hatano et al. [14] reported a relief of symptoms after administration of risedronate in combination with prednisolone. Kopterides et al. [3] demonstrated a successful therapy with zoledronic acid in a patient with SAPHO syndrome

after antibiotics failed to show success and analgesic agents alone had restricted efficacy.

We chose zoledronic acid for our patient because her SAPHO syndrome was resistant to antibiotic therapy and because zoledronic acid has greater potency and better renal tolerability than pamidronate. Gastrointestinal side effects are also avoided, as zoledronate bypasses the gastrointestinal tract [3,18]. Our case report confirms the conclusion of earlier studies that bisphosphonates are an effective treatment for patients suffering from SAPHO syndrome with mandibular involvement. Fever-like side effects were observed here, but our patient emphasized the reduction of pain in the right lower jaw and the reduction of the associated swelling.

In contrast to our clinical findings and the relief of symptoms described by our patient, no improvement was detected in the follow-up MRI. This lack of change has also been described in earlier studies [13]. Changes in bone density take a longer time to be detectable by MRI, as this method is less sensitive to inflammatory changes. Nonetheless, MRI is a safe and adequate method that causes no exposure to radiation [13].

As our case report concentrates on clinical findings, we selected the follow-up period reported here. This case report emphasizes that rapid and permanent clinical improvement can be achieved by the administration of bisphosphonates to patients with SAPHO syndrome, although this effect did not extend to radiological findings. In order to evaluate the possible etiology proposed in this report, further studies are needed to assess the role of MSX-1 and neural crest-derived tissues in the development of SAPHO syndrome and to clarify its etiology. For this purpose, it should be investigated whether MSX-1-related signaling is involved in tissues affected by SAPHO syndrome.

Conclusion

Drug therapy remains the recommended treatment option for patients with SAPHO syndrome, as surgical intervention has failed to show success and does not automatically lead to a cure of SAPHO syndrome. Apart from analgesic agents, antibiotics and bisphosphonates are the most efficient treatment modalities to date. The latter pharmaceuticals are promising because they have led to the improvement of symptoms in SAPHO patients, especially in mandibular lesions.

The exact mechanism of bisphosphonate function remains unknown. Studies that revealed a link between impaired function of the transcription factor MSX-1 and the development of a BRONJ, may also offer a possible explanation for the appearance of SAPHO syndrome, as the same pathway may be affected. This hypothesis is supported by the observation that tissues affected by SAPHO syndrome originate from the same embryonic structures, the neural crest cells, and administration of bisphosphonates results in the relief of symptoms in affected tissues. This hypothesis needs to be validated by further studies to identify the underlying causes of the condition. The identification of new and more accurate therapeutic options in addition to antibiotics and bisphosphonates may reveal a more precise approach for treating patients suffering from SAPHO syndrome.

Overview Box

First Question: What do we already know about the subject?

The synovitis, acne, pustulosis, hyperostosis and osteitis (SAPHO) syndrome belongs to the group of rheumatic diseases and involves lesions of the bone, skin and skin appendages. Its pathogenesis remains unknown up to the present day, but bisphosphonates seem to influence the syndrome's progression positively.

Second Question: What does your proposed theory add to the current knowledge available, and what benefits does it have?

The hypothesis presented in this paper proposes a potential explanation for the yet unidentified etiology of SAPHO syndrome. Impaired function of transcription factors like MSX-1 could play a crucial role in its development and bisphosphonates might improve symptoms by modulating their response.

Third Question: Among numerous available studies, what special further study is proposed for testing the idea?

As the prevalence of SAPHO syndrome is estimated to be only 1:10,000, no clinical trials with a significant amount of patients have been carried out. Hence both *in vitro* and *in vivo* studies are key to investigate the proposed hypothesis further.

Conflict of interest

There is nothing to disclose.

References

- [1] Chamot AM, Benhamou CL, Kahn MF, Beranek L, Kaplan G, Prost A. L syndrome acne pustulose hyperostose osteite (SAPHO). Resultats d'une enquete nationale; 85 observations. *Rev Rhum Mal Osteoartic* 1987;54:187–96.
- [2] Reichardt LF, Pitak-Arnnop P, Hemprich A, Dhanuthai K, Pausch NC. Chronic refractory osteomyelitis as a part of synovitis, acne, pustulosis, hyperostosis and osteitis (SAPHO) syndrome: a diagnostic challenge. *ANZ J Surg* 2011;81(9):642–3.
- [3] Kopterides P, Pikazis D, Koufos C. Successful treatment of SAPHO syndrome with zoledronic acid. *Arthritis Rheum* 2004;50(9):2970–3.
- [4] Zemann W, Pau M, Feichtinger M, Ferra-Matschy B, Kaercher H. SAPHO syndrome with affection of the mandible: diagnosis, treatment, and review of literature. *Oral Surg Oral Med Oral Pathol Oral Radiol Endod* 2011;111(2):190–5.
- [5] Matzaroglou Ch, Velissaris D, Karageorgos A, Marangos M, Panagiotopoulos E, Karanikolas M. SAPHO syndrome diagnosis and treatment: report of five cases and review of the literature. *Open Orthop J* 2009;5(3):100–6.
- [6] Olivieri I, Padula A, Palazzi C. Pharmacological management of SAPHO syndrome. *Expert Opin Invest Drugs* 2006;15(10):1229–33.
- [7] Amital H, Applbaum YH, Aamar S, Daniel N, Rubinow A. SAPHO syndrome treated with pamidronate: an open-label study of 10 patients. *Rheumatology (Oxford)* 2004;43(5):658–61.

- [8] Boutin RD, Resnick D. The SAPHO syndrome: an evolving concept for unifying several idiopathic disorders of bone and skin. *Am J Roentgenol* 1998;170(3):585–91.
- [9] Mochizuki Y, Omura K, Hirai H, Kugimoto T, Osako T, Taguchi T. Chronic mandibular osteomyelitis with suspected underlying synovitis, acne, pustulosis, hyperostosis, and osteitis (SAPHO) syndrome: a case report. *J Inflamm Res* 2012;5:29–35.
- [10] Kahn MF, Khan MA. The SAPHO syndrome. *Baillieres Clin Rheumatol* 1994;8(2):333–62.
- [11] Hayem G, Bouchaud-Chabot A, Benali K, Roux S, Palazzo E, Silbermann-Hoffman O, et al. SAPHO syndrome: a long-term follow-up study of 120 cases. *Semin Arthritis Rheum* 1999;29(3):159–71.
- [12] Swei Y, Taguchi A, Tanimoto K. Diagnostic points and possible origin of osteomyelitis in synovitis, acne, pustulosis, hyperostosis and osteitis (SAPHO) syndrome: a radiographic study of 77 mandibular osteomyelitis cases. *Rheumatology (Oxford)* 2003;42(11):1398–403.
- [13] Compeyrot-Lacassagne S, Rosenberg AM, Babyn P, Laxer RM. Pamidronate treatment of chronic noninfectious inflammatory lesions of the mandible in children. *J Rheumatol* 2007;34(7):1585–9.
- [14] Hatano H, Shigeishi H, Higashikawa K, Shimasue H, Nishi H, Oiwa H, et al. A case of SAPHO syndrome with diffuse sclerosing osteomyelitis of the mandible treated successfully with prednisolone and bisphosphonate. *J Oral Maxillofac Surg* 2012;70(3):626–31.
- [15] Orestes-Cardoso S, Nefussi JR, Lezot F, Oboeuf M, Pereira M, Mesbah M, et al. *Msx1* is a regulator of bone formation during development and postnatal growth: *in vivo* investigation in a transgenic mouse model. *Connect Tissue Res* 2002;43(2–3):153–60.
- [16] Kerrison C, Davidson JE, Cleary AG, Beresford MW. Pamidronate in the treatment of childhood SAPHO syndrome. *Rheumatology (Oxford)* 2004;43(10):1246–51.
- [17] Schultze-Mosgau S, Reich RH. Assessment of inferior alveolar and lingual nerve disturbances after dentoalveolar surgery, and of recovery of sensitivity. *Int J Oral Maxillofac Surg* 1993; 22(4):214–7.
- [18] Hamdy RC. Zoledronic acid: clinical utility and patient considerations in osteoporosis and low bone mass. *Drug Des Dev Ther* 2010;18(4):321–35.
- [19] Kirchhoff T, Merkesdal S, Rosenthal H, Prokop M, Chavan A, Wagner A, et al. Diagnostic management of patients with SAPHO syndrome: use of MR imaging to guide bone biopsy at CT for microbiological and histological work-up. *Eur Radiol* 2003;13(10):2304–8.
- [20] Colina M, Lo Monaco A, Khodeir M, Trotta F. *Propionibacterium acnes* and SAPHO syndrome: a case report and literature review. *Clin Exp Rheumatol* 2007;25:457–60.
- [21] Assmann G, Kueck O, Kirchhoff T, Rosenthal H, Voswinkel J, Pfreundschuh M, et al. Efficacy of antibiotic therapy for SAPHO syndrome is lost after its discontinuation: an interventional study. *Arthritis Res Ther* 2009;11(5):R140.
- [22] Roldán JC, Terheyden H, Dunsche A, Kampen WU, Schroeder JO. Acne with chronic recurrent multifocal osteomyelitis involving the mandible as part of the SAPHO syndrome: case report. *Br J Oral Maxillofac Surg* 2001;39(2):141–4.
- [23] Ben Abdelghani K, Dran DG, Gottenberg JE, Morel J, Sibilia J, Combe B. Tumor necrosis factor-alpha blockers in SAPHO syndrome. *J Rheumatol* 2010;37(8):1699–704.
- [24] Karmakar S, Kay J, Gravalles EM. Bone damage in rheumatoid arthritis: mechanistic insights and approaches to prevention. *Rheum Dis Clin North Am* 2010;36(2):385–404.
- [25] Moon SJ, Ahn IE, Jung H, Yi H, Kim J, Kim Y, et al. Temporal differential effects of proinflammatory cytokines on osteoclastogenesis. *Int J Mol Med* 2013;31(4):769–77.
- [26] Geusens P. The role of RANK ligand/osteoprotegerin in rheumatoid arthritis. *Ther Adv Musculoskelet Dis* 2012;4(4):225–33.
- [27] Wehrhan F, Hyckel P, Ries J, Stockmann P, Nkenke E, Schlegel KA, et al. Expression of *Msx-1* is suppressed in bisphosphonate associated osteonecrosis related jaw tissue-etiology considerations respecting jaw developmental biology-related unique features. *J Transl Med* 2010;13(8):96.
- [28] Wehrhan F, Hyckel P, Amann K, Ries J, Stockmann P, Schlegel K, et al. *Msx-1* is suppressed in bisphosphonate-exposed jaw bone analysis of bone turnover-related cell signalling after bisphosphonate treatment. *Oral Dis* 2011;17(4):433–42.
- [29] Rodríguez-Vázquez JF, Verdugo-López S, Garrido JM, Murakami G, Kim JH. Morphogenesis of the manubrium of sternum in human embryos: a new concept. *Anat Rec (Hoboken)* 2013;296(2):279–89.
- [30] Solau-Gervais E, Soubrier M, Gerot I, Grange L, Puechal X, Sordet C, et al. The usefulness of bone remodelling markers in predicting the efficacy of pamidronate treatment in SAPHO syndrome. *Rheumatology (Oxford)* 2006;45(3):339–42.
- [31] Colina M, La Corte R, Trotta F. Sustained remission of SAPHO syndrome with pamidronate: a follow-up of fourteen cases and a review of the literature. *Clin Exp Rheumatol* 2009;27(1):112–5.