

Human tuberculosis predates domestication in ancient Syria

Baker, Oussama; Lee, Oona Y.-c.; Wu, Houdini H.t.; Besra, Gurdyal S.; Minnikin, David E.; Llewellyn, Gareth; Williams, Christopher M.; Maixner, Frank; O'sullivan, Niall; Zink, Albert; Chamel, Bérénice; Khawam, Rima; Coqueugniot, Eric; Helmer, Daniel; Mort, Françoise L.e.; Perrin, Pascale; Gourichon, Lionel; Dutailly, Bruno; Pálfi, György; Coqueugniot, Hélène

DOI:

[10.1016/j.tube.2015.02.001](https://doi.org/10.1016/j.tube.2015.02.001)

License:

Other (please specify with Rights Statement)

Document Version

Peer reviewed version

Citation for published version (Harvard):

Baker, O, Lee, OY, Wu, HHT, Besra, GS, Minnikin, DE, Llewellyn, G, Williams, CM, Maixner, F, O'sullivan, N, Zink, A, Chamel, B, Khawam, R, Coqueugniot, E, Helmer, D, Mort, FLE, Perrin, P, Gourichon, L, Dutailly, B, Pálfi, G, Coqueugniot, H & Dutour, O 2015, 'Human tuberculosis predates domestication in ancient Syria', *Tuberculosis*, vol. 95, no. Supplement 1, pp. S4-12. <https://doi.org/10.1016/j.tube.2015.02.001>

[Link to publication on Research at Birmingham portal](#)

Publisher Rights Statement:

NOTICE: this is the author's version of a work that was accepted for publication in *Tuberculosis*. Changes resulting from the publishing process, such as peer review, editing, corrections, structural formatting, and other quality control mechanisms may not be reflected in this document. Changes may have been made to this work since it was submitted for publication. A definitive version was subsequently published in *Tuberculosis*, DOI: 10.1016/j.tube.2015.02.001.

Eligibility for repository checked April 2015

General rights

Unless a licence is specified above, all rights (including copyright and moral rights) in this document are retained by the authors and/or the copyright holders. The express permission of the copyright holder must be obtained for any use of this material other than for purposes permitted by law.

- Users may freely distribute the URL that is used to identify this publication.
- Users may download and/or print one copy of the publication from the University of Birmingham research portal for the purpose of private study or non-commercial research.
- User may use extracts from the document in line with the concept of 'fair dealing' under the Copyright, Designs and Patents Act 1988 (?)
- Users may not further distribute the material nor use it for the purposes of commercial gain.

Where a licence is displayed above, please note the terms and conditions of the licence govern your use of this document.

When citing, please reference the published version.

Take down policy


While the University of Birmingham exercises care and attention in making items available there are rare occasions when an item has been uploaded in error or has been deemed to be commercially or otherwise sensitive.

If you believe that this is the case for this document, please contact UBIRA@lists.bham.ac.uk providing details and we will remove access to the work immediately and investigate.

Accepted Manuscript

Human tuberculosis predates domestication in ancient Syria

Oussama Baker, Oona Y-C. Lee, Houdini HT. Wu, Gurdyal S. Besra, David E. Minnikin, Gareth Llewellyn, Christopher M. Williams, Frank Maixner, Niall O'Sullivan, Albert Zink, Bérénice Chamel, Rima Khawam, Eric Coqueugniot, Daniel Helmer, Françoise LE. Mort, Pascale Perrin, Lionel Gourichon, Bruno Dutailly, György Pálfi, Hélène Coqueugniot, Olivier Dutour, Prof.



PII: S1472-9792(15)00002-5

DOI: [10.1016/j.tube.2015.02.001](https://doi.org/10.1016/j.tube.2015.02.001)

Reference: YTUBE 1262

To appear in: *Tuberculosis*

Please cite this article as: Baker O, Lee OY-C, Wu HH, Besra GS, Minnikin DE, Llewellyn G, Williams CM, Maixner F, O'Sullivan N, Zink A, Chamel B, Khawam R, Coqueugniot E, Helmer D, Mort FL, Perrin P, Gourichon L, Dutailly B, Pálfi G, Coqueugniot H, Dutour O, Human tuberculosis predates domestication in ancient Syria, *Tuberculosis* (2015), doi: 10.1016/j.tube.2015.02.001.

This is a PDF file of an unedited manuscript that has been accepted for publication. As a service to our customers we are providing this early version of the manuscript. The manuscript will undergo copyediting, typesetting, and review of the resulting proof before it is published in its final form. Please note that during the production process errors may be discovered which could affect the content, and all legal disclaimers that apply to the journal pertain.

Title page**Title: Human tuberculosis predates domestication in ancient Syria****Author names and affiliations:**

Oussama BAKER^a, Oona Y-C LEE^b, Houdini HT WU^b, Gurdyal S BESRA^b, David E MINNIKIN^b, Gareth LLEWELLYN^c, Christopher M WILLIAMS^c, Frank MAIXNER^d, Niall O'SULLIVAN^d, Albert ZINK^d, Bérénice CHAMEL^e, Rima KHAWAM^e, Eric COQUEUGNIOT^e, Daniel HELMER^e, Françoise LE MORT^e, Pascale PERRIN^f, Lionel GOURICHON^g, Bruno DUTAILLY^h, György PÁLFIⁱ, Hélène COQUEUGNIOT^{h,j}, Olivier DUTOUR^{a,h,k (*)}

^a Laboratoire d'Anthropologie biologique Paul Broca, Ecole Pratique des Hautes Etudes, Paris, France.

^b Institute of Microbiology and Infection, School of Biosciences, University of Birmingham, B15 2TT Birmingham, UK

^c National Mass Spectrometry Service Centre, School of Medicine, Grove Building, Swansea University, Swansea, UK

^d Institute for Mummies and the Iceman, European Academy - Viale Druso, 1 39100 Bolzano - Italy

^e Laboratoire Archéorient (UMR 5133, CNRS – Université de Lyon 2), Maison de l'Orient et de la Méditerranée- Jean Pouilloux, 7 rue Raulin - 69365 LYON cedex 7 - France

^f Université Montpellier 2- MIVEGEC IRD/UR 224 – CNRS/UMR 5290, MIVEGEC - Centre IRD de Montpellier, 911 Avenue Agropolis, BP 64501, 34394 Montpellier cedex 5 - France

^g Cultures et Environnements Préhistoire, Antiquité, Moyen Âge (CEPAM - UMR 7264, CNRS Université Nice Sophia Antipolis), Pôle Universitaire Saint-Jean-d'Angély (SJA3) - 24 avenue des Diables Bleus - 06357 Nice Cedex 4 - France.

^h De la Préhistoire à l'Actuel : Culture, Environnement, Anthropologie (PACEA - UMR 5199, CNRS - Université de Bordeaux - Ministère de la Culture et de la Communication). Allée Geoffroy St Hilaire - CS 50023 - 33615 Pessac cedex, France

ⁱ Department of Biological Anthropology, University of Szeged, Dugonics Ter, Szeged, Hungary.

^j Department of Human Evolution, Max Planck Institute for Evolutionary Anthropology, Deutscher Platz 6, 04103 Leipzig, Germany.

^k Department of Anthropology, University of Western Ontario, London, Canada.

*corresponding author:

Prof. Olivier Dutour

Laboratoire d'Anthropologie biologique Paul Broca - Ecole Pratique des Hautes Etudes, UMR PACEA - CNRS - Université de Bordeaux

Allée Geoffroy St Hilaire - CS 50023 - 33615 PESSAC cedex, France

Phone: +33540008931

Fax: +33540002545

E-mail: olivier.dutour@ephe.sorbonne.fr

Summary:

The question of pre-neolithic tuberculosis is still open in paleopathological perspective. One of the major interests is to explore what type of infection could have existed around the early stage of animal domestication. Paleopathological lesions evoking skeletal TB were observed on five human skeletons coming from two PPNB sites in Syria, which belongs to the geographical cradle of agriculture. These sites represent respectively pre-domestication phase (Dja'de el Mughara, Northern Syria, 8800-8300 BCE cal.) and early domestication phase (Tell Aswad, Southern Syria, 8200-7600 BCE cal.). MicroCT scan analyses were performed on two specimens (one per site) and revealed microscopic changes in favour of TB infection. Detection of lipid biomarkers is positive for two specimens (one per site). Initial molecular analysis further indicates the presence of TB in one individual from Dja'de. Interestingly, no morphological evidence of TB was observed on animal remains of wild and newly domesticated species, discovered in these sites. These observations strongly suggest the presence of human tuberculosis before domestication and at its early stages.

Keywords: paleopathology of TB, Early Neolithic, PPNB, agriculture cradle, domestication, lipid biomarkers, ancient DNA

Introduction:

Human tuberculosis is a specific disease caused by infection by a member of *Mycobacterium tuberculosis* complex. Although the previous widely accepted hypothesis that the human pathogen (*M. tuberculosis*) derived from cattle pathogen (*M. bovis*) by contamination during the Neolithic, the new evolutionary scenario assess that *M. tuberculosis* actually represents a direct descendant of a most ancient strain that existed before the split of *M. africanum* - *M. bovis* lineages from the *M. tuberculosis* lineage¹. This suggests that the tubercle bacilli could have been already a human pathogen before animal domestication.

Paleopathological evidence of tuberculosis before the Neolithic is poorly documented. Lesions observed on extinct bison remains discovered in a natural trap

cave in Wyoming and dated from 17000 BP, led to biomolecular identification of *M. tuberculosis* ancient DNA and lipid biomarkers ². A diagnosis of leptomenigitis tuberculosa was mentioned about endocranial lesions observed on a fossil hominin attributed to *Homo erectus* from Turkey ³, but this hypothesis was questioned by other authors ⁴. As for human tuberculosis, most ancient cases are dated from 7000 yrs BCE in the Eastern Mediterranean. In the site of Atlit Yam, remains of an adult female and an immature individual presented paleopathological evidence of TB, confirmed by lipid biomarkers and aDNA analyses ⁵. In the same geographic area, paleopathological evidences of tuberculosis were previously mentioned for contemporaneous site (Ain Ghazal, ca. 7250 BCE) ⁶. These cases correspond to the development of the first farming and herding societies in the Fertile Crescent, known to be the cradle of agriculture.

In order to explore the link between human and cattle tuberculosis at the beginning of domestication process, the first purpose of this study is to investigate the paleopathological evidence of tuberculosis from two ancient Neolithic sites representing pre and early domestication phases in ancient Syria. This study will allow shedding further light on the debate concerning the origins and the evolutionary pathway of the *Mycobacterium tuberculosis* complex, for example by dating the emergence of the modern strain of *M. tuberculosis*.

Materials and methods:

Archaeological material

Studied material is coming from two Pre-Pottery Neolithic B (PPNB) sites from Syria, Dja'de el Mughara and Tell Aswad.

The pre-domestic Neolithic site of Dja'de el Mughara is located on the left bank of the Euphrates River, about 115 Km N/W from Aleppo. It has been excavated from 1991 to 2010 in the framework of the French Archaeological Research Program in Syria, headed by Eric Coqueugniot ⁷. The chronology of the human occupation ranged from 9310 to 8200 BCE cal. It has been divided in 3 chrono-cultural periods. The first one (DJ 1) corresponds to the end of PPNA, transition phase to early PPNB (9310-8830 BCE cal.). Human remains associated to this period are scarce: only five individuals

were discovered, represented by four adult skulls and a fragmentary skeleton of an adolescent. The second period (DJ 2) corresponds to early PPNB and is dated from 8800 to 8500 BCE cal. Human settlement is represented by 13 burials that provided skeletal remains of 26 individuals (8 immature individuals and 18 adults). The third period (DJ 3), corresponding to the end of early PPNB, is dated from 8540 to 8290 BCE cal. Human remains associated to this period are more numerous: 99 individuals were identified (37 adult and 62 immature individuals). More than 70 are coming from collective burials (Houses of the Dead). After 8200 BCE, the site was abandoned till the 7th millennium.

During this period, people still rely on hunting and gathering. Indeed, the wild resources were still dominating the diet, and there is no morphological evidence that either cereals or animals were domesticated. At the "DJ 3" phase, however, some clues of pre-domestication could be recognized, both for plants (wild cereals) and animals (aurochs)^{7, 8}.

For this site, skeletal remains of 130 individuals were examined by two researchers of this study (OB and BC).

The Neolithic site of Tell Aswad located around 35 Km from East / Southeast Damascus (Southern Syria) has been discovered in 1967 by H. de Contenson, and excavations were performed between 2001 and 2006 by a French-Syrian archeological team co-headed by Danielle Stordeur and Bassam Jammous⁹.

Numerous skeletal remains were discovered, representing 119 individuals, dating from middle and end of PPNB (8200-7600 BCE cal). The domestic resources have been strongly used since the middle PPNB: cereals are derived from an agricultural economy, and exploitation of domestic animals increases in this period, while hunting decreases.

Methods

Anthropology and paleopathology

All the skeletal material was carefully examined in the storage place on site, both for anthropological and paleopathological purposes. Possible changes due to TB were systematically researched on spine, bones and joints. Diagnostic was based upon

the morphology and distribution of the lesions according to criteria commonly accepted in clinical and paleopathological literature¹⁰⁻¹³; including aspects of spondylodiscitis, osteoarthritis and periostitis. Age estimation and sex determination of the immature and adult individuals were performed according to a set of different methods currently used in biological anthropology¹⁴⁻¹⁶.

The skeletal pieces matching with these criteria were selected and analysed by different methods. Morphological methods have used digital imaging acquisitions by laser and X-ray (μ CT) with volumetric reconstructions. Lipidic biomarkers were detected by HPLC¹⁷ and MTBC specific sequence motifs were targeted by ancient DNA based analysis.

In the same time, animal bones found in these sites (wild and domesticated species) were studied by two researchers of this study (DH and LG). No paleopathological lesion was observed. A sample of 9 cattle bones from Dja'de el Mughara was selected for further analyses (lipid biomarkers and ancient DNA).

Digital imaging

Lesions present on 2 thoracic vertebrae of individual Dja'de 304 were digitalized by 3D laser scan at low energy (class II), without contact at a mean resolution lower than 0.5mm. Contrarily to X-rays, this surface laser acquisition allows saving morphological information before sampling for molecular analysis while protecting ancient DNA from ionization. Moreover, it allows the 3D printing of the lesions by rapid prototyping (Eden250™ 3D Printing System, Objet, with horizontal layers of 16 μ m) using VIRCOPAL® technology¹⁸.

Two specimens were analysed by microtomodensitometry: distal ulna of individual Aswad 509 on a GE Healthcare eXplore Locus microCT at a resolution of 20 μ m and lumbar vertebra of young immature individual Dja'de B108 on a GE V/tome/x at 3 μ m. 3D reconstructions were performed using TIVMI® software program¹⁹.

Lipid extraction

Analyses were performed on 2 specimens presenting paleopathological lesions (Dja'de sp483 and Tell Aswad 509). The Dja'de skeleton sp483 provided 14 vertebrae (Laboratory Numbers DV1 to DV14) and 36 rib (Laboratory Numbers DR1 to DR36) samples for study. Eleven fibula fragments were available from Tell Aswad skeleton 509 (Laboratory Numbers AF1 to AF11). Bone samples AF1 (548 mg), AF3

(573 mg), AF11 (473 mg), DR13 (256 mg), DR36 (316 mg), DV7 (214 mg) and DV13 (70 mg) were chosen for lipid biomarker analysis. Specimens were hydrolysed by heating with 30% potassium hydroxide in methanol (2 ml) and toluene (1 ml) at 100°C overnight²⁰. In parallel, standard biomass from *Mycobacterium tuberculosis* was processed. Long-chain compounds were extracted as described previously²⁰ and the extract was treated with pentafluorobenzyl bromide, under phase-transfer conditions²⁰, to convert acidic components into pentafluorobenzyl (PFB) esters. Subsequent separation on an Alltech 209250 (500 mg) normal phase silica gel cartridge gave fractions containing non-hydroxylated fatty acid PFB esters, mycolic acid (MA) PFB esters²⁰. The MA PFB esters were reacted with pyrenebutyric acid (PBA) to produce PBA-PFB MA derivatives, which were purified on an Alltech 205250 (500 mg) C₁₈ reverse phase cartridge²⁰. The PBA-PFB mycolates were analysed by reverse phase HPLC, as described previously²⁰. The non-hydroxylated PFB ester fractions were refined on an Alltech 205250 (500mg) reverse phase silica gel cartridge, using a water-methanol/methanol/methanol-toluene elution sequence²⁰. A fraction enriched in mycocerosic acid and other longer chain (> C₂₀) PFB esters was eluted by 100% methanol with the more usual C₁₂ to C₂₀ esters eluting in the earlier water/methanol fractions. The fractions containing possible mycolipenate and mycocerosates, were analysed by negative ion chemical ionization gas chromatography mass spectrometry (NICI-GCMS), essentially as previously described²⁰. Technical details of the GC-MS analyses are provided in Supplementary Information.

Ancient DNA analysis

Molecular analyses were conducted at the ancient DNA laboratory of the EURAC Institute for Mummies and the Iceman, Bolzano, Italy. Sample preparation and DNA extraction was performed in a dedicated pre-PCR area following the strict procedures required for studies of ancient DNA: use of protective clothing, UV-light exposure of the equipment and bleach sterilization of surfaces, use of PCR workstations and filtered pipette tips. Within a designated sample preparation room the outer surface of the bone samples was mechanically removed by using a Dremel speed rotary tool. The surfaces of hard tissue material were subsequently subjected to an 15min UV treatment. Finally, the cleaned samples were pulverized using a Retsch mixer mill (25

Hz, 15 sec). A complete list of the bone samples used for molecular analysis is provided in the Table 1.

DNA extraction was performed with approximately 250 mg of tissue powder using a silica-based DNA extraction described by Rohland et al.²¹ with minor modifications. Different primer combinations were used to initially check for the presence of human mitochondrial DNA and to further diagnose TB²². Details of the PCR conditions and to the oligonucleotide primers used in this study are provided in Supplementary Information. The obtained PCR products were separated by electrophoresis on a 2.85 % agarose gel and visualized on a UV-screen after staining with ethidium bromide. The nucleotide sequences of the PCR products were determined by direct sequencing. The PCR products of amplification were checked and purified (EXO-SAP treatments) and four microliters of the PCR amplification cleaned-product were sequenced on an ABI Prism 310 DNA automated sequencer, using the BigDye™ Terminator Cycle Sequencing Ready Reaction Kit version 3.1 (Applied Biosystems, Foster City, CA, USA). Primers used for the sequencing were the same as those used for the PCRs. Results were subjected to sequence analysis via NCBI blastN²³.

Results

Paleopathology

Dja'de el Mughara site

Among the skeletal remains of the site representing a total of 135 individuals, 4 individuals showed paleopathological lesions that are consistent with a diagnosis of skeletal tuberculosis.

Two cases are attributed to the early stage of PPNB, "DJ 2" (8800-8500 BCE cal.)

The first specimen (sp483) is an immature individual of about 1 year old at death (determination based on dental maturation stage). The individual was buried in a rectangular structure against a wall, in a primary flexed position. The structure is dated from the "DJ 2b" phase, an initial stage of the early PPNB, which is only known at Dja'de el Mughara. The skeleton is fragmented, mainly represented by fragmented skull (frontal, occipital, parietal bones); 19 vertebrae (unfused); fragmented clavicae, humerii, ulnae, radii, right femora, tibia and fibula, incomplete metatarsal

and foot phalanges. The lesions are represented by symmetrical periosteal reaction on long bones of upper limbs, characterized by thin unilamellar layer of woven bone 'appliqué' on the diaphyseal shafts.

On the anterior part of the vertebral bodies, besides an enlargement of the vascular foramina (anterior venous plexuses) a periosteal reaction is also visible. Similar pattern has been described at the end of the 19th century as a special expression of spine TB infection, which differed from Pott's disease^{24, 25}.

The skeleton sp675 belonged to 8-10 years old individual (determination based on dental maturation and epiphyseal fusion stages) who was primarily buried half-lying down, half-seated in a narrow pit. The burial had no direct link with architecture, but according to the stratigraphic level the skeleton can be dated to the "DJ 2" phase. The skeleton is represented by fragmented skull (mainly facial bones), quite well preserved clavicae, humeri, radii, ulnae, femora, tibiae, fragmented fibulae, incomplete numbers of hand and foot short and tubular bones. Lesions are represented by a periosteal reaction on both ulnae and tibiae, having the same global pattern (symmetrical, woven bone, 'appliqué') but thinner than for the previous case.

A periosteal reaction is clearly visible on the internal side of 3 preserved ribs, that has been presented as a paleopathological marker of TB²⁶. Several vertebral bodies present the same pathological pattern on their anterior part (enlargement of the venous foramina, periosteal reaction) than those described for the young immature sp483.

Two other cases are attributed to "DJ 3" phase (8540-8290 BCE cal.).

The first case came from the 304 collective grave, which was not fully excavated, as a large part was situated in the baulk. The minimal number of individuals represented in this burial is of 5 individuals, 3 adults and 2 immature individuals (4-6 years and 10-14 years old at time of death). The individual which exhibits typical lesions of vertebral TB infection is one of the 3 adults. Sex determination was not possible due to the poor preservation of coxal bones. Due to the collective nature of the burial and mixing of skeletal elements, it was not possible to associate precisely the spine of this individual with the rest of the skeleton, as the skeletons of the 3 adults were mingled. The axial skeleton is represented by vertebrae from T2 to L4, sacrum and fragments of the two coxal bones. Therefore, sex determination is not possible, but small marginal osteophytosis present from 4th to 8th vertebrae can help in age estimation, indicating that this spine belonged to an adult individual. Typical lesions

are present on the 9th and 10th thoracic vertebrae (figure 1a). They are mainly lytic. The inferior part of the 9th thoracic vertebrae is completely destroyed, and the upper part of the 10th thoracic vertebrae shows cystic rounded cavitations expanded to the vertebral body, having a space occupying mass aspect (figure 1b). Due to the lack of any changes in the facet joints, it does not seem that vertebral collapse did occur, in spite of the important lytic destruction of the two vertebral bodies. The cavity was probably occupied by a renitent TB granulomatous mass that therefore offered a biomechanical protection against collapse. This aspect matches with criteria of cystic aspect of spinal TB ^{27, 28}

Using 3D reconstruction from laser surface acquisition, it has been possible to reassemble precisely the zygapophyseal joints and thus to get a more precise view of the spinal static. Indeed, it seems that the vertebrae did not collapse in spite of the importance of the destruction of the vertebral bodies, which is confirming the existence of a space occupying mass (such as a granulomatous cyst) that has probably protected the thoracic spine from crush. This pattern is not commonly described in modern clinical practice, but can be seen by medical imaging on living patients ²⁹ and mummified bodies ²⁸ and has been clearly identified on skeletal material ²⁷, related to tuberculosis of spine.

The second case is labelled B108, coming from a collective burial containing 16 individuals. The skeleton, in good preservation state, is almost complete, excepting the lower limbs that are missing. Dental maturation stage indicated the individual died at an age of about 4-5 years. Lesions were tiny, located on 7th to 12th thoracic vertebrae and on the first 3 preserved lumbar vertebrae. The global pattern is characterized by a slight periosteal reaction on the anterior part of the vertebral body that is developed around the anterior venous plexus foraminae. This aspect can matches with an early stage of superficial vertebral tuberculosis ²⁵.

Tell Aswad site

Among the hundred individuals excavated in this site, we examined 25 skeletons older than 15 years. The rest of the individuals are represented by young immature individuals and adult plastered skulls.

The skeleton 509 coming from an individual burial dated from the Middle PPNB period (8200-7600 BCE cal.) is well preserved, excepting the axial skeleton (spine, pelvic bones and ribs) that is vanished. Age estimation from the physal fusion indicated a result of 20-22 years old with a Bayesian probability of 97% ¹⁵. Long and tubular bones (humerii, radii, ulnae, metacarpal, femorae, tibiae, fibulae, metatarsals) exhibited a striking pattern of symmetrical diffuse periosteal reaction, made of thin layers of woven bone (figure 2b). The distal part of the right ulna is swollen. The symmetrical periosteal reaction involving long and short tubular bones is characteristic of Hypertrophic Pulmonary Osteoarthropathy (HPOA), syndrome that is due to chronic pulmonary disease, including TB ³⁰. TB is here the much probable aetiology, due to the young age of this individual, rather than a malignant process that mainly concern elderly people.

MicroCT

The first specimen is the vertebra of the young immature Dja'de B108. In contrast with minor morphological changes, the 3D reconstruction evidenced clear focal microarchitectural changes on the antero-lateral inner part of the body, when it is sectioned along a horizontal axis. These lesions can be interpreted as the first step of the process of tubercular infection of spine corresponding to a hematogenous spread via lateral equatorial branches of the vertebral artery (for detailed description and illustration, see Coqueugniot et al, this volume) ²⁸.

The second specimen is the ulna of the individual 509 from Tell Aswad. Slices revealed a paucilamellar periosteal reaction, with an "appliqué" aspect. The cortical bone showed an increasing of the porosities predominant on the endosteal side. The cortical bone showed an increasing of the porosities predominant on the endosteal side. The 3D reconstruction (figure 2b) revealed that the reorganization on the endosteal side (looking like a kind of medullar expansion into the cortical bone) corresponds to a probable myelitis, with spread of the infection to the cortical bone through the vascular canals. Moreover, 3D viewing showed some communications between these dilated channels and the space localized under the periosteal reaction. This aspect is typical of the one of osteomyelitis ¹⁰. Given the fact that the periosteal reaction is diffuse on all long bones and tubular bones of this individual, only tuberculosis can be responsible of this diffuse skeletal infection.

Lipid biomarkers

Profiles of total mycolic acids are shown in Figure 3 and mycocerosate/mycolipenate profiles are in Figure 4. The reverse phase HPLC profiles of total mycolates (Figure 3) were relatively weak for the Dja'de specimens, particularly DV13; correspondence with the total mycolates from standard *M. tuberculosis* was imprecise. The Tell Aswad extracts were essentially negative, with some unknown earlier eluting material (10 – 15 minutes). Owing to the low abundance of these mycolates, it was not productive to examine these extracts by sequential normal and reverse phase HPLC, a procedure that can provide additional high quality diagnostic information²⁰.

The mycocerosate/mycolipenate profiles in Figure 4, were more informative for both the Dja'de and Aswad specimens. In the case of the Dja'de 483 vertebra (DV13), clear peaks were recorded for C₃₀ and C₃₂ mycocerosates and C₂₇ mycolipenate, but the same signals were weaker for DR13. Another Dja'de 483 rib sample (DR36) also provided clear C₂₉, C₃₀ and C₃₂ mycocerosates but C₂₇ mycolipenate was not detected. Mycolipenate and mycocerosates were not found in extracts of DV7. The three Aswad 509 fibula samples (AF1, AF3 and AF11) had strong peaks for C₂₇ mycolipenate. Aswad 509 AF1 and AF3 had weak C₃₀ and C₃₂ mycocerosate signals, but only C₃₂ mycocerosate was recorded for AF11.

Ancient DNA

Molecular paleomicrobiological analysis was used to diagnose MTBC bacteria in selected specimens. Four of the five individuals displaying paleopathological lesions indicative for TB were subjected to further molecular analysis. If possible, both one long bone section and one pathological bone section (rib and vertebra) was analysed. Initially, the analysis of a short fragment of the human mtDNA hypervariable region 1 indicated a poor overall preservation of DNA in the human skeletal remains. Only in three of the nine analysed bone samples, human mtDNA was detected via PCR (Table 1). The presence of TB DNA was assessed by applying a nested PCR-based assay targeting the MTBC multicopy IS6110 region^{31, 32}. Within the nine bone samples analysed in this study two specimens of individual 483 of the Dja'de site showed positive molecular results for MTBC pathogens. An IS6110 123 bp product from the rib (DR36) and a 92 bp nested IS6110 product from the vertebra (DV8) and rib (DR36) sample were obtained and confirmed by sequencing.

Discussion:

Paleopathological results are strongly suggestive of tubercular infection for two individuals: Dja'de 304 which showed typical Pott's disease and Aswad 509 which presented a diffuse periosteal reaction characteristic of HPOA. MicroCT analyses with 3D reconstruction revealed a typical pattern of osteomyelitis. Moreover, microarchitectural changes of trabecular vertebral bone observed on the young child Dja'de_108B keenly supports the hypothesis of early stage of tubercular spondylitis. Mycolic acid profiles did not give clear diagnoses for tuberculosis (Figure 3). Some consistent, but poorly shaped, peaks were seen for DR13, DR36 and DV7 specimens from Dja'de 483, but the DV13 trace was uninformative. It is likely that the mycolates are substantially degraded. The Aswad 509 profiles had negligible evidence for mycobacterial mycolic acids, but AF1, AF3 and AF11 consistently had substantial amounts of early eluting peaks whose rather uniform profiles suggested a non-microbial origin (Figure 3).

In the Aswad 509 individual, the tuberculosis-specific C_{27} mycolipenic acid biomarker was prominent in the three fibula cases AF1, AF3 and AF11 (Figure 2; C_{27} m/z 407). This positive diagnosis was backed up by the presence of small but clearly positive C_{32} (m/z 479) mycocerosates in all cases and additional C_{30} (m/z 451) mycocerosates in extracts of AF1 and AF3 (Figure 4). Taken together, these data confirm tuberculosis in Aswad 509. In contrast, Dja'de 483 specimens displayed a different balance of mycolipenate and mycocerosic biomarkers with nice clear signals for C_{30} (m/z 451) and C_{32} (m/z 479) mycocerosates, backed up with smaller peaks representing C_{27} mycolipenate (m/z 407) (Figure 2). Again, tuberculosis is confirmed in individual Dja'de 483 for both rib (DR13, DR36) and vertebra (DV13) samples. The lipid biomarker profiles, recorded here, resemble those recorded for the 17,000 year old bison, where mycolic acids were very degraded but diagnostic mycolipenates and mycocerosates were present²⁰.

Ancient DNA first results evidenced the presence of typical IS6110 product for one individual of Dja'de 483 (young child), confirming the morphological diagnosis of early stage of vertebral tubercular infection, in accordance with the lipid biomarkers. These pluridisciplinary observations strongly suggest the presence of human tuberculosis

before domestication and at its early stages. Further molecular studies on this material will improve our knowledge about the evolution of *Mycobacterium tuberculosis* complex, particularly as they can determine when emerged the modern strain of bacilli responsible for human tuberculosis.

Acknowledgments

First author is supported by French Ministry of Foreign Affairs and this research has been partially granted by Réseau Universités – Institut Français du Proche Orient (IFPO) and by the interdisciplinary CNRS research program MIE : Humans and pathogens: a long co-evolution. First author is grateful to Danielle Stordeur, emeritus CNRS Research Director and to Michel al-Maqdiss, Director of Excavations for DGAM-Syria for their precious help and assistance.

For lipid biomarkers, the study was supported by Leverhulme Trust Project Grant F/00 094/BL (GSB, DEM, OY-CL). Mass spectrometry was carried out at the UK Engineering and Physical Sciences Research Council (EPSRC) funded National Mass Spectrometry Facility National Mass Spectrometry Facility at Swansea University, UK. GSB has a James Bardrick Personal Research Chair and a Royal Society Wolfson Research Merit Award.

For the ancient DNA analysis, this study is supported in part by the Südtiroler Sparkasse and the South Tyrolean grant legge 14 (FM, NOS, AZ).

References:

1. Brosch R, Gordon SV, Marmiesse M, Brodin P, Buchrieser C, Eiglmeier K, Garnier T, Gutierrez C, Hewinson G, Kremer K, Parsons LM, Pym AS, Samper S, van Soolingen D, Cole ST. A new evolutionary scenario for the *Mycobacterium tuberculosis* complex. *Proc Natl Acad Sci U S A* 2002;**99**:3684-9.
2. Rothschild BM, Martin LD, Lev G, Bercovier H, Bar-Gal GK, Greenblatt C, Donoghue H, Spigelman M, Brittain D. *Mycobacterium tuberculosis* complex DNA from an extinct bison dated 17,000 years before the present. *Clin Infect Dis* 2001;**33**:305-11.
3. Kappelman J, Alcicek MC, Kazanci N, Schultz M, Ozkul M, Sen S. First *Homo erectus* from Turkey and implications for migrations into temperate Eurasia. *Am J Phys Anthropol* 2008;**135**:110-6.
4. Roberts CA, Pfister LA, Mays S. Letter to the editor: was tuberculosis present in *Homo erectus* in Turkey? *Am J Phys Anthropol* 2009;**139**:442-4.
5. Hershkovitz I, Donoghue HD, Minnikin DE, Besra GS, Lee OY, Germaey AM, Galili E, Eshed V, Greenblatt CL, Lemma E, Bar-Gal GK, Spigelman M. Detection and molecular

- characterization of 9,000-year-old Mycobacterium tuberculosis from a Neolithic settlement in the Eastern Mediterranean. *PLoS One* 2008;**3**:e3426.
6. El-Najjar M, Al-Sarie I, Al-Shiyab A. Cases of tuberculosis at 'Ain Ghazal, Jordan. *Paléorient* 1996;**22**:123 - 8.
 7. Coqueugniot E. Dja'de (Syrie), un village à la veille de la domestication (seconde moitié du IXe millénaire av. J.-C.). In: Guilaine J, editor. *Premiers paysans du monde Naissances des agricultures*. Paris Editions Errance, collection Espérides, 2000. p. 61-79.
 8. Helmer D, Gourichon L, Monchot H, Peters J, Saña Seguí M. Identifying early domestic cattle from Pre-Pottery Neolithic sites on the Middle Euphrates using sexual dimorphism. In: Vigne J-D, Peters J, Helmer D, editors. *New methods and the first steps of mammal domestication*. Oxford: Oxbow Books, 2005. p. 86-95.
 9. Stordeur D. Des crânes surmodelés à Tell Aswad de Damascène (PPNB-Syrie) *Paléorient* 2003;**29**:109–15.
 10. Resnick D, Niwayama G. *Diagnosis of Bone and Joint Disorders*. 4th ed. Philadelphia: Saunders, 2002.
 11. Aufderheide A, Rodriguez-Martin C. *The Cambridge encyclopaedia of human palaeopathology*. Cambridge: Cambridge University Press, 1998.
 12. Ortner D, Putschar W. *Identification of pathological conditions in human skeletal remains*. Washington DC: Smithsonian Institution Press, 1981.
 13. Steinbock R. *Palaeopathological diagnosis and interpretation*. Springfield, Illinois: Charles C. Thomas, 1976.
 14. Ubelaker D. *Human Skeletal Remains. Excavation, Analysis, Interpretation*. Taraxacum, 1999.
 15. Coqueugniot H, Weaver TD, Houet F. Brief communication: a probabilistic approach to age estimation from infracranial sequences of maturation. *Am J Phys Anthropol* 2010;**142**:655-64.
 16. Murail P, Bruzek J, Houët F, Cunha E. DSP: a tool for probabilistic sex diagnosis using worldwide variability in hip-bone measurements. *Bulletins et Mémoires de la Société d'Anthropologie de Paris* 2005;**17**:167-76.
 17. Minnikin DE, Bolton RC, Hartmann S, Besra GS, Jenkins PA, Mallet AI, Wilkins E, Lawson AM, Ridell M. An integrated procedure for the direct detection of characteristic lipids in tuberculosis patients. *Ann Soc Belg Med Trop* 1993;**73 Suppl 1**:13-24.
 18. Coqueugniot H, Desbarats P, Dutailly B, Dutour O. Procédé de modélisation d'une pièce formée de tissu osseux. *Brevet français*, 2011.
 19. Dutailly B, Coqueugniot H, Desbarats P, Gueorguieva S, Synave R. 3D surface reconstruction using HMH algorithm. In: IEEE, editor. *Proceedings International Conference on Image Processing Image Processing (ICIP)*, 2009. p. 2505-8.
 20. Lee OY, Wu HH, Donoghue HD, Spigelman M, Greenblatt CL, Bull ID, Rothschild BM, Martin LD, Minnikin DE, Besra GS. Mycobacterium tuberculosis complex lipid virulence factors preserved in the 17,000-year-old skeleton of an extinct bison, *Bison antiquus*. *PLoS One*;7:e41923.
 21. Rohland N, Siedel H, Hofreiter M. A rapid column-based ancient DNA extraction method for increased sample throughput. *Mol Ecol Resour*;10:677-83.
 22. Haak W, Forster P, Bramanti B, Matsumura S, Brandt G, Tanzer M, Villems R, Renfrew C, Gronenborn D, Alt KW, Burger J. Ancient DNA from the first European farmers in 7500-year-old Neolithic sites. *Science* 2005;**310**:1016-8.
 23. Altschul SF, Madden TL, Schaffer AA, Zhang J, Zhang Z, Miller W, Lipman DJ. Gapped BLAST and PSI-BLAST: a new generation of protein database search programs. *Nucleic Acids Res* 1997;**25**:3389-402.
 24. Ménard V, Lannelongue A. *Tuberculose vertébrale; Asselin et Houzeau*. Paris, 1888.

25. Dutour O. Archaeology of Human Pathogens: Palaeopathological Appraisal of Palaeoepidemiology. In: Raoult D, Drancourt M, editors. *Paleomicrobiology: Past Human Infections*. Heidelberg: Springer-Verlag Berlin, 2008.
26. Santos AL, Roberts CA. Anatomy of a serial killer: Differential diagnosis of tuberculosis based on rib lesions of adult individuals from the Coimbra identified skeletal collection. *American journal of physical anthropology* 2006;**130** 38-49.
27. Pálfi G, Bereczki Z, Ortner DJ, Dutour O. Juvenile cases of skeletal tuberculosis from the Terry Anatomical Collection (Smithsonian Institution, Washington, D.C., USA). *Acta Biol Szeged* 2012;**56**:1-12.
28. Coqueugnot H, Dutailly B, Desbarats P, Boulestin B, Pap I, Zikossy I, Baker O, Montaudon M, Panuel M, Karlinger K, Kovács B, Kristóf LA, Pálfi G, Dutour O. Three-dimensional imaging of past skeletal TB: from lesion to process. *Tuberculosis*, this volume.
29. Baba H, Tagami A, Adachi S, Hiura T, Osaki M. Tuberculosis affecting multiple vertebral bodies. *Asian Spine J*;7:222-6.
30. Masson M, Molnar E, Donoghue HD, Besra GS, Minnikin DE, Wu HH, Lee OY, Bull ID, Palfi G. Osteological and biomolecular evidence of a 7000-year-old case of hypertrophic pulmonary osteopathy secondary to tuberculosis from neolithic Hungary. *PLoS One*;8:e78252.
31. Taylor GM, Crossey M, Saldanha J, Waldron T. DNA from *Mycobacterium tuberculosis* identified in mediaeval human skeletal remains using polymerase chain reaction. *J Archaeol Sci* 1996;**23**:789-98.
32. Eisenach KD, Cave MD, Bates JH, Crawford JT. Polymerase chain reaction amplification of a repetitive DNA sequence specific for *Mycobacterium tuberculosis*. *J Infect Dis* 1990;**161**:977-81.

List of figures

Figure 1a: Spinal involvement of individual Dja'de 304 showing antemortem destruction of the body of 9th & 10th thoracic vertebrae.

Figure 1b: Reconstruction of laser surface acquisition of the typical aspect of vertebral tuberculosis observed on the 9th and 10th thoracic vertebrae of individual Dja'de 304.

The cavity was probably occupied by a renitent TB granulomatous mass (pseudo-eosinophilic granuloma) that therefore offered a biomechanical protection against collapse. This aspect matches with criteria of cystic aspect of spinal TB.

Figure 2a: Symmetrical diffuse periosteal reaction observed on long bones of the individual 509 from Tell Aswad (a-humerus; b- right radius & ulna ; c- left radius & ulna ; d- right tibia ; g- left tibia ; e- fragment of left coxal bone ; f- left third metatarsal bone). This paleopathological aspect is in favour of a diagnosis of hypertrophic pulmonary osteoarthropathy.

Figure 2b: 3D reconstruction of microCT (resolution 20 μ) of the ulna of the individual 509 from Tell Aswad.

Various 3D reconstruction A: semi-transparent, longitudinal sections; B: transparent longitudinal section; C: transparent, horizontal sections, are clearly revealing: 1- the reorganization on the endosteal side (aspect of medullar expansion into the cortical bone) 2- dilated channels communicating with the space localized under the periosteal reaction 3- periosteal reaction.

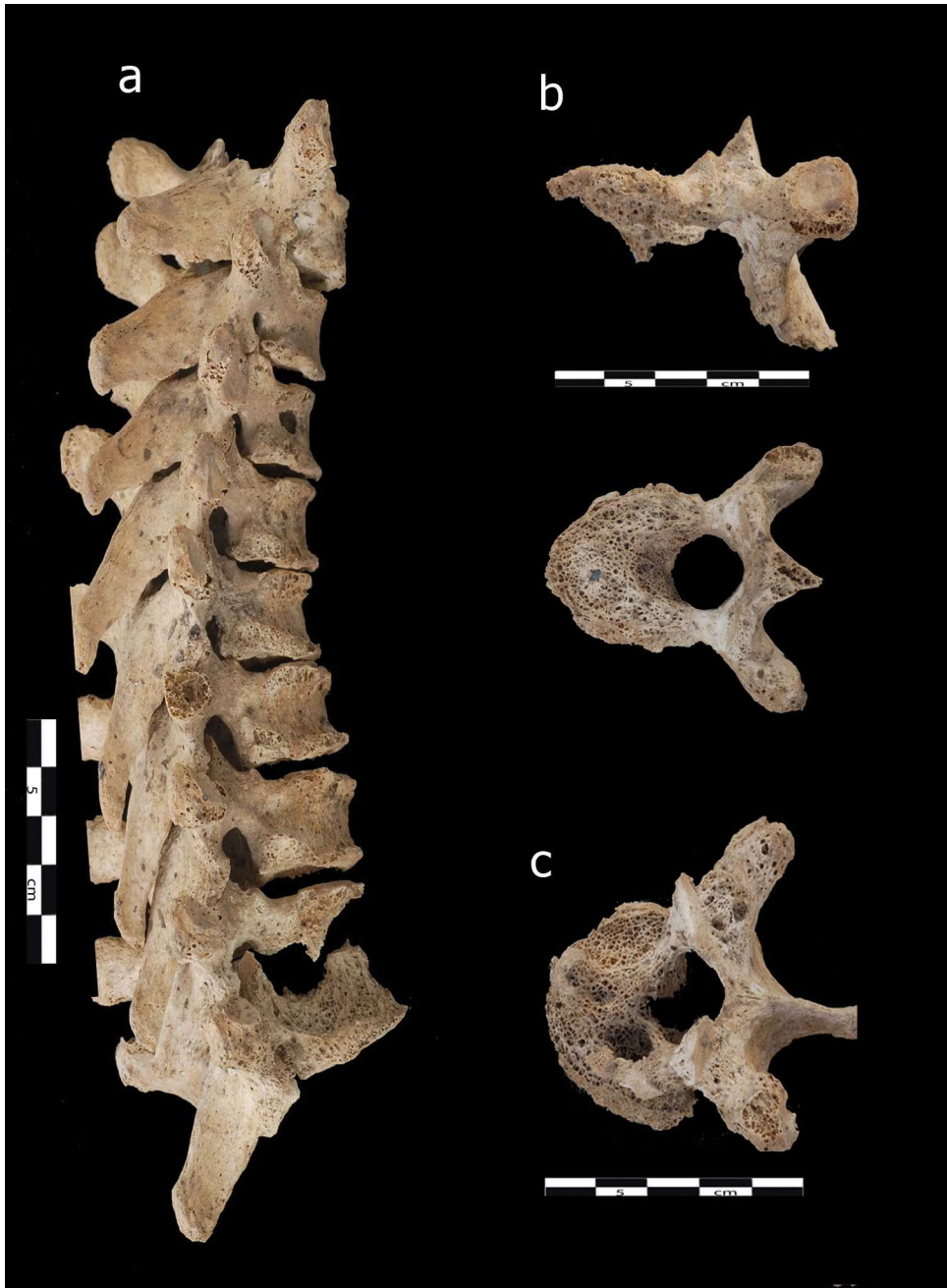This aspect corresponds to a initial myelitis, with secondary spread of the infection to the cortical bone and subperiosteal space through the cortical vascular canals.

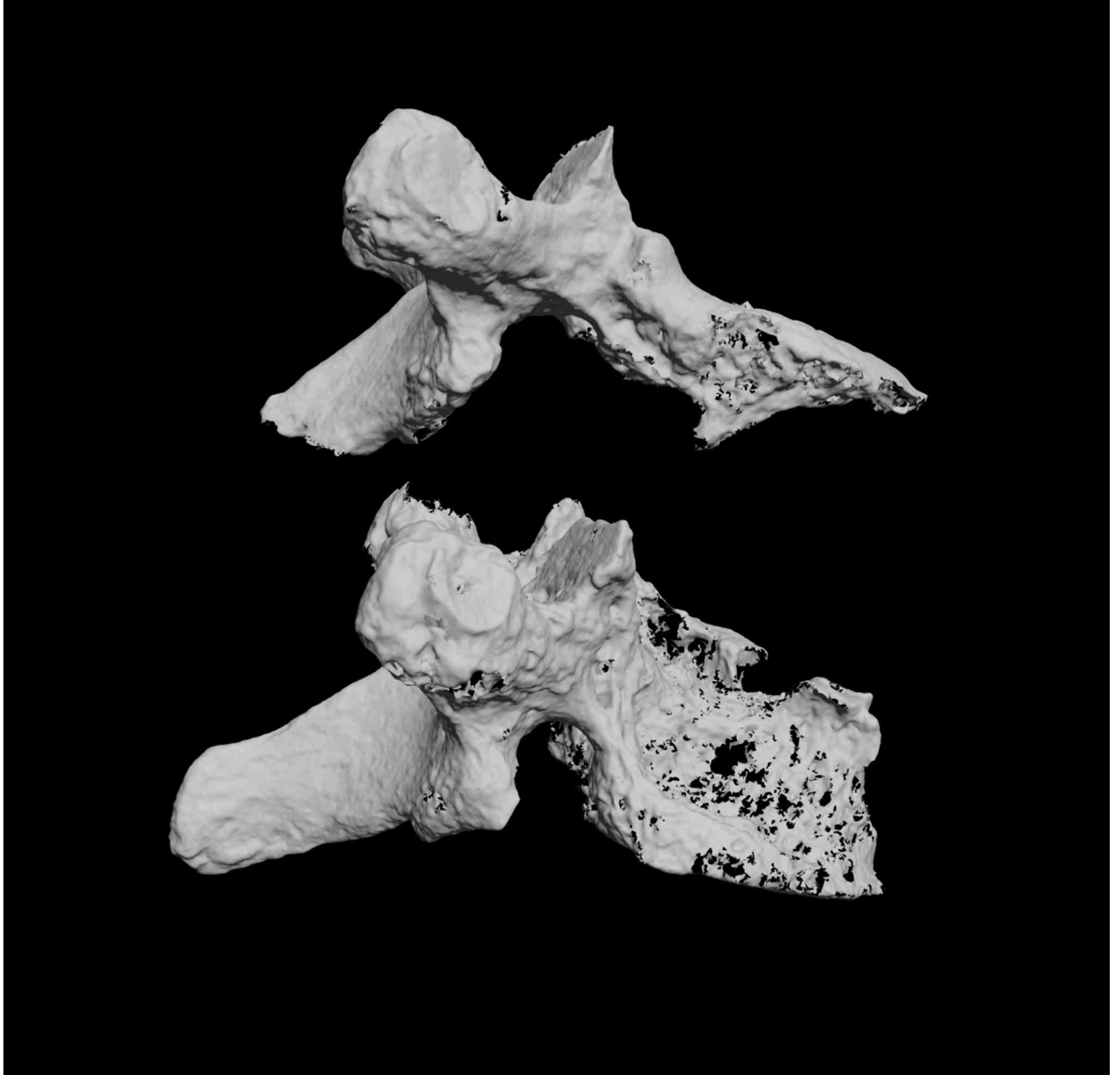
Figure 3: Mycolates profiles

Figure 4 : Mycocerosates profiles

Table 1: Summary of the morphological, chemical and molecular analyses of the sampled bone material of Dja'de and Tell Aswad (5 individuals).


Site	Phase	Period	Individual	Age	Paleopathology	3D imaging and microCT	Sample type	Mycolate	Lipid biomarkers		Sample type	mtDNA	IS6110	IS6110 intern
									Mycocerosates	Mycolipenate				
Dja'de	DJ III	Early PPNB	B108	4-5 yrs	Superficial anterior vertebral changes	Early stage of spondylitis								
	DJ III	Early PPNB	304	Adult	Spinal tuberculosis	Cystic vertebral tuberculosis					Sacrum fragments	+	-	-
	DJ II	Early PPNB	675	8-10 yrs	Diffuse periosteal reaction						Tibia, right, fragments	-	-	-
	DJ II	Early PPNB	483	1yr	Superficial anterior vertebral changes		Vertebra (DV13)	weak	C30(+++) C32(+++)	C27(+++)	Humerus, right fragment	-	-	-
										Vertebra (DV4)	+	-	-	
										Vertebra (DV8)	-	-	+	
Rib (DR36)							weak	C29 C30(++) C32(+++)	-	Rib (DR36)	+	+	+	
Aswad	Middle	Middle PPNB	509	20-22 yrs	Hypertrophic osteoarthropathy	Osteomyelitis (ulna)					Fibula, left fragment	-	-	-
							Fibula (AF1)	-	weak C30, C32	C27(+++)	Fibula (AF1)	-	-	-
							Fibula (AF11)	-	weak C32	C27(+++)	Fibula (AF11)	-	-	-



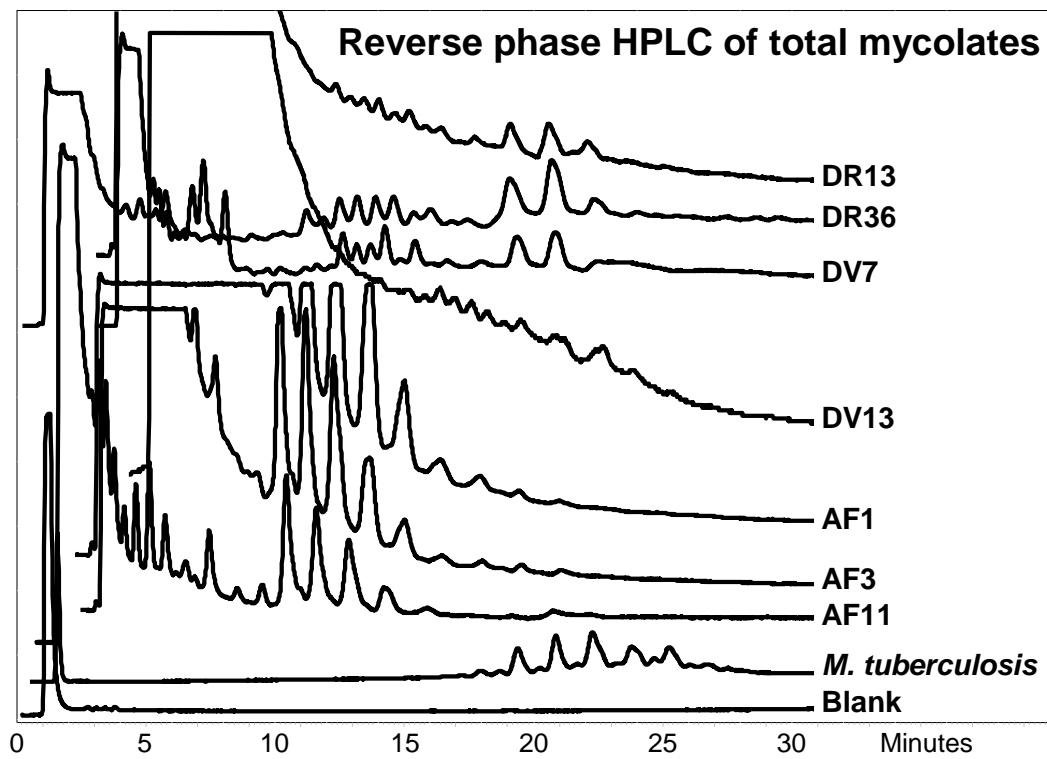


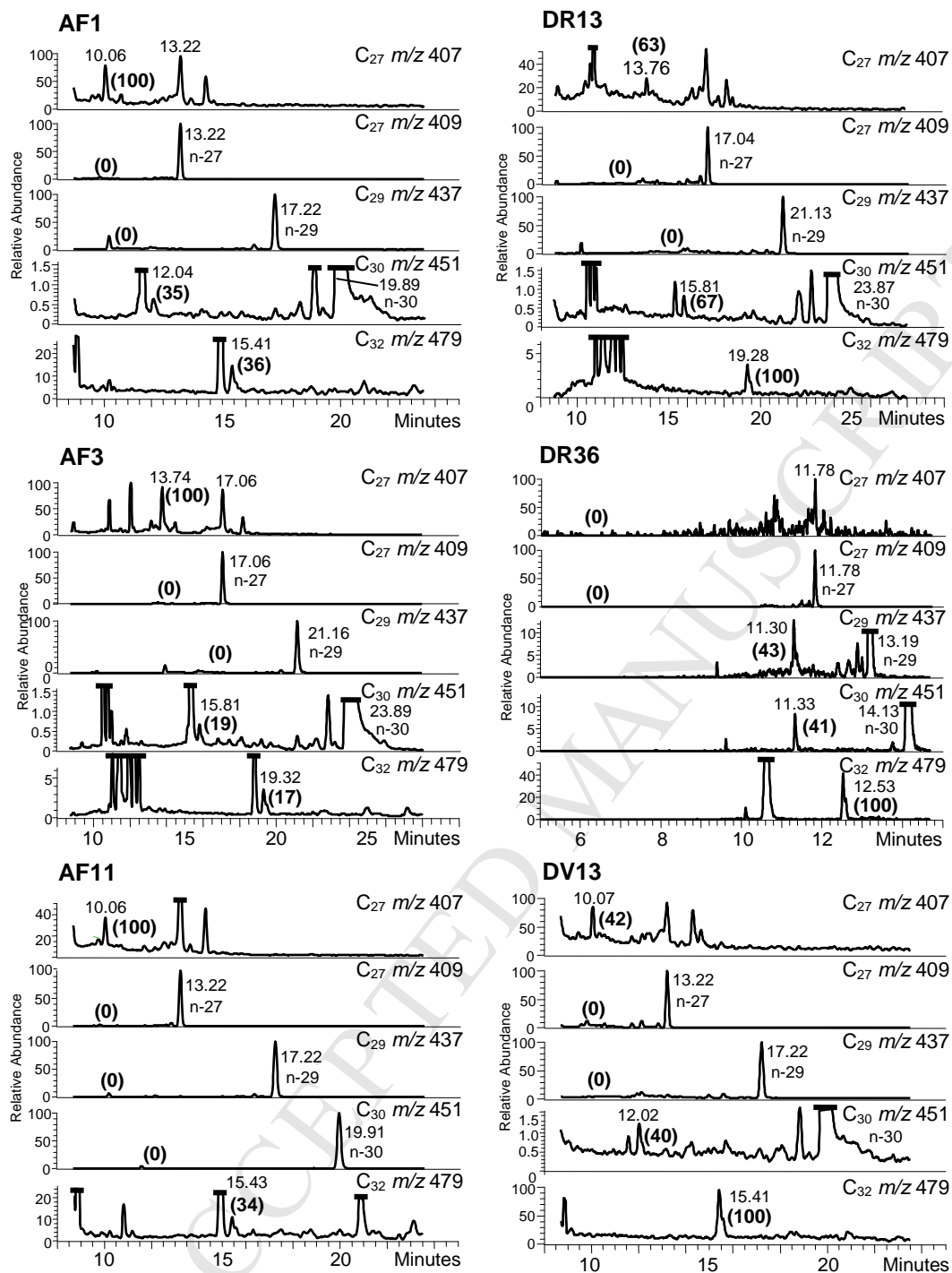
ACCE

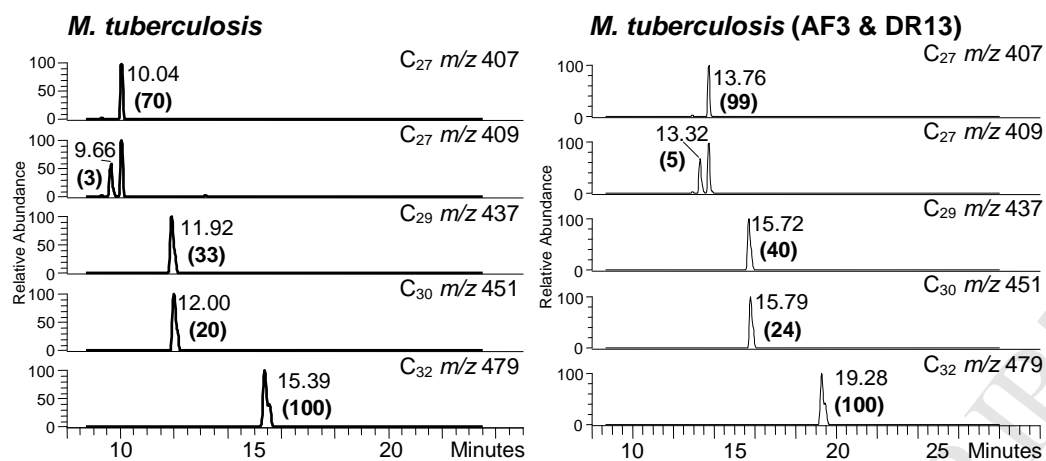




ACCEPTED MANUSCRIPT







SUPPORTING INFORMATION

Mycocerosic and mycolipenic acid analysis

A Thermo Scientific DSQII Mass Spectrometer coupled to a Thermo Scientific TRACE GC Ultra gas chromatograph, was used at Swansea University. The column was a Phenomenex Zebron ZB-5 (5% phenyl, 95% dimethylpolysiloxane; 30 m \times 0.25 mm i.d. \times 0.25 μ m film thickness), using He as carrier gas (constant flow mode 1.2 ml min⁻¹) and ammonia as the CI reagent gas. A GC oven temperature gradient from 200 to 300 °C at 17.5 °C min⁻¹ was used, the final temperature being held for 17.5 min. The ion source temperature was 170 °C, the injector used was a programmable temperature vapourising injector, which started at 50 °C for 0.2 min and increased to 300 °C at a rate of 10 °C s⁻¹ where it stayed for 0.5 min.

PFB esters, on NICI-GCMS, fragment to produce negative carboxylate [M – H]⁻ ions, which can be detected at high sensitivity. Selected ion monitoring (SIM) was used to search for mycocerosate carboxylate ions at m/z 367.6311 (C₂₄), 395.6844 (C₂₆), 409.7111 (C₂₇), 437.7645 (C₂₉), 451.7911 (C₃₀), 479.8445 (C₃₂), 493.8712 (C₃₃) and 507.8978 (C₃₄) [1]. Additionally, m/z 407.6952 was monitored for the presence of the C₂₇ mycolipenate carboxylate ion [1]. Partial racemisation of mycocerosates during the alkaline hydrolysis leads to the formation of diastereoisomers, which resolve on gas chromatography to give characteristic doublets; in contrast, mycolipenates are singlets as they cannot racemise [1]. Standard GC-MS traces, for *M. tuberculosis*, are shown below in Figure S1.

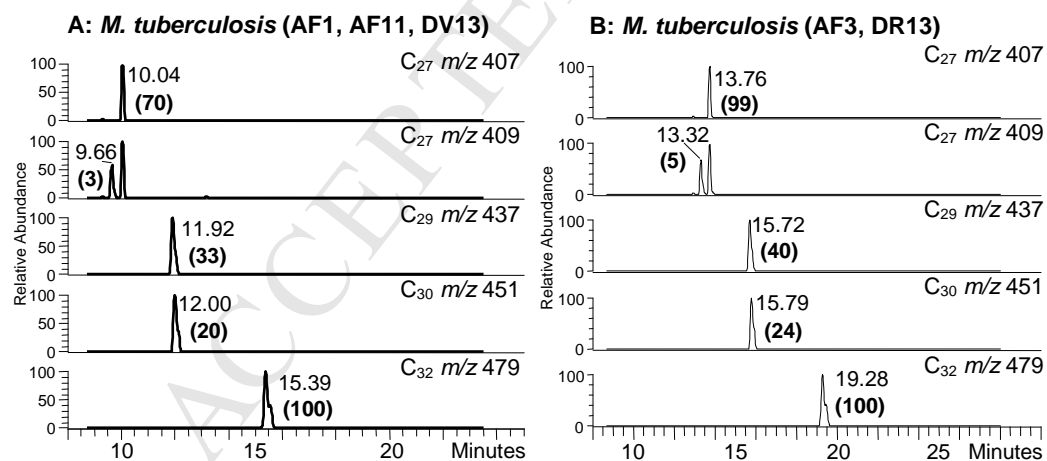


Figure S1. Selected ion monitoring (SIM) negative ion-chemical ionization gas chromatography-mass spectrometry (NI-CI GC-MS) profiles of mycolipenate and mycocerosate pentafluorobenzyl (PFB) esters from extracts of *M. tuberculosis*, recorded on different occasions. **A.** Profiles recorded to correlate with extracts of AF1, AF11 and DV13. **B.** Profiles recorded to correlate with extracts of AF2 and DR13. Circumstances did not allow recording of a standard to accompany DR36.

Ancient DNA analysis

To assess DNA extraction efficiency and to test for possible PCR inhibitors each DNA extract was subject to a PCR-based assay using a primer pair targeting the mtDNA hypervariable region 1 [2]. The presence of TB DNA was assessed by applying a PCR-based assay targeting the MTBC multicopy IS6110 region [3]. To increase the sensitivity of the assay, a nested PCR strategy was applied [4]. Initially, conventional PCR was performed using primer IS6110F and the IS6110R primer to generate a 123 base pair product. Two microliters of the initial PCR reaction was used as the template for the nested PCR.

Table S1: List of DNA Primers used in this study and the corresponding PCR conditions

Molecular target	Primer	Sequence (5'-3')	Product (bp)	PCR conditions	Reference
human mtDNA HVS-I	L16117	TACATTACTGCCAGCCACCAT	162	95°C, 5 min; 95°C, 55°C, and 72°C, 45 sec for 38 cycles	2
	H16233	GCTTTGGAGTTGCAGTTGATGTGT			
MTBC, IS6110	IS6110F	CTCGTCCAGCGCCGCTTCGG	123	95°C, 5 min; 95°C, 68°C, and 72°C, 45 sec for 45 cycles; 72°C, 4 min	3
	IS6110R	CCTGCGAGCGTAGGCGTCGG			
MTBC, IS6110 internal	IS6110intF	TTCGGACCACCAGCACCTAA	92	95°C, 5 min; 95°C, 58°C, and 72°C, 45 sec for 40 cycles; 72°C, 4 min	4
	IS6110intR	TCGGTGACAAAGGCCACGTA			

For the IS6110 PCR assay resulting in a 123 bp large fragment [3] the Ampliqaq Gold Mastermix 360 (Applied Biosystems, Foster City, CA, USA) was used according to the manufactures instructions and 2µl of GC Enhancer and 5µl of DNA were added to a final volume of 25µl. The PCR reaction mix for the mitochondrial PCR and the IS6110 internal nested PCR contained 10 mM tris-HCl (pH 8.3), 50 mM KCl, 1.875 mM MgCl₂, 200 µM of each deoxynucleotide triphosphate, 0.5 µM of each primer, 0.1 mg/ml Bovine serum albumin, 0.05 U/µl Ampliqaq Gold (Applied Biosystems, Foster City, CA, USA) and 5 µl of extracted DNA for the mitochondrial PCR or 2µl of PCR product of the IS6110 external PCR for the internal nested PCR to a final volume of 50 µl. Polymerase chain reaction was carried out according to the parameters in Table S1.

References

1. Lee OY-C, Wu HHT, Donoghue HD, Spigelman M, Greenblatt CL, et al. (2012) *Mycobacterium tuberculosis* complex lipid virulence factors preserved in the 17,000-year-old skeleton of an extinct bison, *Bison antiquus*. PLoS ONE 7: e41923.
2. Haak, W., Forster, P., Bramanti, B., Matsumura, S., Brandt, G., Tanzer, M. et al. (2005) Ancient DNA from the first European farmers in 7500-year-old Neolithic sites. Science 310: 1016-1018.
3. Eisenach, K. D., Cave. M.D., et al. (1990). "Polymerase chain reaction amplification of a repetitive DNA sequence specific for *Mycobacterium tuberculosis*." J Infect Dis 161: 977-981.
4. Taylor, G. M., M. Crossey, et al. (1996). "Mycobacterium tuberculosis identified in mediaeval human skeletal remains using polymerase chain reaction." J ArchaeolSci 23: 789-798.