

# Diagnostic accuracy of FEC-PET/CT, FDG-PET/CT, and diffusion-weighted MRI in detection of nodal metastases in surgically treated endometrial and cervical carcinoma

MAPPING Study Group

DOI:

[10.1158/1078-0432.CCR-21-1834](https://doi.org/10.1158/1078-0432.CCR-21-1834)

License:

Creative Commons: Attribution-NonCommercial-NoDerivs (CC BY-NC-ND)

*Document Version*

Publisher's PDF, also known as Version of record

*Citation for published version (Harvard):*

MAPPING Study Group 2021, 'Diagnostic accuracy of FEC-PET/CT, FDG-PET/CT, and diffusion-weighted MRI in detection of nodal metastases in surgically treated endometrial and cervical carcinoma', *Clinical Cancer Research*, vol. 27, no. 23, pp. 6457-6466. <https://doi.org/10.1158/1078-0432.CCR-21-1834>

[Link to publication on Research at Birmingham portal](#)

## General rights

Unless a licence is specified above, all rights (including copyright and moral rights) in this document are retained by the authors and/or the copyright holders. The express permission of the copyright holder must be obtained for any use of this material other than for purposes permitted by law.

- Users may freely distribute the URL that is used to identify this publication.
- Users may download and/or print one copy of the publication from the University of Birmingham research portal for the purpose of private study or non-commercial research.
- User may use extracts from the document in line with the concept of 'fair dealing' under the Copyright, Designs and Patents Act 1988 (?)
- Users may not further distribute the material nor use it for the purposes of commercial gain.

Where a licence is displayed above, please note the terms and conditions of the licence govern your use of this document.

When citing, please reference the published version.

## Take down policy

While the University of Birmingham exercises care and attention in making items available there are rare occasions when an item has been uploaded in error or has been deemed to be commercially or otherwise sensitive.

If you believe that this is the case for this document, please contact [UBIRA@lists.bham.ac.uk](mailto:UBIRA@lists.bham.ac.uk) providing details and we will remove access to the work immediately and investigate.

# Diagnostic Accuracy of FEC-PET/CT, FDG-PET/CT, and Diffusion-Weighted MRI in Detection of Nodal Metastases in Surgically Treated Endometrial and Cervical Carcinoma



Andrea G. Rockall<sup>1,2</sup>, Tara D. Barwick<sup>1,2</sup>, William Wilson<sup>3</sup>, Naveena Singh<sup>4</sup>, Nishat Bharwani<sup>1,2</sup>, Aslam Sohaib<sup>5</sup>, Marielle Nobbenhuis<sup>6</sup>, Victoria Warbey<sup>7</sup>, Marc Miquel<sup>8,9</sup>, Dow-Mu Koh<sup>5</sup>, Katja N. De Paepe<sup>5</sup>, Pierre Martin-Hirsch<sup>10</sup>, Sadaf Ghaem-Maghani<sup>1,11</sup>, Christina Fotopoulou<sup>1,11</sup>, Helen Stringfellow<sup>10</sup>, Sudha Sundar<sup>12</sup>, Ranjit Manchanda<sup>13,14,15</sup>, Anju Sahdev<sup>16</sup>, Allan Hackshaw<sup>3</sup>, and Gary J. Cook<sup>17</sup>; the MAPPING Study Group

## ABSTRACT

**Purpose:** Preoperative nodal staging is important for planning treatment in cervical cancer and endometrial cancer, but remains challenging. We compare nodal staging accuracy of <sup>18</sup>F-ethylcholine-(FEC)-PET/CT, <sup>18</sup>F-fluoro-deoxy-glucose-(FDG)-PET/CT, and diffusion-weighted-MRI (DW-MRI) with conventional morphologic MRI.

**Experimental Design:** A prospective, multicenter observational study of diagnostic accuracy for nodal metastases was undertaken in 5 gynecology centers. FEC-PET/CT, FDG-PET/CT, and DW-MRI were compared with nodal size and morphology on MRI. Reference standard was strictly correlated nodal histology. Eligibility included operable cervical cancer stage  $\geq$  1B1 or endometrial cancer (grade 3 any stage with myometrial invasion or grade 1–2 stage  $\geq$  II).

**Results:** Among 162 consenting participants, 136 underwent DW-MRI and FDG-PET/CT and 60 underwent FEC-PET/CT. In 118 patients, 267 nodal regions were strictly

correlated at histology (nodal positivity rate, 25%). Sensitivity per patient ( $n = 118$ ) for nodal size, morphology, DW-MRI, FDG- and FEC-PET/CT was 40%\*, 53%, 53%, 63%\*, and 67% for all cases (\*,  $P = 0.016$ ); 10%, 10%, 20%, 30%, and 25% in cervical cancer ( $n = 40$ ); 65%, 75%, 70%, 80% and 88% in endometrial cancer ( $n = 78$ ). FDG-PET/CT outperformed nodal size ( $P = 0.006$ ) and size ratio ( $P = 0.04$ ) for per-region sensitivity. False positive rates were all  $<10\%$ .

**Conclusions:** All imaging techniques had low sensitivity for detection of nodal metastases and cannot replace surgical nodal staging. The performance of FEC-PET/CT was not statistically different from other techniques that are more widely available. FDG-PET/CT had higher sensitivity than size in detecting nodal metastases. False positive rates were low across all methods. The low false positive rate demonstrated by FDG-PET/CT may be helpful in arbitration of challenging surgical planning decisions.

## Introduction

In patients with endometrial or cervical cancer, nodal metastatic disease adversely affects prognosis (1, 2). In cervical cancer, the 5-year relative survival rates for patients with disease localized to the cervix is 92% compared with 56% for those with positive pelvic

lymph nodes (LN; ref. 3). In endometrial cancer, the 5-year disease-free survival is 90% in patients without LN metastasis, but 60% to 70% in those with pelvic LN metastasis and 30% to 40% in those with para-aortic LN metastasis (1). Accurate LN staging is required for prognostic stratification and treatment planning, as well as tailoring the surgical approach and delineating the extent of

<sup>1</sup>Department of Surgery and Cancer, Imperial College London, London, United Kingdom. <sup>2</sup>Department of Radiology, Imperial College Healthcare NHS Trust, London, United Kingdom. <sup>3</sup>Cancer Research UK & UCL Cancer Trials Centre, University College London, United Kingdom. <sup>4</sup>Department of Pathology, Barts Health NHS Trust, London, United Kingdom. <sup>5</sup>Department of Radiology, Royal Marsden Hospital NHS Foundation Trust, London, United Kingdom. <sup>6</sup>Department of Gynaecology, Royal Marsden Hospital NHS Foundation Trust, London, United Kingdom. <sup>7</sup>Department of Radiology, Guys and St Thomas' NHS Trust, London, United Kingdom. <sup>8</sup>Clinical Physics, Barts Health NHS Trust, London, United Kingdom. <sup>9</sup>William Harvey Research Institute, Digital Environment Research Institute, Queen Mary University of London, London, United Kingdom. <sup>10</sup>Royal Preston Hospital, Lancashire Teaching Hospitals NHS Foundation Trust, Preston, United Kingdom. <sup>11</sup>Department of Gynaecology, Imperial College Healthcare NHS Trust, London, United Kingdom. <sup>12</sup>Pan Birmingham Gynaecological Cancer Centre, City Hospital and Institute of Cancer and Genomic Sciences, University of Birmingham, Birmingham, United Kingdom. <sup>13</sup>Wolfson Institute of Preventive Medicine QMUL, London, United Kingdom. <sup>14</sup>Department of Gynaecological Oncology, Barts Health NHS Trust, London, United Kingdom. <sup>15</sup>Department of Health Services Research, London School of Hygiene & Tropical

Medicine, London, United Kingdom. <sup>16</sup>Department of Radiology, St Bartholomew's Hospital, Barts Health NHS Trust, London, United Kingdom. <sup>17</sup>Cancer Imaging Department, School of Biomedical Engineering and Imaging Sciences, King's College London, London, United Kingdom.

**Note:** Supplementary data for this article are available at Clinical Cancer Research Online (<http://clincancerres.aacrjournals.org/>).

A.G. Rockall and T.D. Barwick contributed equally to this article.

Sponsor Protocol Number: 007697 EudraCT Number: 2011–001290–78.

**Corresponding Author:** Andrea G. Rockall, Division of Surgery and Cancer, Imperial College London, ICTEM Building, Hammersmith Campus, Du Cane Road, London W12 0NS, United Kingdom. E-mail: a.rockall@imperial.ac.uk

Clin Cancer Res 2021;27:6457–66

doi: 10.1158/1078-0432.CCR-21-1834

This open access article is distributed under Creative Commons Attribution-NonCommercial-NoDerivatives License 4.0 International (CC BY-NC-ND).

©2021 The Authors; Published by the American Association for Cancer Research

Rockall et al.

### Translational Relevance

Nodal status is a highly important prognostic factor in endometrial and cervical cancers and has a significant impact on patient risk stratification and management. This is the first multicenter prospective study to directly compare the diagnostic performance of FEC-PET/CT, FDG-PET/CT, and DW-MRI for the detection of nodal involvement in surgically staged endometrial and cervical cancers, with a strict histologic reference standard. No technique had sufficient sensitivity to obviate the need for surgical nodal staging in radiologically node-negative patients, in cases where nodal staging is considered appropriate. However, the low false positive rate may contribute to patient risk stratification in cases with difficult surgical decision making, for arbitration in borderline surgical cases: In cervical cancer, an FDG-positive case could support a decision to redirect patients from radical surgery to chemoradiotherapy options. In endometrial cancer, an FDG-positive case could allow planning of a more tailored therapeutic approach. By identifying the site and extent of avid nodes, a targeted surgical dissection of the area of interest could be planned, avoiding morbidity from unnecessary radicality. Moreover, a preoperative discussion with the patient about their systemic and radiotherapeutic options and how those would complement any surgical approach, would be facilitated.

radiotherapy in both cervical and endometrial cancer. Knowledge of LN status is of paramount importance to stratify patients to radical hysterectomy versus primary chemoradiotherapy, particularly in cervical cancer.

In endometrial cancer, most patients will undergo at least a hysterectomy and bilateral salpingo-oophorectomy as primary treatment. The International Federation of Gynecology and Obstetrics (FIGO) include the LN status in the tumor staging of the patients, and so national and international guidelines recommend surgical LN staging in high-risk subtypes (4, 5). However, there has not been any prospective evidence so far to demonstrate therapeutic value of systematic lymphadenectomy (LND) in endometrial cancer (6–9). Even though sentinel LN techniques are now gradually replacing systematic LND in multiple guidelines (10–12), its implementation is not yet homogenous around the world due to infrastructural, financial, and governance challenges. For that reason many patients still undergo LND with all the associated sequelae such as lymphocyst formation, lymphorrhea and lymphedema in addition to higher surgical morbidity. The accurate and reliable preoperative identification of LN-positive patients, therefore, still represents an unmet need to adequately tailor therapeutic management.

In cervical cancer, radical hysterectomy is not recommended in LN-positive patients, and so the accurate preoperative identification of even microscopically involved LN would spare those patients unnecessary surgical morbidity and direct them to chemoradiotherapy with exact tailoring of the extended field.

Although the preoperative detection of nodal metastases would be practice-changing, conventional imaging techniques, including CT and MRI, that rely on LN size criteria and morphology (shape, contour, signal intensity) are largely unreliable (10). Few prospective multicenter trials with a histological reference standard to guide management exist (11).

Several functional imaging techniques have been evaluated in an attempt to improve preoperative nodal staging. DW-MRI,

which assesses tissue diffusion properties and cellularity, is now widely established for routine use in pelvic MRI in cervical and endometrial cancer staging although published results of DW-MRI in nodal diagnosis are variable (13).

FDG-PET/CT is established in staging locally advanced cervical cancer and incorporated into guidelines due to its diagnostic superiority (12, 14). The role of FDG-PET/CT in endometrial cancer has not been clearly established with a lack of evidence to date (15). In general, FDG-PET/CT has high specificity for nodal involvement in advanced cervical and endometrial cancer but low to moderate sensitivity remains problematic, particularly in early-stage disease (15–17).

Choline-PET imaging is a surrogate marker of accelerated cell membrane metabolism in cancer and has an established role in imaging of prostate cancer, including nodal assessment for high-risk staging (18). In cell line studies of endometrial cancer, the expression and activity of choline kinase alpha is increased with a several-fold increase in the uptake of <sup>3</sup>H choline in endometrial cancer cells compared with normal endometrial stromal cells (19). Early pilot studies of <sup>11</sup>C choline in gynecologic cancer show promise (20, 21); however, <sup>18</sup>F-labeled fluoro-methyl and fluoro-ethyl choline have a longer radioactive half-life (110 minutes) and are therefore more practical to use. The use of Fluoro-ethyl-choline (FEC)-PET/CT in detecting nodal metastases in endometrial and cervical cancer has not been previously explored.

Our hypothesis was that any of DW-MRI, FEC-PET/CT or FDG-PET/CT could preoperatively identify LN metastases, with sufficiently high accuracy, to replace the need for surgical LN staging but also identify those patients who should not undergo surgery, in eligible patients with seemingly operable cervical and high-risk endometrial cancer.

## Materials and Methods

### Study design and participants

MAPPING is a multicenter, prospective observational study evaluating the diagnostic accuracy for detecting nodal metastases using different imaging methods. Ethics approval, ARSAC licence, and MHRA approvals were obtained (Research Ethics Committee reference number 11/LO/1465). The study was sponsored by Barts Health NHS Trust. The Centre for Experimental Cancer Medicine (CECM), Barts Cancer Institute, Queen Mary University of London had overall responsibility for trial management. All participants gave written informed consent.

Eligible patients were aged  $\geq 18$  years, with newly diagnosed histologically confirmed cervical or endometrial cancer and were eligible and fit for surgical lymphadenectomy, as per the decision of a multidisciplinary tumor board and assessment by a specialist surgical and anaesthetic team. Pretreatment FIGO stage (2009) was established on the basis of clinical examination and standard-of-care imaging (CT and MRI). Patients with cervical cancer were eligible if the pretreatment FIGO stage was considered stage IB and local disease appeared operable. Patients with endometrial cancer were eligible if high-risk features for LN metastases, that is, histologic grade was high-grade (including grade 3 endometrioid adenocarcinoma, serous, clear cell, or carcinosarcoma) with myometrial invasion on MRI, or MRI-based FIGO stage II or above. Patients were ineligible if unable to provide written informed consent, were pregnant or had contra-indications to MRI or PET/CT (Supplementary Table S1).

## Imaging in Nodal Staging in Cervix and Endometrial Cancer

### Procedures

All imaging tests were performed before surgery and within the national standard time frame of preoperative care. Standard-of-care MRI scan was performed first, and as per local practice. FDG- and FEC-PET/CT scans had to be performed on separate days, and the DW-MRI scan could be performed alongside either of these, and at the same time as the conventional MRI (Supplementary Fig. S1).

### MRI

Standard-of-care MRI scan for staging was performed as per local protocol. The MRI field of view included the pelvis and para-aortic regions up to the level of the left renal vein. For nodal evaluation, readers had a minimal dataset that included axial T1, axial T2, and study-specific axial DW-MRI (b values 0, 300, 600, 900, and 1,200) with associated calculated ADC maps, following optimization with ice-water phantom (Supplementary Table S2). The details of standard-of-care MRI and DW-MRI are provided in Supplementary Table S2A–S2C.

### FDG-PET/CT and FEC-PET/CT

FDG- and FEC-PET/CT scans were performed using a standard protocol (Supplementary Table S2D) based on UK NCRI PET Research Network guidance. Each center had been accredited by the NCRI PET Research Network for multicenter trials. All scans were acquired from base of skull to upper thighs as 3D acquisitions with TOF if available. Low-dose CT acquisitions were made for attenuation correction and image fusion. FDG-PET/CT scans were acquired at a median of 60 minutes postinjection (range 57–80) and FEC-PET/CT scans at a median 60 minutes (range 55–74) and the two scans were acquired on different days.

Participants fasted for  $\geq 4$  hours prior to FDG injection (median 370 MBq, range 217–436 MBq) and scanning only performed if blood glucose was  $< 10$  mmol/L. Fasting was not required prior to FEC injection (median 293 MBq, range 209–369 MBq). Patients were asked to void their bladder before both scans. Both tracers were classified as investigational medical products. Patients were contacted 24 hours following scans to record any adverse events.

### Reader evaluations

All imaging scans were read by one local and two central radiologists. The central reviews were coordinated through the UK NCRI PET core lab (PET) and the trials unit (MRI), and discordant reviews were resolved by consensus. All radiologists were accredited core members of the gynecology multi-disciplinary team and/or PET/CT experts. All readers were aware of the clinical diagnosis (endometrial or cervical cancer) but when assessing each scan they were blinded to all other imaging scans, surgical findings and final histology. The local radiologic assessment was used for the main analyses to be consistent with patient management and treatment being guided by the local MRI evaluation.

Evaluation of nodes using the standard MRI, DW-MRI, and PET scans was based on a 6-point confidence score: 1, definitely benign; 2, probably benign; 3, low confidence benign; 4, low confidence malignant; 5, probably malignant; 6, definitely malignant. A score of 5 or 6 was classified as test-positive.

### Conventional MRI nodal diagnosis based on MRI size and morphology

The anatomic location of nodes that were  $\geq 5$  mm and their short and long axis diameter were recorded. If there were multiple nodes in one anatomic region, the largest or most suspicious node was used for

the nodal descriptors (fatty hilum, homogeneous appearance, necrosis, or irregular margin). Nodal diagnosis was then made using the size (in mm), or nodal morphology (based on the 6-point confidence score); both without reference to the DW-MRI.

The diagnosis based on nodal size criteria was considered using three cutoffs, analyzed separately: (i) short axis diameter  $> 9$  mm; (ii) short axis  $> 10$  mm or (iii) “size ratio” criteria, whereby a node  $< 8$  mm short axis is considered benign, node  $> 10$  mm short axis is considered metastatic (and therefore positive), but a node with a short axis between 8 and 10 mm is only considered positive if the short axis to long axis ratio is over 0.8 (i.e., a round node; ref. 22).

### Nodal diagnosis based on DW-MRI

Nodes were identified on the high b value DW-MRI as noncontinuous high signal intensity (SI) round or ovoid structures that corresponded with a node on the anatomic images. Nodes that retained very high SI on the high b value images, without T2 shine-through, were considered to be positive based on the 6-point confidence score.

### Nodal diagnosis based on PET/CT

The anatomic location of any focally increased tracer uptake that was higher than background adjacent tissue corresponding to a node of any size on the CT was recorded and assessed according to a 5-point scale (A, normal FDG/FEC uptake; B, mild increased FDG/FEC uptake likely not to represent tumor involvement; C, equivocal FDG/FEC uptake; D, moderately increased FDG/FEC uptake likely to represent tumor involvement; E, intensely increased FDG/FEC uptake representing tumor involvement). The 6-point confidence level was used for nodal diagnosis.

### Primary reference standard

The primary reference standard was confirmed nodal histology obtained by surgical lymphadenectomy. The surgeon was made aware of the position of any suspicious node prior to the lymphadenectomy to ensure the highest likelihood of correlating all suspected positive nodes based on imaging tests. The surgeon recorded the site of resected nodes that were labeled for histologic correlation according to the predefined protocol.

All retrieved nodes were analysed by expert gynecology histopathologists at each site and the anatomic location of all nodes, nodal size, and presence of metastatic disease were recorded. The histopathologist was blind to all image findings, although they were aware of the original histopathology results from preoperative biopsy of the primary tumor, as per standard practice.

In cases where imaging suggested an involved node but histopathology was negative, further reviews were undertaken to avoid an uncertain reference standard due to the possibility that the node was not retrieved at surgery. First, any postoperative imaging was reviewed by an expert consensus to be certain that all suspicious nodes had been retrieved at surgery. If the suspicious node remained *in situ*, then the case was not eligible for analysis by the primary reference standard, as the correlation with histology was uncertain. Second, the most suspicious node underwent ultrasectioning and immunostains to ensure very high sensitivity for micrometastases. Where histopathology was positive but imaging negative, then the imaging was deemed false-negative.

The final histologic subtype and pathologic stage of the primary tumor were recorded. If no nodal tissue was obtained in the surgical specimen, the case was not eligible for analysis with the histologic primary reference standard.

Rockall et al.

### Secondary reference standard

A secondary reference standard was specified to allow for inclusion of patients in whom definitive histopathology was unavailable (either no surgery, no nodal tissue retrieved or suspicious node not resected), and therefore could not be included in analyses using the primary reference standard. This secondary reference standard was comprised by a consensus panel that reviewed all available imaging and clinical information for 9 months from when the patient was recruited to impute the presence and position of any positive nodal sites, for example by identifying progression in a node or clear regression following treatment. If no follow-up was available, the patient was excluded from analysis.

### Outcome measures

The primary outcome measures were sensitivity and false positive rate [FPR] for histologically confirmed nodal metastatic disease. Sensitivity is the proportion of cases who are test-positive among all who have confirmed metastatic disease. FPR (specificity) is the proportion of cases who are test-positive among all those who do not have metastatic disease. These were estimated for each of the DW-MRI, FEC-, and FDG-PET/CT scans, and also (using standard MRI) nodal size criteria and morphology. Secondary outcome measures were positive and negative predictive values. Analyses were performed according to cervical or endometrial cancer, and on a per-patient level (all surgically resected nodal regions considered together) and per-nodal-region level (right pelvis, left pelvis, para-aortic).

### Statistical considerations

Sensitivities of DW-MRI, FDG- and FEC-PET/CT were compared with that of nodal size, using a McNemar paired test. The primary analysis was based on patients who had both DW-MRI and FDG-PET/CT, as these were mandatory for study inclusion and FEC-PET/CT was optional.

Sample size assumptions were based on results for conventional MRI nodal size, DW-MRI (original calculation based on Thoeny HC et al, ESUR 2009 abstract MS8 p45) and FDG-PET/CT (23).

For comparing sensitivity of DW-MRI (93%) with nodal size (47%), at a fixed FPR of 25% (the published estimate for DW-MRI), using a discordant paired analysis, 19 subjects with confirmed histologic nodal disease were required (80% power, and one-sided statistical significance of 0.017 to allow for three main comparisons). Assuming 15% of patients have nodal disease, 127 patients were needed in total. For comparing the sensitivity of FDG-PET/CT (73%) with nodal size (27%), at a fixed FPR of 3% (the published estimate for FDG-PET/CT), required 23 patients with confirmed nodal disease and therefore about 150 in total.

The target study size was taken as the greater of the two main comparisons:  $n = 150$  patients. No preliminary data were available for FEC-PET/CT, but we expected that FEC-PET/CT would have a diagnostic performance similar to either DW-MRI or FDG-PET/CT, and thus not require a larger sample size. A statistically significant difference was taken to be  $<0.034$  (two-sided, as per the design and power calculation).

Interrater agreement between local and the central consensus reviews was assessed using Cohen kappa statistic.

## Results

Participants were included from 5 gynecology tertiary referral centers in National Health Service (NHS) hospitals in England (Supplementary Table S2A). Consent was obtained from 162 patients

between October 2012 and July 2017 (Fig. 1). Among the 145 patients who had any study imaging and surgery, surgery was performed laparoscopically in 64, open in 42, robotically assisted procedure in 32 and 7 did not undergo surgery [advanced disease on PET ( $n = 1$ ), investigator decision ( $n = 2$ ), patient decision ( $n = 1$ ), unable to comply with study schedule ( $n = 2$ )]. The diagnosis was endometrial cancer in 98 and cervical cancer in 47 patients (Table 1).

Our primary analyses were based on the 118 who had both DW-MRI and FDG-PET/CT, and definitive histopathology according to the primary reference standard; baseline patient and tumor characteristics are in Table 1 and Supplementary Table S3. The median time interval between preoperative imaging and nodal surgery was 26 days, (range 1–83) for standard-of-care MRI, 12 days (1–58) for DW-MRI, 7.5 days (0–44), for FDG-PET/CT (one patient being imaged early morning prior to evening surgery) and 7 days (1–28) for FEC-PET/CT. Among 118 cases included with primary reference standard, 4 cases had review of post operative imaging for confirmation of nodal resection.

Metastatic nodal disease was histologically confirmed in 25.4% (30/118) patients in both tumor types, according to the primary reference standard: 10 of 40 patients of cervical cancer and 20 of 78 patients of endometrial cancer.

### Diagnostic accuracy using primary reference standard

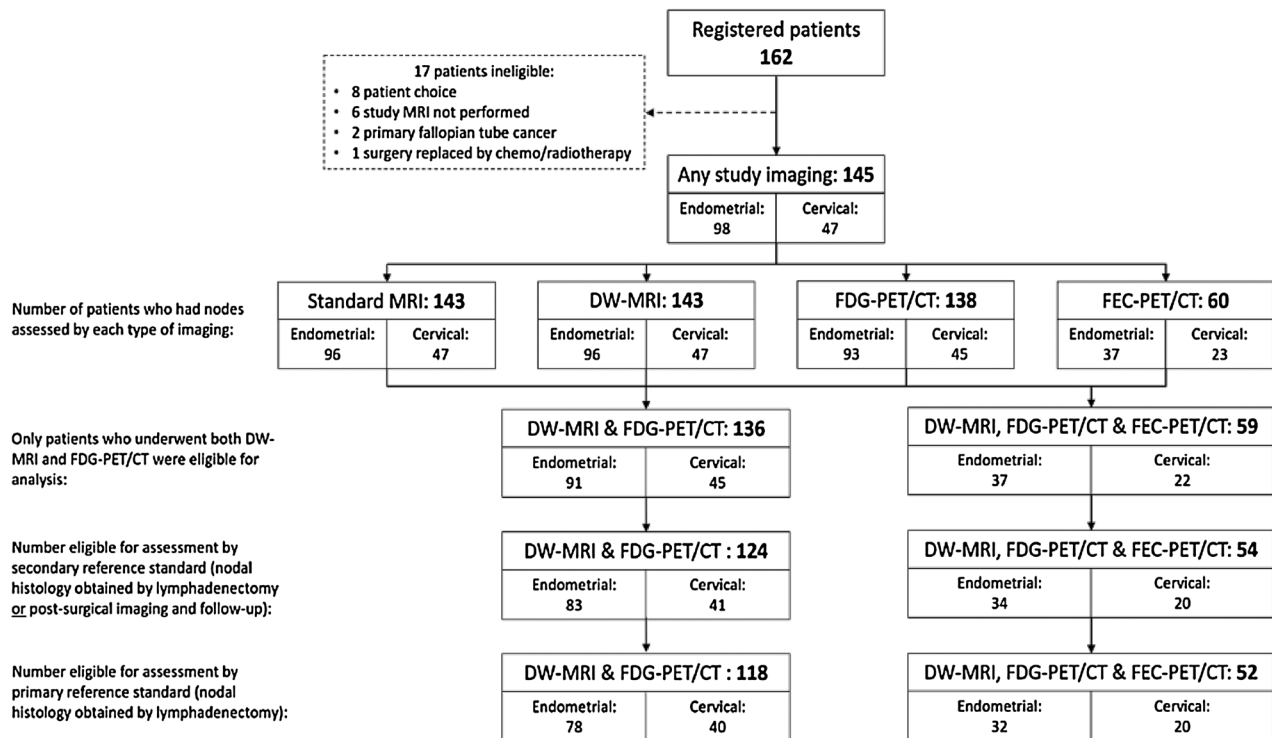
On a per patient basis, for all patients combined, diagnosis based on nodal morphology was equivalent to DW-MRI with sensitivities and FPRs of 53% [95% confidence interval (CI), 34–72] and 3% (95% CI, 1–10), respectively (Table 2). FDG-PET/CT had the same FPR but with a slightly higher sensitivity of 63% (95% CI, 44–80), while FEC-PET/CT had sensitivity and FPR of 67% (95% CI, 35–90) and 3% (95% CI, 0–13), respectively. Diagnosis based on short axis  $>10$  mm had a sensitivity of 40% (95% CI, 23–59) and FPR of 5% (95% CI, 1–11). McNemar tests found FDG-PET/CT to have significantly better sensitivity than short axis  $>10$  mm ( $P = 0.016$ ) while all other comparisons were not statistically significant.

On a per-region basis ( $n = 267$  regions among the 118 patients, mean 2.3 regions per patient), diagnostic performances differed only slightly (Supplementary Table S4A–S4C) and McNemar tests found FDG-PET/CT outperformed both short axis  $>10$  mm ( $P = 0.006$ ) and size ratio criteria ( $P = 0.04$ ) with regards to sensitivity. Distant metastases were described on PET/CT in 8 of 162 patients, 6 included in the primary reference standard and 2 excluded due to final histology being ovarian cancer ( $n = 1$ ) and no histology or follow-up imaging therefore no nodal reference standard available ( $n = 1$ ; Fig. 1).

Among 40 patients with cervical cancer, 10 (25%) had confirmed histologic nodal metastases, only 1 of which had a LN short axis  $>10$  mm. The sensitivities were lower, ranging from 10% (size ratio criteria, morphology and short axis  $>9$  mm) to 30% (FDG-PET/CT; Table 3). There was no significant difference in modalities among these patients in terms of sensitivity or FPR. Only 4 patients had an MRI FIGO stage greater than 1B1 (as expected due to patient selection for operability) and in these cases the FPR was 0% for all tests (Supplementary Table S5).

Among 78 patients with endometrial cancer, 20 (25.6%) had confirmed histologic nodal metastases, 15 of whom had a LN short axis  $>10$  mm. Sensitivities were 75% (95% CI, 51–91) for morphology, and 65% (95% CI, 41–85) for short axis  $>9$  mm, 70% (95% CI, 46–88) for DW-MRI, 80% (95% CI, 56–94) for FDG-PET/CT, 88% (95% CI, 47–100) for FEC-PET/CT. FPRs ranged from 9% (95% CI, 3–19) for size ratio criteria to 3% (95% CI, 0–12) for DW-MRI (Table 4). No imaging modality had significantly better sensitivity or FPR among

## Imaging in Nodal Staging in Cervix and Endometrial Cancer



**Figure 1.**  
Study CONSORT diagram.

patients with endometrial cancer. Of the 27 cases with stage 1A disease based on MRI, there was no histologically confirmed nodal metastasis, with a single false positive detection on MRI and no false positives on PET/CT with very high NPV on PET/CT (Supplementary Table S5C). There were 20 cases with stage 1B disease based on MRI of which only one had a suspected nodal metastasis, detected on DW-MRI, and was false-negative on FDG-PET/CT, size and morphology (Supplementary Table S5D). Among 30 patients with cancer stage higher than 1B on MRI, 19 had nodal metastases and the sensitivity and FPR based on MRI nodal morphology was 79% (95% CI, 54–94) and 9% (95% CI, 0–41), for DW-MRI was 68% (95% CI, 43–87) and 9% (95% CI, 0–41) and for FDG-PET/CT was 84% (95% CI, 60–97) and 9% (95% CI, 0–41; Supplementary Table S5E).

The above results were based on patients who had both the DW-MRI and FDG-PET/CT scans. Quantitative values for FDG- and FEC-SUV and ADC in positive and negative nodes are provided in Supplementary Table S6.

### Secondary reference standard

Eighteen patients were not included in the main analyses because they did not have definitive histopathology correlation using the primary reference standard. This included 4 patients who did not undergo surgery, 3 patients in whom a suspected positive node remained visible on postoperative imaging therefore not considered resected (Fig. 2, all included in secondary reference standard), 3 in whom lymphadenectomy was attempted but no nodal tissue retrieved and 8 who underwent surgery but lymphadenectomy was abandoned during surgery for clinical reasons. Of these 18 patients, 6 in total had postoperative imaging and follow-up to 9 months. Combining these with the 118 who had the primary reference standard, gave a total of

124 patients for analyses based on the secondary reference standard (Fig. 1). 25.8% (32/124) had nodal metastasis. Results using the secondary reference standard did not differ substantially from results based on the primary reference standard and are available in Supplementary Table S7A–S7C. Twelve patients had no histology or imaging follow-up and therefore could not be included (Fig. 1).

### Central review

Diagnostic performance based on the independent central review did not differ substantially from the local radiologist assessment (Supplementary Table S8). Interrater agreement between local and central consensus reviews was high for each imaging modality, with kappa statistics of 0.70, 0.86, and 0.79 for DW-MRI, FDG-, and FEC-PET/CT, respectively.

### Adverse events

The MAPPING study was conducted as a study of investigational medicinal products, according to MHRA guidance. Adverse events were collected for all patients who underwent at least one of the trial PET scans ( $n = 147$  participants, Supplementary Table S9). One patient had mood alteration and another had vomiting, both thought to be related to FEC-PET/CT. One patient had hyperglycaemia and another developed a rash, these were considered related to FDG-PET/CT. There were no serious adverse events.

### Discussion

In this multicenter prospective cohort study, with a strict histologic reference standard, we failed to demonstrate a significantly higher sensitivity, on a per patient basis ( $n = 118$ ), using FEC-PET/CT,

Rockall et al.

**Table 1.** Baseline characteristics of the 118 patients who had confirmed histopathology using the primary reference standard.

Characteristics	Cervical (n = 40)		Endometrial (n = 78)	
Age (years), median (range)	38 (24–75)		67 (27–83)	
Ethnic group, N (%)				
Asian (Indian)	1 (2.5)		8 (10.3)	
Asian (Other)	1 (2.5)		3 (3.8)	
Asian Pakistani	1 (2.5)		0	
Black (African)	0		3 (3.8)	
Black (Caribbean)	0		2 (2.6)	
Chinese	0		1 (1.3)	
Other	2 (5.0)		1 (1.3)	
White	35 (87.5)		58 (74.4)	
Unknown	0		2 (2.6)	
Histology, n (%)				
Adenocarcinoma		13 (32.5)	Endometrioid	37 (47.4)
Adenosquamous		4 (10.0)	Serous/clear cell	31 (39.7)
Squamous cell		22 (55.0)	Carcinosarcoma	2 (2.6)
Unknown		1 (2.5)	Mixed <sup>a</sup>	6 (7.7)
			Unknown	2 (2.6)
Lymphovascular space invasion (LVSI), n (%)				
No	22 (55.0)		41 (52.6)	
Yes	16 (40.0)		29 (37.2)	
Unknown	2 (5.0)		8 (10.3)	
Differentiation, n (%)				
Grade 1	5 (12.5)		7 (9.0)	
Grade 2	20 (50.0)		9 (11.5)	
Grade 3	12 (30.0)		59 (75.6)	
Unknown	3 (7.5)		3 (3.8)	
FIGO stage (on MRI), n (%)				
1B1		36 (90.0)	1A	27 (34.6)
1B2		1 (2.5)	1B	20 (25.6)
2A1		2 (5.0)	2	9 (11.5)
2B		1 (2.5)	3A	3 (3.8)
			3C	13 (16.7)
			4B	5 (6.4)
			Unknown	1 (1.3)

<sup>a</sup>Five mixed endometrioid and serous/clear cell and one mixed serous/clear cell and carcinosarcoma.

FDG-PET/CT, or DW-MRI compared with standard MRI in the radiologic detection of nodal metastases in seemingly operable cervical (sensitivities of 20–30% compared with 10%) and in endometrial cancer (sensitivities of 70%–87.5% compared with 75%). FEC-PET/CT, studied as a possible alternative to FDG, was not found to improve diagnostic performance compared with FDG-PET/CT, with sensitivity of 66.7% in the entire cohort (25% in cervical cancer and 87.5% in endometrial cancer). As such, we could not establish any preoperative imaging that had sufficient sensitivity to obviate the need for surgical LN staging in seemingly operable early-stage cervical and operable endometrial cancer.

On a per-region basis ( $n = 267$ ), FDG-PET/CT outperformed both short axis >10 mm ( $P = 0.006$ ) and size ratio criteria ( $P = 0.04$ ) with regards to sensitivity.

Importantly, we demonstrated very low false positive rates for LN metastases in both cervical and endometrial cancers (ranging from 2.5%–6.8%) across all imaging modalities. This high specificity suggests that positive preoperative imaging can be relied upon to indicate nodal involvement, even in the case of non bulky LN, so that indication for surgery and extent of surgical radicality can be appropriately modified.

The performance of functional imaging techniques was better in the cohort of endometrial, compared to cervical cancer patients. This may be attributed to the fact that only patients with early-stage cervical

cancer with non-bulky LN on conventional imaging were included, because only those were eligible for surgery, as opposed to patients with endometrial cancer, where those with bulky LN were considered operable and hence included in our study.

In the cohort of patients with endometrial cancer, radiologic detection of nodal metastases was demonstrated to be reasonably sensitive (FDG-PET/CT 80%, FEC-PET/CT 87.5%) and highly specific (false positive rate: FDG-PET/CT 5%, FEC-PET/CT 4%). Of all the modalities, PET/CT had higher performance than MRI with or without DW-MRI, although this was not statistically significant. This first study using FEC-PET/CT in endometrial cancer demonstrated good diagnostic performance but not statistically better than FDG-PET/CT. In endometrial cancer, FDG-PET/CT is not currently used routinely but the high negative predictive value (NPV: FDG-PET/CT 93.2%, FEC-PET/CT 95.8%) could be used to re-inforce standard-of-care imaging to arbitrate difficult or borderline surgical decisions concerning surgical lymphadenectomy. Surgical LN staging is recommended in apparent uterine-confined high-risk endometrial cancer (5) but there is no prospective evidence so far to demonstrate a therapeutic value of systematic LND (9). A corroboration of a borderline or suspicious morphologic imaging test with a functional imaging test could support the decision to proceed with nodal dissection and allow planning of surgical approach and extent to minimize morbidity related to the surgery and subsequent increased risk of lymphoedema.

## Imaging in Nodal Staging in Cervix and Endometrial Cancer

**Table 2.** Estimates of diagnostic performance using the primary reference standard: Per patient diagnostic performance among all patients.

Diagnostic method <sup>a</sup>	No. patients	Confirmed node metastatic disease		Confirmed without nodal disease		Sensitivity (95% CI)	False-positive rate (95% CI)	PPV (95% CI)	NPV (95% CI)
		True +ve	False -ve	True -ve	False +ve				
DW-MRI	118	16 (13.6%)	14 (11.9%)	85 (72.0%)	3 (2.5%)	53.3% (34.3–71.7)	3.4% (0.7–9.6)	84.2% (60.4–96.6)	85.9% (77.4–92.0)
FDG-PET/CT	118	19 (16.1%)	11 (9.3%)	85 (72.0%)	3 (2.5%)	63.3% (43.9–80.1)	3.4% (0.7–9.6)	86.4% (65.1–97.1)	88.5% (80.4–94.1)
FEC-PET/CT	52	8 (15.4%)	4 (7.7%)	39 (75.0%)	1 (1.9%)	66.7% (34.9–90.1)	2.5% (0.1–13.2)	88.9% (51.8–99.7)	90.7% (77.9–97.4)
Diagnosis based on morphology	118	16 (13.6%)	14 (11.9%)	85 (72.0%)	3 (2.5%)	53.3% (34.3–71.7)	3.4% (0.7–9.6)	84.2% (60.4–96.6)	85.9% (77.4–92.0)
Short axis									
>9 mm	118	14 (11.9%)	16 (13.6%)	82 (69.5%)	6 (5.1%)	46.7% (28.3–65.7)	6.8% (2.5–14.3)	70.0% (45.7–88.1)	83.7% (74.8–90.4)
>10 mm	118	12 (10.2%)	18 (15.3%)	84 (71.2%)	4 (3.4%)	40.0% (22.7–59.4)	4.5% (1.3–11.2)	75.0% (47.6–92.7)	82.4% (73.6–89.2)
Size ratio criteria	118	14 (11.9%)	16 (13.6%)	82 (69.5%)	6 (5.1%)	46.7% (28.3–65.7)	6.8% (2.5–14.3)	70.0% (45.7–88.1)	83.7% (74.8–90.4)

Abbreviation: PPV, positive predictive value.

<sup>a</sup>For all imaging, a positive test result is defined as a confidence score of 5 or 6 (see Materials and Methods); for short axis, a positive result is defined in the table, and for size ratio criteria see Materials and Methods.

Our study provides prospective multicenter evidence that would support the use of FDG-PET/CT in endometrial cancer cases with difficult surgical decision-making, in order to direct surgical resection to the positive LN avoiding more extensive lymphadenectomy. In cases with a positive PET/CT, the surgical plan could include limited targeted resection of individual accessible positive nodes at the time of hysterectomy, followed by adjuvant therapy or a decision to avoid nodal dissection altogether to treat with targeted radiotherapy depending on the overall tumor dissemination pattern and patient's profile. In cases that are PET/CT-negative, but intermediate to high risk disease, there is increasing evidence for the use of sentinel lymph node technique as a viable alternative for systematic LND (24).

This is the first study to report the use of FEC-PET/CT as an alternative to FDG-PET/CT in the nodal staging of endometrial cancer. The rationale to study this was choline-PET/CT has shown promise in the nodal staging of high risk prostate cancer (25) and supportive feasibility data of <sup>11</sup>C-choline-PET in gynecologic cancers (20, 21). In our study, FEC-PET/CT performed well, but with no statistical difference to FDG-PET/CT. In daily practice, FDG is more widely available and therefore more practical.

There are no similar multicenter prospective studies in the last five years in gynecologic malignancies. Eight prospective studies have evaluated endometrial cancer with FDG-PET/CT and surgical-pathologic reference standard between 2009 and 2019 (with inclusion of more than 30 patients, range 37–220; refs. 26–33). The range of sensitivities was between 45.8% and 93.3% and FPRs between 3.0% and 8.8% apart from one study with a higher FPR of 17.9% (31). The largest multicenter prospective study of FDG-PET/CT in endometrial cancer (27), reported per patient sensitivity of 59% (23/39) for nodal metastases in those patients that had histologic confirmation, a little lower than 80.0% in our study. Criteria for nodal involvement and details of surgical reference standard were not described. A more recent single-center prospective study in patients with high-risk endometrial cancer found a lower sensitivity of 45.8% (11/24), specificity of 91.1% (72/79) for nodal metastatic disease in 103 patients (33). In this study, there was a similar prevalence of nodal involvement in the cases that underwent nodal dissection (23.3% vs. 26% in our study) and more FIGO stage 1A cases, although they did not mention the size of the nodes. Their sensitivity is lower than other studies included in a meta analysis that reported the pooled sensitivity of 68% (34). In

**Table 3.** Estimates of diagnostic performance using the primary reference standard: per patient diagnostic performance among patients with cervical cancer.

Diagnostic method <sup>a</sup>	No. patients	Confirmed node metastatic disease		Confirmed without nodal disease		Sensitivity (95% CI)	False-positive rate (95% CI)	PPV (95% CI)	NPV (95% CI)
		True +ve	False -ve	True -ve	False +ve				
DW-MRI	40	2 (5.0%)	8 (20.0%)	29 (72.5%)	1 (2.5%)	20.0% (2.5–55.6)	3.3% (0.1–17.2)	66.7% (9.4–99.2)	78.4% (61.8–90.2)
FDG-PET/CT	40	3 (7.5%)	7 (17.5%)	30 (75.0%)	0 (0.0%)	30.0% (6.7–65.2)	0.0% (0.0–11.6)	100.0% (29.2–100.0)	81.1% (64.8–92.0)
FEC-PET/CT	20	1 (5.0%)	3 (15.0%)	16 (80.0%)	0 (0.0%)	25.0% (0.6–80.6)	0.0% (0.0–20.6)	100.0% (2.5–100.0)	84.2% (60.4–96.6)
Diagnosis based on morphology	40	1 (2.5%)	9 (22.5%)	30 (75.0%)	0 (0.0%)	10.0% (0.3–44.5)	0.0% (0.0–11.6)	100.0% (2.5–100.0)	76.9% (60.7–88.9)
Short axis									
>9 mm	40	1 (2.5%)	9 (22.5%)	28 (70.0%)	2 (5.0%)	10.0% (0.3–44.5)	6.7% (0.8–22.1)	33.3% (0.8–90.6)	75.7% (58.8–88.2)
>10 mm	40	1 (2.5%)	9 (22.5%)	30 (75.0%)	0 (0.0%)	10.0% (0.3–44.5)	0.0% (0.0–11.6)	100.0% (2.5–100.0)	76.9% (60.7–88.9)
Size ratio criteria	40	1 (2.5%)	9 (22.5%)	29 (72.5%)	1 (2.5%)	10.0% (0.3–44.5)	3.3% (0.1–17.2)	50.0% (1.3–98.7)	76.3% (59.8–88.6)

Abbreviation: PPV, positive predictive value.

<sup>a</sup>For all imaging, a positive test result is defined as a confidence score of 5 or 6 (see Materials and Methods); for short axis, a positive result is defined in the table, and for size ratio criteria see Materials and Methods.



Rockall et al.

**Table 4.** Estimates of diagnostic performance using the primary reference standard: per patient diagnostic performance among patients with endometrial cancer.

Diagnostic method <sup>a</sup>	No. patients	Confirmed node metastatic disease		Confirmed without nodal disease		Sensitivity (95% CI)	False-positive rate (95% CI)	PPV (95% CI)	NPV (95% CI)
		True +ve	False -ve	True -ve	False +ve				
DW-MRI	78	14 (17.9%)	6 (7.7%)	56 (71.8%)	2 (2.6%)	70.0% (45.7–88.1)	3.4% (0.4–11.9)	87.5% (61.7–98.4)	90.3% (80.1–96.4)
FDG-PET/CT	78	16 (20.5%)	4 (5.1%)	55 (70.5%)	3 (3.8%)	80.0% (56.3–94.3)	5.2% (1.1–14.4)	84.2% (60.4–96.6)	93.2% (83.5–98.1)
FEC-PET/CT	32	7 (21.9%)	1 (3.1%)	23 (71.9%)	1 (3.1%)	87.5% (47.3–99.7)	4.2% (0.1–21.1)	87.5% (47.3–99.7)	95.8% (78.9–99.9)
Diagnosis based on morphology	78	15 (19.2%)	5 (6.4%)	55 (70.5%)	3 (3.8%)	75.0% (50.9–91.3)	5.2% (1.1–14.4)	83.3% (58.6–96.4)	91.7% (81.6–97.2)
Short axis									
>9 mm	78	13 (16.7%)	7 (9.0%)	54 (69.2%)	4 (5.1%)	65.0% (40.8–84.6)	6.9% (1.9–16.7)	76.5% (50.1–93.2)	88.5% (77.8–95.3)
>10 mm	78	11 (14.1%)	9 (11.5%)	54 (69.2%)	4 (5.1%)	55.0% (31.5–76.9)	6.9% (1.9–16.7)	73.3% (44.9–92.2)	85.7% (74.6–93.3)
Size ratio criteria	78	13 (16.7%)	7 (9.0%)	53 (67.9%)	5 (6.4%)	65.0% (40.8–84.6)	8.6% (2.9–19.0)	72.2% (46.5–90.3)	88.3% (77.4–95.2)

Abbreviation: PPV, positive predictive value.

<sup>a</sup>For all imaging, a positive test result is defined as a confidence score of 5 or 6 (see Materials and Methods); for short axis, a positive result is defined in the table, and for size ratio criteria, see Materials and Methods.

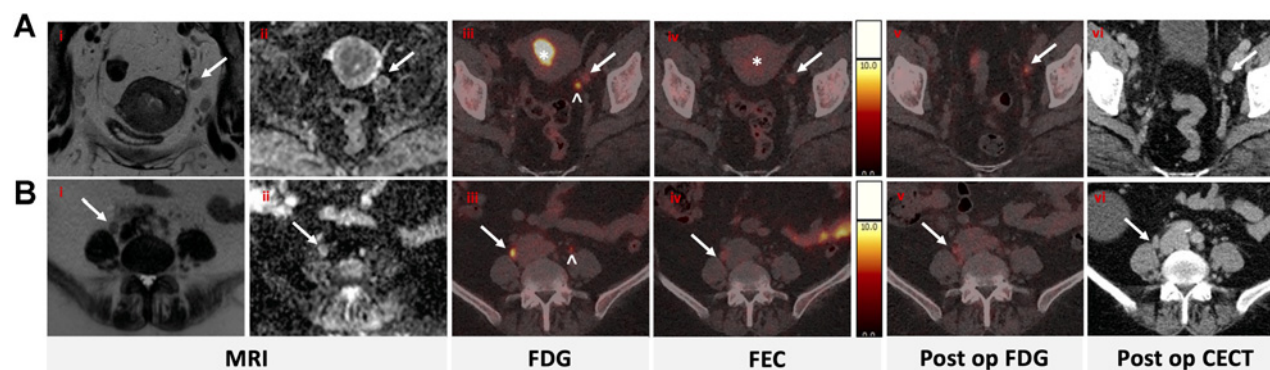
addition, the reference standard for false positive PET cases was not clear: in our study, we reviewed postoperative imaging to ensure the suspicious node was removed, and excluded cases where the suspicious node was still present on postoperative imaging, to ensure an accurate reference standard.

There are only three prospective studies assessing diagnostic accuracy of MRI for LN metastases in endometrial cancer with more than 30 evaluable patients with surgical–pathologic reference standard (including 46, 181, and 220 patients) between 2009 and 2015 (27, 31, 35). The sensitivities using size criteria (short axis >10 mm) for LN metastases were from 75%, 69.2%, and 40% with FPRs of 19%, 6.5%, and 3.5% respectively. More recently a prospective study developing and testing radiomic features to predict nodal involvement has been published and this is an exciting area of future research (36).

In early-stage presumed operable cervical cancer, we found that no imaging method, including DW-MRI, FDG-, or FEC-PET/CT was able to reliably identify nodal metastases in normal sized/nonbulky LNs with sufficient sensitivity. Our results confirm the findings of a single-center prospective cohort (32.1% sensitivity FDG-PET/CT compared with 30.0% in our study), that the role of FDG-PET/CT in staging of early cervical cancer is limited as the prevalence of nodal

involvement is low, and if present, nodal metastases are often small volume and below the sensitivity of PET (37). Although in our cohort 25% (10/40) had at least one positive node, the majority of these nodes were subcentimetre. Importantly, we had no false positive case on FDG-PET/CT in patients with cervix cancer. This information is highly relevant in cases where the choice of surgery may be difficult: a negative FDG-PET/CT could allow a decision for surgery to go ahead, at least for surgical nodal staging, whereas the finding of a positive node could safely and reliably exclude these patients from radical hysterectomy and direct them to chemoradiotherapy. Early data that suggest individual nodal sensitivity of FDG PET/CT in endometrial and cervical cancer could be enhanced by image fusion with DW-MRI with potential complementarity between the modalities but was beyond the scope of our study (38).

There are limitations to our study. Our results are suggestive (but not conclusive) of a difference in diagnostic performance between cervical and endometrial cancer. However, there are insufficient cases to reliably analyse these separately because when the study was designed there were few publications on this, limiting the power calculation. Study recruitment was challenging as patients needed to undertake repeat study MRI for the study diffusion sequence, as well as

**Figure 2.**

A 55-year-old with endometrial carcinoma. Cor/axial T2-weighted MRI (i), axial ADC (ii), axial FDG fused (iii), axial FEC fused (iv) shows focal tracer uptake in an 8-mm rounded left external iliac node (row A, arrows, \* tumor, ^ ureter), and a 9-mm rounded right common iliac node (row B, arrows). Histopathology was negative. Follow-up axial FDG fused (v) and axial contrast-enhanced CT (CECT) (vi) confirmed the nodes were not removed at surgery.

## Imaging in Nodal Staging in Cervix and Endometrial Cancer

study-specific FDG-PET/CT and optional FEC-PET/CT prior to the planned surgery. In addition, many recruited participants did not complete all the imaging as per study protocol, in particular FEC-PET/CT due to logistic challenges of coordinating manufacture timings and radiotracer distribution in a multicenter study with short time-frames for imaging prior to surgery. Several cases could not be evaluated with the primary reference standard as we could not be fully confident that the suspicious node on imaging had been correlated at histology. By having a stringent primary reference standard, we ensured a high likelihood of correlated imaging and nodal histology. However, this led to several patients excluded from the primary analysis, where the suspicious node was not successfully surgically resected. Nevertheless, analyses based on the secondary (follow-up) reference standard were similar to the primary analyses. Although our main analyses were based on 118 patients (less than the target of 150), the sample size was based on the number of histologically confirmed cases with nodal metastasis, and we observed 30 cases, above the target of 19–23.

In conclusion, in this prospective multicenter study with strict histologic reference standard, no imaging technique provided sufficient sensitivity to obviate the need for lymph node dissection in cases where this is considered appropriate, in patients with early-stage operable cervical cancer and in patients with intermediate- to high-risk endometrial cancer. However, the very low false positive rates, in all modalities, could be helpful in treatment planning. In patients with cervical cancer, with borderline appropriateness for radical surgery, MRI findings could be supported by FDG-PET/CT, as false positive scans are highly unlikely and therefore a positive scan would allow avoidance of inappropriate surgery, or could direct surgical resection for confirmation. In patients with endometrial cancer, in cases where there is uncertainty regarding the risk/benefits of lymphadenectomy, confirmatory FDG-PET/CT may add support to MRI to decide on proceeding to surgical nodal dissection, as well as directing the surgical approach.

### Authors' Disclosures

A.G. Rockall reports grants from Cancer Research UK during the conduct of the study. A. Sohaib reports other support from NIHR BRC funding during the conduct of the study. S. Ghaem-Maghani reports grants from Cancer Research UK Charity during the conduct of the study as well as grants from Eve Appeal charity and NIHR outside the submitted work. C. Fotopoulou reports personal fees and other support from Roche, AstraZeneca, Sequana, Tesaro, GSK, MSD, Clovis, and Ethicon outside the submitted work. R. Manchanda reports grants from CRUK, Barts Charity, Eve Appeal, and Rosetrees Trust and other support from GSK and AstraZeneca outside the submitted work. A. Sahdev reports grants from St Bartholomew's Hospital during the conduct of the study. G.J. Cook reports grants from CRUK during the conduct of the study. No disclosures were reported by the other authors.

### Authors' Contributions

A.G. Rockall: Conceptualization, resources, data curation, funding acquisition, validation, investigation, methodology, writing—original draft, writing—review and editing. T.D. Barwick: Data curation, formal analysis, supervision, investigation, methodology, writing—original draft, writing—review and editing, joint first author with equal contribution. W. Wilson: Formal analysis, writing—original draft, writing—review and editing. N. Singh: Formal analysis, funding acquisition, investigation,

methodology, writing—review and editing. N. Bharwani: Funding acquisition, investigation, writing—review and editing. A. Sohaib: Funding acquisition, investigation, writing—review and editing. M. Nobbenhuis: Investigation, writing—review and editing. V. Warbey: Formal analysis, investigation. M. Miquel: Formal analysis, funding acquisition, investigation, writing—review and editing. D.-M. Koh: Funding acquisition, investigation. K.N. De Paepe: Investigation, writing—review and editing. P. Martin-Hirsch: Funding acquisition, investigation, writing—review and editing. S. Ghaem-Maghani: Investigation, writing—review and editing. C. Fotopoulou: Investigation, writing—review and editing. H. Stringfellow: Funding acquisition, investigation, writing—review and editing. S. Sundar: Funding acquisition, investigation, writing—review and editing. R. Manchanda: Investigation, writing—review and editing. A. Sahdev: Investigation, writing—review and editing. A. Hackshaw: Conceptualization, supervision, funding acquisition, methodology, writing—review and editing. G.J. Cook: Conceptualization, supervision, investigation, methodology, writing—original draft, writing—review and editing. **Mapping Study Group:** Resources, funding acquisition, validation, investigation, project administration, writing—review and editing; group authors in the Mapping Study Group are listed in the acknowledgments section and in the supplementary data under participating sites and roles.

### Acknowledgments

The MAPPING study group authors are as follows: Victoria Stewart, Alan Farthing, Maria Kyrgiou, Joseph Yazbek, Roberto Dina, Thomas Ind, Desmond Barton, John Butler, Ayoma Attygalle, Steve Hazell, Alexandra Taylor, Susan Lalondrelle, Imene Zerizer, Diana Rosof-Williams, Mike Dobson, Jonathan Hill, Elly Brockbank, Alexandra Lawrence, Arjun Jeyarajah, David Oram, Raji Ganesan, Peter Guest, Mark Davies, Laura Vosper, Carike Coetzee. We acknowledge the support of Evis Sala, Norbert Avril, Rodney Reznick, Lesley Honeyfield, Richard Edmondson, Neva Patel, Sameer Khan, Lucy Pike, Priya Narayanan, Nicholas Reed, Raj Naik, Shah-Jalal Sarker, Iain McNeish, The authors acknowledge support from Biomarkers and Imaging Discovery and Development (BIDD) Project Grant; Cancer Research UK (chief investigator: A.G. Rockall, C. Coetzee, L. Vosper), National Institute of Health Research Imperial Biomedical Centre and the Imperial Cancer Research UK Centre (to A.G. Rockall, T.D. Barwick, S. Ghaem-Maghani, C. Fotopoulou, M. Kyrgiou), Centre for Experimental Cancer Medicine, Barts Cancer Institute, Queen Mary University of London, London, United Kingdom (to R. Manchanda, M. Miquel, N. Singh, A. Sahdev), National Institute for Health Research Biomedical Research Centre at Guy's & St Thomas' Hospitals and King's College London, King's College London/University College London Comprehensive Cancer Imaging Centre funded by Cancer Research UK and Engineering and Physical Sciences Research Council in association with the Medical Research Council and the Department of Health (C1519/A16463; to G.J. Cook, V. Warbey), National Institute for Health Research (NIHR) Biomedical Research Centre at The Royal Marsden NHS Foundation Trust and the Institute of Cancer Research, London (to A. Sohaib, M. Nobbenhuis, T. Ind, D. Barton, J. Butler, A. Attygalle, S. Hazell, A. Taylor, S. Lalondrelle, I. Zerizer, K.N. De Paepe, D.-M. Koh), Cancer Research UK (C444/A15953), with support from the University College London and University College London Hospital Biomedical Research Centre (to A. Hackshaw), Alliance Medical sites for PET/CT research slots at Lancashire Teaching Hospitals NHS Foundation Trust. The Clinical Trials Units were as follows: Centre for Experimental Cancer Medicine, Barts Cancer Institute, Queen Mary University of London, Barts Health NHS Trust, and Queen Mary University of London Joint Research Management Office.

The costs of publication of this article were defrayed in part by the payment of page charges. This article must therefore be hereby marked *advertisement* in accordance with 18 U.S.C. Section 1734 solely to indicate this fact.

Received May 20, 2021; revised July 14, 2021; accepted September 13, 2021; published first September 15, 2021.

### References

- Morice P, Leary A, Creutzberg C, Abu-Rustum N, Darai E. Endometrial cancer. *Lancet* 2016;387:1094–108.
- Creasman WT, Odicino F, Maisonneuve P, Quinn MA, Beller U, Benedet JL, et al. Carcinoma of the corpus uteri. FIGO 26th Annual Report on the Results of Treatment in Gynecological Cancer. *Int J Gynecol Obstet* 2006; 95:S105–43.
- American Cancer Society. Survival rates for cervical cancer: Cancer facts & figures 2020. Atlanta, GA: American Cancer Society; 2020. Available from: <https://www.cancer.org/cancer/cervical-cancer/detection-diagnosis-staging/survival.html>.
- Pecorelli S. Revised FIGO staging for carcinoma of the vulva, cervix, and endometrium. *Int J Gynecol Obstet* 2009;105:103–4.

## Rockall et al.

5. National Comprehensive Cancer Network. NCCN Guidelines Version 1.2021 Uterine neoplasms 2020. Available from: [https://www.nccn.org/professionals/physician\\_gls/pdf/uterine.pdf](https://www.nccn.org/professionals/physician_gls/pdf/uterine.pdf).
6. Kitchener H, Swart AM, Qian Q, Amos C, Parmar MK. Efficacy of systematic pelvic lymphadenectomy in endometrial cancer (MRC ASTEC trial): a randomised study. *Lancet* 2009;373:125–36.
7. Benedetti Panici P, Basile S, Maneschi F, Alberto Lissoni A, Signorelli M, Scambia G, et al. Systematic pelvic lymphadenectomy vs. no lymphadenectomy in early-stage endometrial carcinoma: randomized clinical trial. *J Natl Cancer Inst* 2008;100:1707–16.
8. Todo Y, Kato H, Kaneuchi M, Watari H, Takeda M, Sakuragi N. Survival effect of para-aortic lymphadenectomy in endometrial cancer (SEPAL study): a retrospective cohort analysis. *Lancet* 2010;375:1165–72.
9. Frost JA, Webster KE, Bryant A, Morrison J. Lymphadenectomy for the management of endometrial cancer. *Cochrane Database Syst Rev* 2017;10: Cd007585.
10. Concin N, Matias-Guiu X, Vergote I, Cibula D, Mirza MR, Marnitz S, et al. ESGO/ESTRO/ESP guidelines for the management of patients with endometrial carcinoma. *Int J Gynecol Cancer* 2021;31:12–39.
11. Fotopoulou C, Lind T, Baldwin P, Crawford R, Devaja O, Dobbs S, et al. Sentinel lymph node consensus document of the British Gynecological Cancer Society for endometrial, vulvar, and cervical cancers. *Int J Gynecol Cancer* 2019;29:1348–50.
12. Reed N, Balega J, Barwick T, Buckley L, Burton K, Eminowicz G, et al. British Gynecological Cancer Society (BGCS) cervical cancer guidelines: recommendations for practice. *Eur J Obstet Gynecol Reprod Biol* 2021;256:433–65.
13. Shen G, Zhou H, Jia Z, Deng H. Diagnostic performance of diffusion-weighted MRI for detection of pelvic metastatic lymph nodes in patients with cervical cancer: a systematic review and meta-analysis. *Br J Radiol* 2015;88:20150063.
14. National Comprehensive Cancer Network. NCCN Guidelines Version 1.2021 Cervical cancer 2020. Available from: [https://www.nccn.org/professionals/physician\\_gls/pdf/cervical.pdf](https://www.nccn.org/professionals/physician_gls/pdf/cervical.pdf).
15. Garau LM, Niccoli-Asabella A, Ferrari C, Sardaro A, Pisani A, Rubini G. The role of 18F-FDG PET/CT in endometrial adenocarcinoma: a review of the literature and recent advances. *Clin Transl Imaging* 2020;8:357–64.
16. Hu J, Zhang K, Yan Y, Zang Y, Wang Y, Xue F. Diagnostic accuracy of preoperative (18)F-FDG PET or PET/CT in detecting pelvic and para-aortic lymph node metastasis in patients with endometrial cancer: a systematic review and meta-analysis. *Arch Gynecol Obstet* 2019;300:519–29.
17. Woo S, Atun R, Ward ZJ, Scott AM, Hricak H, Vargas HA. Diagnostic performance of conventional and advanced imaging modalities for assessing newly diagnosed cervical cancer: systematic review and meta-analysis. *Eur Radiol* 2020;30:5560–77.
18. Contractor K, Challapalli A, Barwick T, Winkler M, Hellawell G, Hazell S, et al. Use of [11C]choline PET-CT as a noninvasive method for detecting pelvic lymph node status from prostate cancer and relationship with choline kinase expression. *Clin Cancer Res* 2011;17:7673–83.
19. Trousil S, Lee P, Pinato DJ, Ellis JK, Dina R, Aboagye EO, et al. Alterations of choline phospholipid metabolism in endometrial cancer are caused by choline kinase alpha overexpression and a hyperactivated deacylation pathway. *Cancer Res* 2014;74:6867–77.
20. Torizuka T, Kanno T, Futatsubashi M, Okada H, Yoshikawa E, Nakamura F, et al. Imaging of gynecologic tumors: comparison of (11)C-choline PET with (18)F-FDG PET. *J Nucl Med* 2003;44:1051–6.
21. Sofue K, Tateishi U, Sawada M, Maeda T, Terauchi T, Kano D, et al. Role of carbon-11 choline PET/CT in the management of uterine carcinoma: initial experience. *Ann Nucl Med* 2009;23:235–43.
22. McMahon CJ, Rofsky NM, Pedrosa I. Lymphatic metastases from pelvic tumors: anatomic classification, characterization, and staging. *Radiology* 2010;254:31–46.
23. Sironi S, Buda A, Picchio M, Perego P, Moreni R, Pellegrino A, et al. Lymph node metastasis in patients with clinical early-stage cervical cancer: detection with integrated FDG PET/CT. *Radiology* 2006;238:272–9.
24. Basaran D, Bruce S, Aviki EM, Mueller JJ, Broach VA, Cadoo K, et al. Sentinel lymph node mapping alone compared to more extensive lymphadenectomy in patients with uterine serous carcinoma. *Gynecol Oncol* 2020;156:70–6.
25. Evangelista L, Guttilla A, Zattoni F, Muzzio PC, Zattoni F. Utility of choline positron emission tomography/computed tomography for lymph node involvement identification in intermediate- to high-risk prostate cancer: a systematic literature review and meta-analysis. *Eur Urol* 2013;63:1040–8.
26. Konuralp Atakul B, Taskin S, Soydal C, Sukur YE, Kahraman A, Koyuncu K, et al. Preoperative 18F-fluorodeoxyglucose positron emission tomography/CT in prediction of uterine risk factors and lymph node metastasis: an analysis of 111 endometrioid endometrial cancer patients. *Gynecol Obstet Invest* 2017;82: 340–8.
27. Antonsen SL, Jensen LN, Loft A, Berthelsen AK, Costa J, Tabor A, et al. MRI, PET/CT and ultrasound in the preoperative staging of endometrial cancer - a multicenter prospective comparative study. *Gynecol Oncol* 2013;128:300–8.
28. Atri M, Zhang Z, Dehdashti F, Lee SI, Marques H, Ali S, et al. Utility of PET/CT to evaluate retroperitoneal lymph node metastasis in high-risk endometrial cancer: results of ACRIN 6671/GOG 0233 trial. *Radiology* 2017;283:450–9.
29. Crivellaro C, Signorelli M, Guerra L, De Ponti E, Pirovano C, Fruscio R, et al. Tailoring systematic lymphadenectomy in high-risk clinical early stage endometrial cancer: the role of 18F-FDG PET/CT. *Gynecol Oncol* 2013; 130:306–11.
30. Husby JA, Reitan BC, Biermann M, Trovik J, Børge L, Magnussen JJ, et al. Metabolic tumor volume on 18F-FDG PET/CT improves preoperative identification of high-risk endometrial carcinoma patients. *J Nucl Med* 2015;56:1191–8.
31. Inubashiri E, Hata K, Kanenishi K, Shiota A, Ohno M, Yamamoto Y, et al. Positron emission tomography with the glucose analog [F]-fluoro-2-deoxy-D-glucose for evaluating pelvic lymph node metastasis in uterine corpus cancer: comparison with CT and MRI findings. *J Obstet Gynecol Res* 2009;35:26–34.
32. Signorelli M, Crivellaro C, Buda A, Guerra L, Fruscio R, Elisei F, et al. Staging of high-risk endometrial cancer with PET/CT and sentinel lymph node mapping. *Clin Nucl Med* 2015;40:780–5.
33. Stewart KI, Chasen B, Erwin W, Fleming N, Westin SN, Dioun S, et al. Preoperative PET/CT does not accurately detect extruterine disease in patients with newly diagnosed high-risk endometrial cancer: a prospective study. *Cancer* 2019;125:3347–53.
34. Reijnen C, Int'Hout J, Massuger L, Strobbe F, Küsters-Vandeveldt HVN, Haldorsen IS, et al. Diagnostic accuracy of clinical biomarkers for preoperative prediction of lymph node metastasis in endometrial carcinoma: a systematic review and meta-analysis. *Oncologist* 2019;24:e880–e90.
35. Ytre-Hauge S, Husby JA, Magnussen JJ, Werner HM, Salvesen OO, Børge L, et al. Preoperative tumor size at MRI predicts deep myometrial invasion, lymph node metastases, and patient outcome in endometrial carcinomas. *Int J Gynecol Cancer* 2015;25:459–66.
36. Yang LY, Siow TY, Lin YC, Wu RC, Lu HY, Chiang HJ, et al. Computer-aided segmentation and machine learning of integrated clinical and diffusion-weighted imaging parameters for predicting lymph node metastasis in endometrial cancer. *Cancers* 2021;13.
37. Signorelli M, Guerra L, Montanelli L, Crivellaro C, Buda A, Dell'Anna T, et al. Preoperative staging of cervical cancer: is 18-FDG-PET/CT really effective in patients with early stage disease? *Gynecol Oncol* 2011;123:236–40.
38. Stecco A, Buemi F, Cassarà A, Matheoud R, Sacchetti GM, Arnulfo A, et al. Comparison of retrospective PET and MRI-DWI (PET/MRI-DWI) image fusion with PET/CT and MRI-DWI in detection of cervical and endometrial cancer lymph node metastases. *Radiol Med* 2016;121:537–45.

# Clinical Cancer Research

## Diagnostic Accuracy of FEC-PET/CT, FDG-PET/CT, and Diffusion-Weighted MRI in Detection of Nodal Metastases in Surgically Treated Endometrial and Cervical Carcinoma

Andrea G. Rockall, Tara D. Barwick, William Wilson, et al.

*Clin Cancer Res* 2021;27:6457-6466. Published OnlineFirst September 15, 2021.

**Updated version** Access the most recent version of this article at:  
doi:[10.1158/1078-0432.CCR-21-1834](https://doi.org/10.1158/1078-0432.CCR-21-1834)

**Supplementary Material** Access the most recent supplemental material at:  
<http://clincancerres.aacrjournals.org/content/suppl/2021/09/15/1078-0432.CCR-21-1834.DC1>

**Cited articles** This article cites 34 articles, 8 of which you can access for free at:  
<http://clincancerres.aacrjournals.org/content/27/23/6457.full#ref-list-1>

**E-mail alerts** [Sign up to receive free email-alerts](#) related to this article or journal.

**Reprints and Subscriptions** To order reprints of this article or to subscribe to the journal, contact the AACR Publications Department at [pubs@aacr.org](mailto:pubs@aacr.org).

**Permissions** To request permission to re-use all or part of this article, use this link <http://clincancerres.aacrjournals.org/content/27/23/6457>.  
Click on "Request Permissions" which will take you to the Copyright Clearance Center's (CCC) Rightslink site.