

Measurement of human abdominal and femoral intravascular adipose tissue blood flow using percutaneous Doppler ultrasound

Lempesis, Ioannis G; Goossens, Gijs H; Manolopoulos, Konstantinos N

DOI:

[10.1080/21623945.2021.1888471](https://doi.org/10.1080/21623945.2021.1888471)

License:

Creative Commons: Attribution (CC BY)

Document Version

Publisher's PDF, also known as Version of record

Citation for published version (Harvard):

Lempesis, IG, Goossens, GH & Manolopoulos, KN 2021, 'Measurement of human abdominal and femoral intravascular adipose tissue blood flow using percutaneous Doppler ultrasound', *Adipocyte*, vol. 10, no. 1, pp. 119-123. <https://doi.org/10.1080/21623945.2021.1888471>

[Link to publication on Research at Birmingham portal](#)

General rights

Unless a licence is specified above, all rights (including copyright and moral rights) in this document are retained by the authors and/or the copyright holders. The express permission of the copyright holder must be obtained for any use of this material other than for purposes permitted by law.

- Users may freely distribute the URL that is used to identify this publication.
- Users may download and/or print one copy of the publication from the University of Birmingham research portal for the purpose of private study or non-commercial research.
- User may use extracts from the document in line with the concept of 'fair dealing' under the Copyright, Designs and Patents Act 1988 (?)
- Users may not further distribute the material nor use it for the purposes of commercial gain.

Where a licence is displayed above, please note the terms and conditions of the licence govern your use of this document.

When citing, please reference the published version.

Take down policy

While the University of Birmingham exercises care and attention in making items available there are rare occasions when an item has been uploaded in error or has been deemed to be commercially or otherwise sensitive.

If you believe that this is the case for this document, please contact UBIRA@lists.bham.ac.uk providing details and we will remove access to the work immediately and investigate.



Measurement of human abdominal and femoral intravascular adipose tissue blood flow using percutaneous Doppler ultrasound

Ioannis G. Lempesis, Gijs H. Goossens & Konstantinos N. Manolopoulos

To cite this article: Ioannis G. Lempesis, Gijs H. Goossens & Konstantinos N. Manolopoulos (2021) Measurement of human abdominal and femoral intravascular adipose tissue blood flow using percutaneous Doppler ultrasound, *Adipocyte*, 10:1, 119-123, DOI: [10.1080/21623945.2021.1888471](https://doi.org/10.1080/21623945.2021.1888471)

To link to this article: <https://doi.org/10.1080/21623945.2021.1888471>



© 2021 The Author(s). Published by Informa UK Limited, trading as Taylor & Francis Group.



Published online: 16 Feb 2021.



Submit your article to this journal [↗](#)



Article views: 498

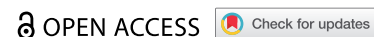

View related articles [↗](#)



View Crossmark data [↗](#)

BRIEF REPORT



Measurement of human abdominal and femoral intravascular adipose tissue blood flow using percutaneous Doppler ultrasound

Ioannis G. Lempesis^{a,b,c}, Gijs H. Goossens^c, and Konstantinos N. Manolopoulos^{a,b}

^aInstitute of Metabolism and Systems Research (IMSR), College of Medical and Dental Sciences, University of Birmingham, Birmingham, UK;

^bCentre for Endocrinology, Diabetes and Metabolism, Birmingham Health Partners, Birmingham, UK; ^cDepartment of Human Biology, NUTRIM School of Nutrition and Translational Research in Metabolism, Maastricht University Medical Centre+, Maastricht, The Netherlands

ABSTRACT

Adipose tissue blood flow (ATBF) is an important determinant of adipose tissue (AT) function. ¹³³Xenon wash-out technique is considered the gold-standard for human ATBF measurements. However, decreasing ¹³³Xenon clinical use and costly production and preservation, make alternative (non-invasive) methods necessary. Here, we explored percutaneous Doppler ultrasound as a proxy method to quantify intravascular subcutaneous abdominal and femoral ATBF in humans ($n = 17$). Both fasting ATBF and the postprandial increase in ATBF were significantly higher in abdominal compared to femoral AT. Although anatomical variations in vein location and depot thickness may impact feasibility, we demonstrate that Doppler ultrasound detects the expected depot-differences and postprandial increase in ATBF in healthy individuals. This method warrants further investigation in other populations and metabolic conditions.

ARTICLE HISTORY

Received 5 October 2020
Revised 3 February 2021
Accepted 6 February 2021

KEYWORDS

Adipose tissue; fat depots; blood flow; Doppler ultrasound; human physiology

Introduction

Tissue-specific regulation of blood flow is needed to meet local physiological demands and to allow proper functioning of organs. Adipose tissue blood flow (ATBF) is an important determinant of adipose tissue (AT) function, as it delivers nutrients and oxygen to AT, exerts a key role in fatty acid trafficking, and distributes adipokines and metabolites into the circulation [1–3]. Under fasting conditions, nitric oxide, adrenergic regulation and the renin-angiotensin system determine ATBF [4,5], while the increase in ATBF following ingestion of a glucose drink or mixed meal is mainly under beta-adrenergic control [1]. Many studies have demonstrated that both fasting and the postprandial enhancement of ATBF are impaired in obesity and insulin-resistant conditions [6–8], thereby contributing to the metabolic perturbations in insulin-resistant individuals with obesity [1,3,7–10]. In line with an important role of ATBF in metabolic regulation, several, but not all, studies have demonstrated a lower ATBF in lower-body compared to upper-body AT [11–13].



The gold-standard method for measuring ATBF is the ¹³³Xenon (¹³³Xe) wash-out technique, first described by Larsen and colleagues in 1966 [14]. The rate of disappearance of the lipid-soluble radioactive

isotope ¹³³Xe, of which a small volume is administered in an area of subcutaneous AT, is used as an indicator of ATBF [10]. Alternative methods to assess subcutaneous ATBF include measurement of ethanol wash-out using microdialysis, laser Doppler flowmetry, and contrast-enhanced ultrasound [10,15–18]. The current reduced availability of ¹³³Xe due to its costly production and declining clinical use, as well as the invasive nature of some of the other techniques implies the need for an alternative, non-invasive method for the measurement of ATBF that can be used in physiological human *in vivo* studies. The aim of the present study, therefore, was to explore intravascular Doppler ultrasound as a proxy method for measuring ATBF in humans, by establishing technical feasibility, reproducibility, and sensitivity of the method to detect ATBF changes in response to an oral glucose drink.

Research design and methods

Study design

Seventeen healthy individuals with no known medical conditions who were non-smokers and not taking any medication participated in the present study. Participants arrived at the Clinical Research Facility in the morning around 08:30 a.m. after an overnight fast

CONTACT Ioannis G. Lempesis  i.lempesis@bham.ac.uk  Institute of Metabolism and Systems Research, University of Birmingham, IBR Tower Level 3, Birmingham B15 2TT, United Kingdom

© 2021 The Author(s). Published by Informa UK Limited, trading as Taylor & Francis Group.

This is an Open Access article distributed under the terms of the Creative Commons Attribution License (<http://creativecommons.org/licenses/by/4.0/>), which permits unrestricted use, distribution, and reproduction in any medium, provided the original work is properly cited.

(at least 10 h fasting). They were advised to abstain from coffee, tea and alcohol, and sports or intense physical activity one day prior to the measurements, but to keep on their usual activities. Following 30 min of rest, two ATBF measurements in abdominal and femoral AT, separated by 5 min, were acquired under fasted conditions. Next, subjects were asked to ingest 75 g of glucose in the form of a pre-made drink (113 ml of Polycal Liquid, Nutricia Ltd, Trowbridge, Wiltshire, UK). Postprandial ATBF responses in abdominal and femoral AT were determined for 120 min at 10 min intervals. Measurements were taken by a single operator and, depending on feasibility, repeated up to three times at each time-point for both AT depots. Femoral ATBF was measured in 11 individuals due to a near-parallel to the skin anatomical course of femoral AT veins resulting in poor Doppler signal. The study was approved by the University of Birmingham Ethics committee and the UK Health Research Authority. All participants provided written informed consent before taking part in the study procedures.

Doppler ultrasound technique

Vessels that specifically drain abdominal subcutaneous AT are branches of the superficial epigastric vein (*V. epigastrica superficialis*), that are located above the inguinal ligament, as determined by using the anterior superior iliac spine and the projected pubic symphysis as reference points [19]. In the present study, the subcutaneous AT areas lateral of the umbilicus and between the lower end of the rib cage and the inguinal ligament were scanned on each side in order to identify suitable veins for ATBF measurements in the abdominal subcutaneous AT depot. In the femoral depot, the great saphenous vein and its branches drain mostly femoral subcutaneous AT [20]. Suitable femoral veins for ATBF measurements were identified by scanning the inner aspect of the thigh, approximately half-way between the groin and the knee. A Philips CX50 ultrasound system (Philips Ultrasound, 22,100 Bothell-Everett Highway, Bothell, WA 98,021-8431, USA) with two different transducers was used for the measurements: Depending on the anatomical location, course and size of the identified veins, a L15-7io broadband compact linear array transducer (Frequency range: 15–7 MHz) and a L12-3 (Frequency range: 12–3 MHz) were used.

The sequence of measurement involved the following steps. One or two suitable subcutaneous veins draining the respective AT depot were identified using a live greyscale imaging mode (2D Mode; [Figure 1\(a\)](#)), and their location was marked on the skin with

a suitable marker for easy identification for measurements later during the study. The insonation angle was checked visually between two projected lines, one corresponding to the skin level and the other running horizontally across the vessel lumen, aiming for it to be less than 70 degrees to ensure an adequate Doppler signal. Flow within the selected vein was visualized using colour or colour power angio (CPA) mode ([Figure 1\(b\)](#)), before switching to pulsed waved (PW) Doppler to obtain the measurement. The quality of the Doppler signal was optimized using proprietary functions of the ultrasound system (iSCAN Intelligent Optimization on the system used in this study). Following the conduction of the PW Doppler measurement, the live image was frozen and flow volume calculations were performed using the ultrasound system's internal algorithms to obtain a time-averaged flow. Importantly, this included measurement of the vessel diameter ([Figure 1\(c\)](#)). During the PW Doppler measurement, great care was taken to apply the lowest possible pressure to the skin with the ultrasound transducer to avoid compression of the vessel, which could affect ATBF.

Statistical analyses

For each time point, mean ATBF was determined from the available repeated measurements. Fasting ATBF was calculated as the mean of time points $t = -5$ - and 0-min. Peak ATBF was defined as the highest value recorded during the measurements' timeframe. Time-averaged area under the curve (iAUC/min) was calculated following the trapezoid rule. Since parameters were not normally distributed (based on Shapiro-Wilk test), the Wilcoxon-Signed Rank test was used to compare fasting and postprandial ATBF within the same AT depot, and to compare ATBF between abdominal and femoral AT. SPSS version 25 and GraphPad Prism version 8 were used to perform statistics, and $p < 0.05$ was considered as statistically significant.

Results

The participant characteristics are shown in [Table 1](#). Briefly, seventeen individuals (12 females, 5 males) with BMI range 19.8–33.8 kg/m² and age range 24–58 years were included in the present study. Of note, only one study participant had obesity (BMI, 33.8 kg/m²) with the BMI range of all other participants being 19.8–24.8 kg/m². Fasting abdominal ATBF was 2.9 ± 0.8 mL/min, which increased to peak levels at 6.9 ± 1.7 mL/min at $t = 90$ min after glucose ingestion ($p = 0.002$ vs. fasting ATBF) ([Figure 2](#)). Femoral ATBF

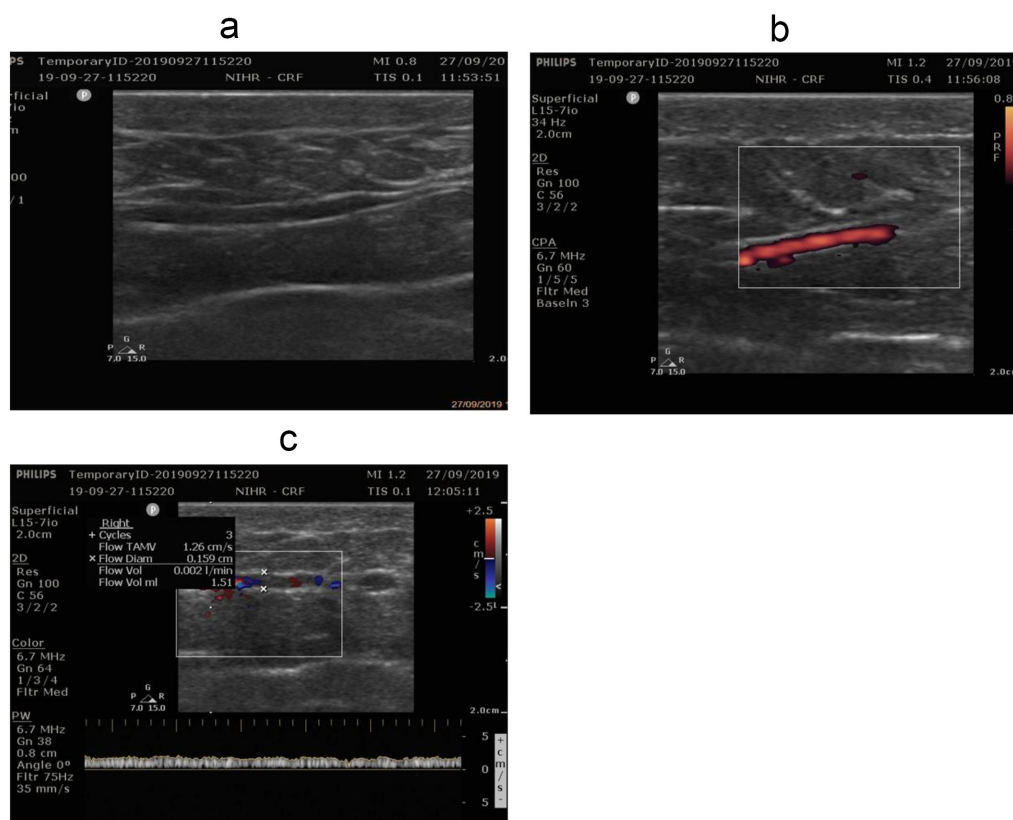


Figure 1. Representative images from the workflow of obtaining an ATBF measurement using Doppler ultrasound. Identification of a suitable subcutaneous adipose tissue vein (a), confirmation of flow signal in colour power angle (PCA) mode (b), followed by measurement of vessel diameter and calculation of ATBF (c).

Table 1. Participants' characteristics.

Sex	5 Males/12 Females
Age (years)	37 (24–58)
Height (m)	1.73 (1.58–1.88)
Weight (kg)	69.1 (49.5–111.4)
BMI (kg/m ²)	22.9 (19.8–33.8)
Waist circumference (cm)	83.4 (68–119)
Hip circumference (cm)	99.4 (89.5–117)
Waist/Hip ratio	0.84 (0.69–1.01)

BMI: Body Mass Index

increased from 1.1 ± 0.3 mL/min under fasting conditions to peak ATBF values of 2.2 ± 0.6 mL/min at $t = 70$ min after glucose ingestion ($p = 0.047$ vs. fasting ATBF).

Fasting ATBF was higher in abdominal compared to femoral AT (2.9 vs. 1.1 mL/min, respectively, $p = 0.033$, $n = 11$ paired measurements). Furthermore, the postprandial increase in ATBF (iAUC/min) was significantly higher in abdominal than femoral AT (2.0 vs. 0.3 mL/min, respectively, $p = 0.033$, $n = 11$ paired measurements). The iAUCs for both abdominal and femoral ATBF were not significantly correlated with BMI (abdominal: $r = -0.018$, $p = 0.945$; femoral: $r = -0.388$, $p = 0.237$) or waist/hip ratio (abdominal: $r = 0.076$, $p = 0.773$; femoral: $r = 0.582$, $p = 0.065$). When

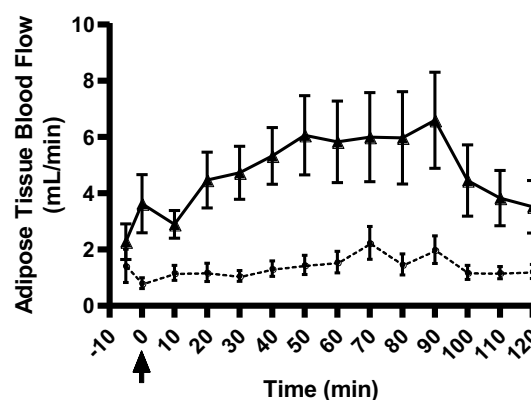


Figure 2. Abdominal (solid line with triangles, $n = 17$) and femoral (dashed line with circles, $n = 11$) adipose tissue blood flow measurements with Doppler ultrasound. A standardized 75 g glucose drink was given at time 0 min (black arrow). ATBF follows the expected postprandial increase for the abdominal adipose tissue depot, peaking at 6.9 ± 1.7 mL/min ($t = 90$ min post-glucose ingestion) ($p = 0.002$ vs. fasting ATBF, $n = 17$). The femoral AT depot showed a less pronounced increase in ATBF to 2.2 ± 0.6 mL/min (peak value at $t = 70$ min post-glucose ingestion) ($p = 0.047$ vs. fasting ATBF, $n = 11$). The postprandial enhancement (iAUC) in abdominal ATBF was more pronounced than in femoral AT ($p = 0.033$, $n = 11$).

examining the individual participants where a femoral ATBF measurement was not possible, there were no notable predictors of poor signal apart from the anatomical considerations outlined above. The coefficient of variation of repeated measurements in abdominal AT was $33 \pm 6\%$ for fasting ATBF and $20 \pm 5\%$ for peak ATBF. For femoral AT, the coefficient of variation of repeated measurements was $39 \pm 7\%$ for fasting ATBF and $51 \pm 11\%$ for peak ATBF.

Discussion

The present study demonstrated that measurement of abdominal and femoral intravascular ATBF with percutaneous Doppler ultrasound is technically feasible. This non-invasive method is able to detect the expected increase in blood flow following oral glucose ingestion in both abdominal and femoral AT in healthy individuals [1–3]. Furthermore, we found that abdominal ATBF was significantly higher than femoral ATBF under fasting conditions. Moreover, the postprandial increase in abdominal subcutaneous ATBF was significantly higher than the ATBF increase in femoral AT. These findings are in agreement with previous studies, in which ATBF was quantified using the gold-standard ^{133}Xe wash-out technique [1,11]. As expected, we found that there is large inter- and intra-individual variability in ATBF, which is commonly observed with ATBF [8] measurements, even when performed using the ^{133}Xe wash-out technique. However, intra-individual coefficients of variation with intravascular Doppler ultrasound seem larger than found with ^{133}Xe wash-out [8].

Important limitations of the method employed in the present study are those inherent to using ultrasound and relate to the quality of the ultrasound image that can be obtained in individual participants. Appropriate operator training paying special attention to the identification of suitable veins that allow acquisition of a high-quality PW Doppler signal is of paramount importance. Low blood flow in small AT veins may further hamper the accuracy of ATBF measurement. These issues become especially noticeable when assessing ATBF in (very) lean participants due to thin subcutaneous fat layers and smaller blood vessels. While the anatomical properties of AT veins, especially in the femoral AT depot, may limit the ability of obtaining a good Doppler signal in every participant of a given study, it is important to note that other available methods also have intrinsic limitations such as exposure to radiation (i.e. PET-tracers, ^{133}Xe wash-out), thereby restricting their applicability. This also holds true for repeated measurements during a clinical study, which is often not possible with PET scans, for example.

Although intravascular Doppler ultrasound may be an alternative method that could be applied to calculate metabolite fluxes across AT in physiological *in vivo* studies in humans, it is important to note that Doppler ultrasound provides data on intravascular blood flow in relatively large AT veins. In contrast, the ^{133}Xe wash-out technique on which the original calculations of metabolic fluxes were based provides ATBF values at the capillary level. Due to the global production stop of medical ^{133}Xe it was not possible to validate the present Doppler measurements against the gold-standard ^{133}Xe wash-out technique. A further limitation of our study is that we did not obtain information on the actual volume of the AT depot measured, e.g. through magnetic resonance imaging or dual x-ray absorptiometry, which could allow for the modelling of whole-depot blood flow values. Finally, we did not measure postprandial glucose and insulin concentrations in this study, although we would not expect to find any different postprandial glucose and insulin responses to previously published data given that all our participants were healthy volunteers [7].

To summarize, the present study demonstrates that AT Doppler ultrasound is a non-invasive method for measuring abdominal and femoral ATBF, that is sensitive enough to detect differences between AT depots as well as the expected postprandial increase in ATBF in healthy individuals. Future studies should explore the feasibility and sensitivity of this method in determining ATBF in other populations, for example individuals with obesity and patients with type 2 diabetes, establish inter-operator variability, and assess the usefulness of the method in combination with volumetric AT measurements as a basis of mathematical models allowing calculation of substrate fluxes across different AT depots.

Acknowledgments

We would like to express our gratitude to the study participants and the team of the NIHR/Wellcome Trust Clinical Research Facility at Queen Elisabeth Hospital Birmingham.

Funding

This work was supported by the European Foundation for the Study of Diabetes (EFSD) under an EFSD/Lilly European Diabetes Research Program grant to G.H.G and K.N.M.; and Maastricht University (The Netherlands) and the University of Birmingham (UK) under a joint PhD scholarship grant to G.H.G and K.N.M.

Contribution statement

K.N.M. conceived and designed research; I.G.L. performed experiments; I.G.L. analyzed data; I.G.L., G.H.G. and K.N.M. interpreted results of experiments; I.G.L. prepared figures and drafted manuscript; I.G.L., G.H.G. and K.N.M. edited and revised manuscript; I.G.L., G.H.G. and K.N.M. approved final version of manuscript.

Disclosure statement

No conflicts of interest, financial or otherwise, are declared by the authors.

Funding

This work was supported by the European Foundation for the Study of Diabetes (EFSD) under an EFSD/Lilly European Diabetes Research Program grant to G.H.G. and K.N.M.; and Maastricht University (The Netherlands) and the University of Birmingham (UK) under a joint PhD scholarship grant to G.H.G. and K.N.M.

References

- [1] Frayn KN, Karpe F. Regulation of human subcutaneous adipose tissue blood flow. *Int J Obes (Lond)*. 2014;38(8):1019–1026.
- [2] Goossens GH. The role of adipose tissue dysfunction in the pathogenesis of obesity-related insulin resistance. *Physiol Behav*. 2008;94(2):206–218.
- [3] Lempesis IG, Van Meijel RLJ, Manolopoulos KN, et al. Oxygenation of adipose tissue: a human perspective. *Acta Physiol*. 2020;228(1):e13298.
- [4] Ardilouze J-L, Fielding Barbara A, Currie Jenny M, et al. Nitric Oxide and β -Adrenergic Stimulation are major regulators of preprandial and postprandial subcutaneous adipose tissue blood flow in humans. *Circulation*. 2004;109(1):47–52.
- [5] Goossens GH, McQuaid SE, Dennis AL, et al. Angiotensin II: a major regulator of subcutaneous adipose tissue blood flow in humans. *J Physiol*. 2006;571(2):451–460.
- [6] Goossens GH, Jocken JWE, Van Baak MA, et al. Short-term β -adrenergic regulation of leptin, adiponectin and interleukin-6 secretion in vivo in lean and obese subjects. *Diabetes Obesity Metab*. 2008;10(11):1029–1038.
- [7] Karpe F, Fielding BA, Ilic V, et al. Impaired postprandial adipose tissue blood flow response is related to aspects of insulin sensitivity. *Diabetes*. 2002;51(8):2467–2473.
- [8] Summers LK, Samra JS, Humphreys SM, et al. Subcutaneous abdominal adipose tissue blood flow: variation within and between subjects and relationship to obesity. *Clin Sci (Lond)*. 1996;91(6):679–683.
- [9] Frayn KN, Humphreys SM. Metabolic characteristics of human subcutaneous abdominal adipose tissue after overnight fast. *Am J Physiol Endocrinol Metab*. 2012;302(4):E468–E475.
- [10] Goossens GH, Karpe F. Human adipose tissue blood flow and micromanipulation of human subcutaneous blood flow. *Methods Mol Biol*. 2008;456:97–107.
- [11] McQuaid SE, Humphreys SM, Hodson L, et al. Femoral adipose tissue may accumulate the fat that has been recycled as VLDL and nonesterified fatty acids. *Diabetes*. 2010;59(10):2465–2473.
- [12] Tan GD, Goossens GH, Humphreys SM, et al. Upper and lower body adipose tissue function: a direct comparison of fat mobilization in humans. *Obesity Res*. 2004;12(1):114–118.
- [13] Vogel MAA, Jocken JWE, Sell H, et al. Differences in upper and lower-body adipose tissue oxygen tension contribute to the adipose tissue phenotype in humans. *J Clin Endocrinol Metab*. 2018;103(10):3688–3697. [jc.2018-00547-jc.2018-00547](https://doi.org/10.1210/clinem.2018-00547).
- [14] Larsen OA, Lassen NA, Quaade F. Blood flow through human adipose tissue determined with radioactive xenon. *Acta Physiol Scand*. 1966;66(3):337–345.
- [15] Emanuel AL, Meijer RI, Muskiet MH, et al. Role of insulin-stimulated adipose tissue perfusion in the development of whole-body insulin resistance. *Arterioscler Thromb Vasc Biol*. 2017;37(3):411–418.
- [16] Goossens GH, Bizzarri A, Venteclef N, et al. Increased adipose tissue oxygen tension in obese compared with lean men is accompanied by insulin resistance, impaired adipose tissue capillarization, and inflammation. *Circulation*. 2011;124(1):67–76.
- [17] Hu D, Remash D, Russell RD, et al. Impairments in adipose tissue microcirculation in type 2 diabetes mellitus assessed by real-time contrast-enhanced ultrasound. *Cir Cardiovasc Imaging*. 2018;11(4). DOI:10.1161/CIRCIMAGING.117.007074
- [18] Wellhöner P, Rolle D, Lönnroth P, et al. Laser-Doppler flowmetry reveals rapid perfusion changes in adipose tissue of lean and obese females. *Am J Physiol Endocrinol Metab*. 2006;291(5):E1025–E1030.
- [19] Frayn KN, Coppack SW, Humphreys SM. Subcutaneous adipose tissue metabolism studied by local catheterization. *Int J Obes Relat Metab Disord*. 1993;17(Suppl 3): S18–21. discussion S22.
- [20] McQuaid SE, Manolopoulos KN, Dennis AL, et al. Development of an arterio-venous difference method to study the metabolic physiology of the femoral adipose tissue depot. *Obesity (Silver Spring, Md)*. 2010;18(5):1055–1058.