

Therapeutic intervention for lower urinary tract obstruction in the fetus

Farrugia, Marie-Klaire; Kilby, Mark

DOI:

[10.1016/j.jpurol.2021.01.034](https://doi.org/10.1016/j.jpurol.2021.01.034)

License:

Creative Commons: Attribution-NonCommercial-NoDerivs (CC BY-NC-ND)

Document Version

Peer reviewed version

Citation for published version (Harvard):

Farrugia, M-K & Kilby, M 2021, 'Therapeutic intervention for lower urinary tract obstruction in the fetus: current evidence and future strategies', *Journal of Pediatric Urology*, vol. 17, no. 2, pp. 193-199.
<https://doi.org/10.1016/j.jpurol.2021.01.034>

[Link to publication on Research at Birmingham portal](#)

General rights

Unless a licence is specified above, all rights (including copyright and moral rights) in this document are retained by the authors and/or the copyright holders. The express permission of the copyright holder must be obtained for any use of this material other than for purposes permitted by law.

- Users may freely distribute the URL that is used to identify this publication.
- Users may download and/or print one copy of the publication from the University of Birmingham research portal for the purpose of private study or non-commercial research.
- User may use extracts from the document in line with the concept of 'fair dealing' under the Copyright, Designs and Patents Act 1988 (?)
- Users may not further distribute the material nor use it for the purposes of commercial gain.

Where a licence is displayed above, please note the terms and conditions of the licence govern your use of this document.

When citing, please reference the published version.

Take down policy

While the University of Birmingham exercises care and attention in making items available there are rare occasions when an item has been uploaded in error or has been deemed to be commercially or otherwise sensitive.

If you believe that this is the case for this document, please contact UBIRA@lists.bham.ac.uk providing details and we will remove access to the work immediately and investigate.

JPU Review:

Therapeutic intervention for lower urinary tract obstruction in the fetus: current evidence and future strategies

Marie-Klaire Farrugia^{1,2}, Mark D Kilby^{3,4}

1. Chelsea & Westminster Hospital NHS Foundation Trust, 369 Fulham Road, London SW10 9NH, UK
2. Imperial College London, Exhibition Road, London SW7 2AZ, UK
3. Fetal Medicine Centre, Birmingham Women's and Children's Foundation Trust, Birmingham, UK. B15 2TG.
4. College of Medical & Dental Sciences, University of Birmingham, B15 2TT, UK.

Corresponding author: Marie-Klaire Farrugia (m.farrugia@nhs.net)

Keywords: fetal; lower urinary tract obstruction, bladder outflow obstruction; renal failure; cystoscopy; antenatal

Abstract

In-utero vesico-amniotic shunting for fetal lower urinary obstruction (LUTO) is known to improve perinatal survival. More recently, studies including centres performing fetal cystoscopy, have suggested benefit on longer-term survival and renal outcome – within the limitations of small numbers and limited follow-up. These interventions carry significant risk, and therefore patient selection, and optimal timing, are key. The aim of this article is to explore ways of improving the accuracy of prenatal diagnosis, and of identifying risk factors for fetal and postnatal renal failure. The next step is that of using established staging and classification systems to select the patient group that may benefit from intervention, based on published outcomes. Several factors come into play when selecting the timing of intervention, especially if the aim is that of renal, and not only pulmonary, preservation. Lastly, current technologies and their shortfalls are discussed.

Introduction

Lower urinary tract obstruction (LUTO), most commonly caused by posterior urethral valves (PUV) is a life-long condition, continuously evolving from fetal development through the neonatal period, childhood, adolescence and adulthood. As with many pathologies that affect the fetus, the impact in-utero is variable and the postnatal outcome is difficult to predict [1]. Patients with congenital LUTO may have varying degrees of urinary tract dilatation, renal function impairment or altered bladder dynamics. Hence, selecting the right candidate for fetal intervention, with the aim of altering this outcome, remains challenging. Several factors come

into play when deciding whether a fetus with LUTO could benefit from intervention. Firstly, there are multiple underlying aetiologies of LUTO, other than PUV - including urethral atresia and prune belly syndrome, and it is likely that these distinct causes have variable pathophysiologic impact on renal development [2]. Secondly, the variation in degree of obstruction, and its effect on renal morphogenesis, makes patient selection and timing of intervention, more challenging [3]. Third, while obstructive uropathy contributes to abnormal kidney development, and may be reversible, primary congenital dysplasia, such as renal hypoplasia and cystic dysplasia, may not be [4]. In fact, fetal LUTO forms part of the CAKUT (congenital anomalies of the kidney and urinary tract) spectrum [5].

This review aims to update our knowledge of current techniques and outcomes, as a basis for multidisciplinary collaboration and evidence-based discussions when counselling parents and, in specialised centres, when recommending intervention. The focus will be on:

1. Improving the accuracy of prenatal diagnosis
2. Better prediction of postnatal renal function
3. Staging of fetal LUTO with the aim of selective intervention
4. Postnatal outcomes of fetal intervention
5. Definition of an intervention timing “window”
6. Current technology and future directions

1. Improving the accuracy of prenatal diagnosis

The antenatal diagnosis of LUTO is classically based on ultrasound identification of a dilated/thick-walled bladder, bilateral hydronephrosis, dilated ureters and a visible posterior urethra (also known as the “*keyhole sign*”) (Figure 1). A multicenter case-control study, published in 2015, showed that even with strict ultrasound criteria (fetal megacystis, increased bladder-wall thickness, bilateral hydronephrosis and oligohydramnios), postnatal outcome revealed a 23% rate of false-positive diagnoses[6]. The definition of fetal megacystis during the first trimester is a longitudinal bladder diameter (LBD) greater than 7 mm. Beyond the 14th week of gestation, various and miscellaneous criteria have been reported in the literature to define megacystis, ranging from a bladder length >99th percentile for gestational age (in absence of a nomogram), to the most commonly used definition of a fetal bladder failing to empty during a period of 45 minutes ultrasound examination[7]. Fontanella et al. sought to improve diagnostic accuracy of LUTO by designing a clinical score, whereby the optimal bladder volume cut-off for prediction of LUTO was 35 cm³[8]. The clinical score included fetal sex, degree of bladder distension, ureteral size, severe oligo- or anhydramnios and gestational age at referral. The combination of these five variables demonstrated good accuracy in discriminating LUTO from non-obstructive megacystis (Table 1).

The use of fetal magnetic resonance imaging (MRI) is becoming more prevalent [9]. The imaging fusion of real time US and MRI is feasible and may improve the fetal diagnosis of LUTO. Werner et al. published their technique of creating a three-dimensional (3D) model created from antenatal MRI images. The authors published 3D “virtual cystoscopy” images showing clear visualization of the urethral lumen, distended bladder, and hydroureter, although the actual PUV could not be demonstrated [10].

Fetal cystoscopy can be used both as diagnostic and therapeutic tool for the management of LUTO. In fact, fetal cystoscopy can allow the direct visualization of the urethra, and both the eventual confirmation and ablation of PUV (Figure 2). Although technically challenging to perform and not therapeutic in fetuses with urethral atresia, fetal cystoscopy may yield high sensitivity (100%) and specificity (85.7%) for confirming PUV[11].

2. More accurate prediction of fetal and postnatal renal function

The prediction of fetal renal function is currently based on ultrasound appearances of the fetal renal cortex, amniotic fluid volume and fetal urine biochemistry. A 2009 systematic review by Morris et al. supported the predictive value of increased parenchymal echogenicity and renal cystic changes on postnatal serum creatinine[12]. Oligohydramnios at the time of LUTO diagnosis was predictive of poor neonatal renal function. In a study of 101 fetuses with LUTO, of whom 40 (39.6%) had an eGFR less than 60 postnatally – Duin et al. also showed that renal cortical “echogenicity” and reduced amniotic fluid volume were the best predictors[13]. A further study revealed that fetal bladder re-filling after vesicocentesis was the only predictor of “intrauterine fetal renal failure”, with a cut-off <27%[14].

The presence of “normal” amniotic fluid at diagnosis, is not always a positive predictor. The North American Fetal Therapy Network (NAFTNet) carried out a retrospective review of 32 consecutive pregnancies with LUTO with normal mid-gestational amniotic fluid volume[15]. Perinatal survival was 97%. Follow-up was available for 25 patients (78%), of whom one-third

underwent renal replacement therapy (RRT). Development of late oligohydramnios or cortical renal cysts, a diagnosis of PUV, prematurity, and prolonged neonatal intensive care unit stay were associated with need for RRT. Nassr et al. reviewed the outcome of fetuses with LUTO and normal amniotic fluid volume in second trimester of pregnancy[16]. Eleven of 18 fetuses (61.1%) developed oligohydramnios in the third trimester. Of those who survived to 2 years, 14.3% had normal renal function; 57.1% had developed chronic kidney disease; and 28.6% had ESRD. This study again suggests that mid-gestation normal amniotic fluid volume may not predict normal renal function in childhood.

The effectiveness of fetal urinary biochemical markers to predict renal function remains controversial. A 2018 study by Dreux et al. demonstrated an association between fetal urine sodium, calcium and β -2 microglobulin and long term renal function in LUTO survivors[17]. Fetal urine β -2 microglobulin was shown to predict decreased glomerular number, while fetal serum β -2 microglobulin has been associated with renal dysplasia - as well as clinically correlating to postnatal serum creatinine. However, Nassr et al. failed to show an association between ultrasonographic renal parameters and urine biochemistry[16]. No correlation between renal echogenicity, cortical cysts, severe oligohydramnios and the fetal urinary concentration of sodium, chloride, calcium, osmolality and beta2-microglobulin was identified [16].

Urinary *peptidome* analysis has emerged as a helpful tool for the discovery and validation of biomarkers of renal disease, both in adults and in children. In the setting of PUV, Buffin-Meyer et al. identified a fetal urinary peptide signature called 12PUV that predicted postnatal renal function in fetuses with suspected PUV, outperforming routine ultrasound and fetal urine biochemistry[18]. The validity of these findings was confirmed in 25 fetuses with suspected PUV shunted in pregnancy[19]. PUV was confirmed postnatally in 23 patients. Of those 23 fetuses, 14 survivors were analysed. The primary outcome was early renal failure, defined by an eGFR < 60 mL/min/1.73 m² before 6 months of age or pre- or perinatal death. Results confirmed that the peptide signature predicted postnatal renal outcome in postnatally confirmed PUV fetuses with an accuracy of 90%; and in suspected PUV cases with an accuracy of 84% [19].

3. Staging of fetal LUTO with the aim of selective intervention

The PLUTO trial was the first prospective open-labelled randomised controlled trial designed to evaluate the effectiveness of VAS compared to conservative management in fetal LUTO [20]. It prematurely ended in 2010 because of lower than predicted recruitment. However, even with the smaller numbers recruited, it demonstrated improved survival to 28 days, 1 year, and 2 years, in fetuses actually treated with VAS compared to those with conservative management. There was however, an overall poor postnatal prognosis (in terms of long-term childhood renal morbidity) irrespective of whether or not VAS was placed. In retrospect – the case selection for intervention may have targeted those fetuses with significant renal impairment at the time of randomization, and therefore better patient selection may alter the outcome.

Ruano et al. has also proposed a prenatal staging system which classifies LUTO into four stages (Table 2) based on severity at presentation, correlated with postnatal outcomes in a

single center retrospective study[21][22]. Fetuses presenting with LUTO and an associated anomaly (complex) tend to have poor outcomes and are therefore not considered candidates for fetal therapy.

Stage I LUTO is characterized by bladder dilatation and bilateral hydronephrosis, but normal levels of amniotic fluid and favorable fetal urine biochemistry. Fetuses diagnosed with stage I LUTO are unlikely develop pulmonary hypoplasia or end stage renal disease (ESRD); postnatal survival rate is almost 100%. Fetal intervention is therefore not indicated. The authors recommend weekly ultrasound monitoring, and re-assessment if there is progression to Stage II [23].

Stage II LUTO is associated with decreasing amniotic fluid levels or established oligo/ anhydramnios, after 18 weeks of gestation. Typical ultrasound findings are echogenic kidneys without renal cortical cysts. Results from fetal urine biochemistry (3 samples over 24-48 hours) should fall into the 'favorable' category (urinary sodium < 100mEq/L, chloride < 90mEq/L, osmolality <200mOsm/L and beta2-microglobulin <6mg/L). The authors recommend fetal intervention for this stage of LUTO, with the objective of preventing both severe pulmonary hypoplasia and ESRD (Figure 3).

Stage III LUTO is characterized by severe oligohydramnios / anhydramnios, and "echogenic" kidneys with cysts. Urine biochemistries demonstrate poor renal function with minimal bladder filling rate after vesicocentesis. Although VAS may improve perinatal survival, it would not affect renal function outcomes or longer-term survival. Fetal cystoscopy is not indicated due to the relatively small size of the fetal bladder [23].

Stage IV represents in-utero renal failure and carries a poor prognosis. Ultrasound findings are that of severe renal dysplasia with anuria and a bladder filling rate $\leq 27\%$. No intervention is recommended for these cases; instead, palliative care or termination of pregnancy is the current management option[22].

A retrospective study from eight centres in the Netherlands proposed an alternative staging of fetal LUTO (Table 3)[24]. All cases were managed conservatively, and the first year eGFR assessed – with the aim of predicting postnatal survival and renal function. The authors found that gestational age at onset of oligohydramnios was the best predictor of perinatal mortality, with an optimal cut-off at 26 weeks' gestation. Fetuses with normal amniotic fluid volume at 26 weeks' gestation were low risk. Before 26 weeks, the bladder volume (BV) was the best predictor of perinatal mortality. ROC curve analysis identified a BV of $\geq 5.4 \text{ cm}^3$ and appearance of oligohydramnios at 20 weeks, as the best threshold for predicting an adverse outcome. LUTO cases with a BV $\geq 5.4 \text{ cm}^3$ or abnormal AF volume at 20 weeks' gestation were defined as severe, whereas those with BV $< 5.4 \text{ cm}^3$ and normal AF volume at the 20 weeks' scan were defined as moderate [24]. Risk of perinatal mortality in the low/ moderate and severe groups was 9%, 26% and 55% respectively, whereas risk of severe renal impairment was 11%, 31% and 44% respectively.

Smith-Harrison et al. proposed an alternative algorithm for fetal intervention focussing on the presence of low amniotic fluid volume (AFI $\geq 5\text{cm}$), favourable urine biochemistry, with the addition of pulmonary maturity evaluation, so that intervention would only be indicated where lungs are still immature[25]. The authors propose early delivery where lung maturity permits, although evidence for this approach is not currently available.

4. Postnatal Outcomes of fetal intervention

Following implementation of the Ruano classification system, the Texas Children's Hospital group performed a retrospective review evaluating the relationship between LUTO stage and postnatal outcome[22]. The authors specifically explored the outcome of VAS in Stage II LUTO between 18 and 30 weeks' gestation; 14 patients met the criteria. Mean gestational age at delivery was 33+4 weeks. At 6 months follow-up, survival was 86%, and 67% had normal renal function. Multivariate analysis revealed that fetal intervention, absence of anhydramnios or renal cortical cysts, and favourable fetal urine biochemistry, were the best predictors of survival.

A 2017 systematic review and meta-analysis of the postnatal outcome of VAS alone, analysed 423 abstracts, of which nine studies were eligible for inclusion. These studies included 112 fetuses treated with VAS and 134 managed conservatively – no uniform selection criteria were implemented. Although the data demonstrated an improvement in perinatal survival, there was no difference in 6–12-month survival or 2-year survival[26].

A 2020 systematic review and meta-analysis of 10 articles on antenatal intervention (both VAS and fetal cystoscopy) for LUTO included 355 fetuses[27]. Perinatal survival was higher in the VAS group (57%) versus control (39%)[27]. In a sub-group analysis, survival was higher in shunted fetuses with unfavourable fetal urine biochemistry. Five studies reported on postnatal renal function between 6 months and 2 years and suggested improved postnatal renal function in the VAS group compared to the conservative group. Fetal cystoscopy was performed in only two included studies. Overall, 45 fetuses underwent fetal cystoscopy. The perinatal survival was higher in the cystoscopy group compared to the conservative management group. Normal renal function was noted in only 13/34 fetuses (38%) in the cystoscopy group versus 12/61 (16%) in the conservative management group at 6 months follow-up[27].

Monteiro et al. published the postnatal neurodevelopmental (ND) outcome of LUTO based on the Ruano prenatal staging system[28]. Twenty male infants with LUTO were classified prenatally in Stages I-III and assessed in 5 developmental domains (physical, adaptive behaviour, social-emotional, cognitive, and communication). No differences in GA at delivery were detected between the groups. Outcomes were correlated with need for dialysis or transplantation postnatally. Mean age at testing was 20.3 ± 12.3 months. Fifteen of the 20 patients (75%) had no ND delays. Of the 5 patients with ND delays, 4 received dialysis. No differences in ND outcomes between infants with LUTO Stage I and those with Stages II and III were detected. Infants who received dialysis showed 15-fold increased risk for delayed socio-emotional development [28].

Fetal intervention is not a risk-free endeavour. Four of 15 pregnancies were lost in the PLUTO trial: an Intrauterine death at 16 weeks' gestation; termination of pregnancy at 17 and 22 weeks due to chorioamnionitis; and a blocked shunt at 19 weeks[20]. Preterm labour occurred in 7/12 livebirths, but the incidence of prematurity did not differ from the conservative management group. A retrospective study of 48 procedures (23 FC, 25 VAS) reported a striking complication rate (74 vs. 92%) for both procedures. The main maternal complication was premature rupture of membranes (25% with FC, 33% with VAS). Fetal complications

occurred in 54% of procedures: shunt migration (38% of VAS cases), omentum or bowel herniation (25% in both VAS and FC cases), urinoma with urethral-perineal fistula (25% of FC cases). Rare complications included muscular hematoma and bowel perforation (FC). The technical failure rate of FC was 30% and a secondary procedure (VAS or FC) was necessary in 5 out of 21 cases of the FC group (24%)[29].

5. Defining a gestational age intervention “window”

The ideal gestational window of opportunity is not well-defined. Fetal pulmonary and renal development are co-dependent: normal lung development requires amniotic fluid, perhaps as a mechanical stenting force, or as a source of growth factors. During the canalicular phase of lung development (17–26 weeks' gestation), the airway branching pattern is complete and the prospective gas-exchange region starts to develop. Respiratory bronchioli appear, interstitial tissue decreases, vascularisation of peripheral mesenchyme increases, and the differentiation of the cuboidal epithelium into type I and type II cells signals the start of surfactant production. In the saccular (terminal sac) phase (24–36 weeks) the growth of the pulmonary parenchyma and further maturation of the surfactant system are the most important steps towards ex-utero life[30]. Oligohydramnios before 26 weeks' gestation will result in pulmonary hypoplasia and a poor prognosis [31][24]. Therefore, intervention before 26 weeks would give the best potential of lung preservation.

The ideal timing for renal functional preservation is difficult to determine. It is well established in the fetal lamb model, that even a reproducible degree of partial urethral obstruction will cause a huge variation in kidney pathology within days. Whereas some kidneys may suffer little or no change, in others, the cortex contained cysts, some with glomerular tufts, and dilated medullary ducts[4]. Samnakay et al. looked into renal histology at different stages post-urethral obstruction in the fetal lamb model[32]. Early cystic changes, with dilatation of ureteric buds and glomerular spaces, were evident in fetal kidneys two days after bladder outflow obstruction. By five days post-obstruction, cystic dilatation was more prominent; and after 10 days, there was architectural disorganization of the renal cortex – with progression to cystic renal dysplasia [32]. It is not known whether these changes could be reversed by stopping the obstructive process. Therefore, the only recommendation that can be given is to intervene before signs of cystic renal dysplasia and fetal renal failure ensue.

6. Current technology and future directions

Fetal cystoscopy using a flexible fetoscope, has been utilized for both diagnosis and treatment if LUTO. The procedure can be technically challenging due to the axis of the fetal bladder and urethra which makes navigation of the fetoscope difficult. In an elegant study using fetal MRI, Vinit et al. found that the bladder neck angle is approximately 15° higher in LUTO fetuses and the angle between the posterior urethra and the bladder axis averages 117°. The development of a customized fetal cystoscope should help overcome the current technical challenges of FC [33].

There is considerable scope for improving vesicoamniotic shunt technology, in order to minimize complications of shunt dislodgement and blockage occurring in approximately 20%

of cases[20]. There has not been an innovation in shunt design in several years. There is concern that the shunt itself may cause bladder wall thickening and fibrosis [34]. Kitagawa et al. explored the option of a “valved” shunt, hypothesizing it would preserve the filling/emptying cycle of a normal bladder[35]. TA fetal lamb study suggested that low-pressure shunts preserved both bladder volume and renal development, as well as lung volumes [36]. This is an area where fetal cystoscopy and treatment of the obstruction without an indwelling device, would have the advantage of preserving bladder cycling.

Kurtz et al. designed a dumb-bell shaped silicone nitinol stent which aims to reduce dislodgement and clogging, leaving a fetal vesicostomy which may be able to delay treatment of PUV[37]. The prototype is woven in such a way that the thinner saddle in the middle is flanked by self-expanding soft flanges that serve to create a self-retaining system.

Conclusion

Current evidence shows improved perinatal survival, with the potential of longer-term survival and renal functional preservation, with fetal intervention for LUTO. The underlying challenges include the accurate antenatal diagnosis of the cause of obstruction, patient selection, and mode and timing of intervention. Smaller studies show a possible benefit of fetal cystoscopy over VAS, but the procedure is technically demanding and has a high complication rate. Improved prenatal diagnosis accuracy, and better patient selection with the aim of intervention before renal failure ensues, may result in better outcomes.

References

- [1] Farrugia MK. Fetal bladder outlet obstruction: Embryopathology, in utero intervention and outcome. *J Pediatr Urol* 2016;12:296–303. doi:10.1016/j.jpuiol.2016.05.047.
- [2] Malin G, Tonks a. M, Morris RK, Gardosi J, Kilby MD. Congenital lower urinary tract obstruction: A population-based epidemiological study. *BJOG An Int J Obstet Gynaecol* 2012;119:1455–64. doi:10.1111/j.1471-0528.2012.03476.x.
- [3] Cheung KW, Morris RK, Kilby MD. Congenital urinary tract obstruction. *Best Pract Res Clin Obstet Gynaecol* 2019. doi:10.1016/j.bpobgyn.2019.01.003.
- [4] Farrugia M-K, Long D a, Godley ML, Peebles DM, Fry CH, Cuckow PM, et al. Experimental short-term fetal bladder outflow obstruction: I. Morphology and cell biology associated with urinary flow impairment. *J Pediatr Urol* 2006;2:243–53. doi:10.1016/j.jpuiol.2006.01.019.
- [5] Farrugia M-K, Woolf AS. Congenital Urinary Bladder Outlet Obstruction. *Fetal Matern Med Rev* 2010;21:55. doi:10.1017/S0965539509990192.
- [6] Fontanella F, Duin L, Adama van Scheltema PN, Cohen-Overbeek TE, Pajkrt E, Bekker M, et al. Fetal megacystis: prediction of spontaneous resolution and outcome. *Ultrasound Obstet Gynecol* 2017. doi:10.1002/uog.17422.
- [7] Liao a. W, Sebire NJ, Geerts L, Cicero S, Nicolaides KH. Megacystis at 10-14 weeks of gestation: Chromosomal defects and outcome according to bladder length. *Ultrasound Obstet Gynecol* 2003;21:338–41. doi:10.1002/uog.81.
- [8] Fontanella F, Duin LK, Adama van Scheltema PN, Cohen-Overbeek TE, Pajkrt E, Bekker M, et al. Prenatal diagnosis of LUTO: improving diagnostic accuracy. *Ultrasound Obstet Gynecol* 2018. doi:10.1002/uog.18990.
- [9] Chalouhi GE, Millischer AÉ, Mahallati H, Siauve N, Melbourne A, Grevent D, et al.

- The use of fetal MRI for renal and urogenital tract anomalies. *Prenat Diagn* 2020. doi:10.1002/pd.5610.
- [10] Werner H, Lopes J, Ribeiro G, Jésus NR, Santos GR, Alexandria HAF, et al. Three-dimensional virtual cystoscopy: Noninvasive approach for the assessment of urinary tract in fetuses with lower urinary tract obstruction. *Prenat Diagn* 2017. doi:10.1002/pd.5188.
 - [11] Ruano R, Duarte S, Bunduki V, Giron AM, Srougi M, Zugaib M. Fetal cystoscopy for severe lower urinary tract obstruction--initial experience of a single center. *Prenat Diagn* 2010;30:30–9. doi:10.1002/pd.2418.
 - [12] Morris RK, Malin GL, Khan KS, Kilby MD. Systematic review of the effectiveness of antenatal intervention for the treatment of congenital lower urinary tract obstruction. *BJOG An Int J Obstet Gynaecol* 2010;117:382–90. doi:10.1111/j.1471-0528.2010.02500.x.
 - [13] Duin LK, Fontanella F, Groen H, Adama van Scheltema PN, Cohen-Overbeek TE, Pajkrt E, et al. Prediction model of postnatal renal function in fetuses with lower urinary tract obstruction (LUTO)—Development and internal validation. *Prenat Diagn* 2019. doi:10.1002/pd.5573.
 - [14] Ruano R, Safdar A, Au J, Koh CJ, Gargollo P, Shamshirsaz AA, et al. Defining and predicting 'intrauterine fetal renal failure' in congenital lower urinary tract obstruction. *Pediatr Nephrol* 2016. doi:10.1007/s00467-015-3246-8.
 - [15] Johnson MP, Danzer E, Koh J, Polzin W, Harman C, O'Shaughnessy R, et al. Natural History of Fetal Lower Urinary Tract Obstruction with Normal Amniotic Fluid Volume at Initial Diagnosis. *Fetal Diagn Ther* 2018. doi:10.1159/000478011.
 - [16] Nassr AA, Koh CK, Shamshirsaz AA, Espinoza J, Sangi-Haghpeykar H, Sharhan D, et al. Are ultrasound renal aspects associated with urinary biochemistry in fetuses with lower urinary tract obstruction? *Prenat Diagn* 2016. doi:10.1002/pd.4958.
 - [17] Spaggiari E, Stirnemann JJ, Benedetti S, Dreux S, Salomon LJ, Blanc T, et al. Comparison of biochemical analysis of fetal serum and fetal urine in the prediction of postnatal renal outcome in lower urinary tract obstruction. *Prenat Diagn* 2018. doi:10.1002/pd.5263.
 - [18] Buffin-Meyer B, Klein J, Breuil B, Muller F, Moulos P, Groussolles M, et al. Combination of the fetal urinary metabolome and peptidome for the prediction of postnatal renal outcome in fetuses with PUV. *J Proteomics* 2018. doi:10.1016/j.jprot.2018.06.012.
 - [19] Buffin-Meyer B, Tkaczyk M, Stańczyk M, Breuil B, Siwy J, Szaflik K, et al. A single-center study to evaluate the efficacy of a fetal urine peptide signature predicting postnatal renal outcome in fetuses with posterior urethral valves. *Pediatr Nephrol* 2020. doi:10.1007/s00467-019-04390-9.
 - [20] Morris RK, Malin GL, Quinlan-Jones E, Middleton LJ, Hemming K, Burke D, et al. Percutaneous vesicoamniotic shunting versus conservative management for fetal lower urinary tract obstruction (PLUTO): a randomised trial. *Lancet* 2013;382:1496–506. doi:10.1016/S0140-6736(13)60992-7.
 - [21] Ruano R, Sananes N, Wilson C, Au J, Koh CJ, Gargollo P, et al. Fetal Lower Urinary Tract Obstruction - A proposal of Standardized Multidisciplinary Prenatal Management based on Disease Severity. *Ultrasound Obstet Gynecol* 2015:n/a-n/a. doi:10.1002/uog.15844.
 - [22] Ruano R, Sananes N, Wilson C, Au J, Koh CJ, Gargollo P, et al. Fetal lower urinary tract obstruction: proposal for standardized multidisciplinary prenatal management based on disease severity. *Ultrasound Obstet Gynecol* 2016. doi:10.1002/uog.15844.
 - [23] Ruano R, Dunn T, Braun MC, Angelo JR, Safdar A. Lower urinary tract obstruction: fetal intervention based on prenatal staging. *Pediatr Nephrol* 2017. doi:10.1007/s00467-017-3593-8.
 - [24] Fontanella F, van Scheltema PNA, Duin L, Cohen-Overbeek TE, Pajkrt E, Bekker MN, et al. Antenatal staging of congenital lower urinary tract obstruction. *Ultrasound Obstet Gynecol* 2019. doi:10.1002/uog.19172.

- [25] Smith-Harrison L, Hougen HY, Timberlake MD, Corbett ST. Current applications of in utero intervention for lower urinary tract obstruction. *J Pediatr Urol* 2015. doi:10.1016/j.jpurol.2015.07.012.
- [26] Nassr AA, Shazly SAM, Abdelmagied AM, Araujo Júnior E, Tonni G, Kilby MD, et al. Effectiveness of vesicoamniotic shunt in fetuses with congenital lower urinary tract obstruction: an updated systematic review and meta-analysis. *Ultrasound Obstet Gynecol* 2017. doi:10.1002/uog.15988.
- [27] Saccone G, D'Alessandro P, Escolino M, Esposito R, Arduino B, Vitagliano A, et al. Antenatal intervention for congenital fetal lower urinary tract obstruction (LUTO): a systematic review and meta-analysis. *J Matern Neonatal Med* 2020. doi:10.1080/14767058.2018.1555704.
- [28] Monteiro S, Nassr AA, Yun PS, Voigt R, Koh CJ, Roth DR, et al. Neurodevelopmental Outcome in Infants with Lower Urinary Tract Obstruction Based on Different Degrees of Severity. *Fetal Diagn Ther* 2020. doi:10.1159/000504977.
- [29] Vinit N, Gueneuc A, Bessi eres B, Dreux S, Heidet L, Salomon R, et al. Fetal Cystoscopy and Vesicoamniotic Shunting in Lower Urinary Tract Obstruction: Long-Term Outcome and Current Technical Limitations. *Fetal Diagn Ther* 2020. doi:10.1159/000500569.
- [30] Copland I, Post M. Lung development and fetal lung growth. *Paediatr Respir Rev* 2004. doi:10.1016/S1526-0542(04)90049-8.
- [31] Shipp TD. Outcome of singleton pregnancies with severe oligohydramnios in the second and third trimesters. *Ultrasound Obstet Gynecol* 1996. doi:10.1046/j.1469-0705.1996.07020108.x.
- [32] Samnakay N, Orford J, Barker A, Charles A, Terry P, Newnham J, et al. Timing of morphologic and apoptotic changes in the sheep fetal kidney in response to bladder outflow obstruction. *J Pediatr Urol* 2006. doi:10.1016/j.jpurol.2006.05.007.
- [33] Vinit N, Grevent D, Millischer-Bellaiche AE, Pandya VM, Sonigo P, Delmonte A, et al. Biometric and morphological features on magnetic resonance imaging of fetal bladder in lower urinary tract obstruction: new perspectives for fetal cystoscopy. *Ultrasound Obstet Gynecol* 2020. doi:10.1002/uog.20297.
- [34] Kitagawa H, Seki Y, Nagae H, Aoba T, Manabe S, Ooyama K, et al. Valved shunt as a treatment for obstructive uropathy: Does pressure make a difference? *Pediatr Surg Int* 2013. doi:10.1007/s00383-012-3249-5.
- [35] Nagae H, Kitagawa H, Pringle KC, Koike J, Zuccollo J, Sato Y, et al. Pressure-limited vesico-amniotic shunt tube for fetal obstructive uropathy. *J Pediatr Surg* 2006;41:2086–9. doi:10.1016/j.jpedsurg.2006.08.012.
- [36] Tanaka K, Koike J, Obayashi J, Seki Y, Nagae H, Pringle K, et al. Pressure limited vesico-amniotic shunt allows normal lung growth in a fetal lamb model of obstructive uropathy. *J Pediatr Surg* 2015;In print.
- [37] Kurtz MP. Improving the vesicoamniotic shunt for fetal lower urinary tract obstruction. *Dialogues Paediatr Urol* 2020.
- [38] Kilby MD, Morris RK. Fetal therapy for the treatment of congenital bladder neck obstruction. *Nat Rev Urol* 2014. doi:10.1038/nrurol.2014.132.

Table 1. Clinical score for antenatal diagnosis of LUTO[24]

US signs	Points
Severe megacystis (volume > 35 cm³ or ascites)	4
Bilateral ureteral diameters	1.3 for each mm of ureteral size
Oligo- or anhydramnios	4
Fetal sex (male)	4
Referral before the 28th week	4

	Risk of LUTO	Sensitivity
Score ≥ 9.5	96%	78% (70-85)

Table 2. Staging system proposed by Ruano et al. [22]

	Stage I (mild LUTO)	Stage II (severe LUTO, with prenatal findings suggestive of preserved fetal renal function)	Stage III (severe LUTO, with prenatal findings suggestive of fetal abnormal renal function)	Stage IV (severe LUTO, with prenatal findings suggestive of fetal renal failure)
Amount of amniotic fluid	Normal	Oligohydramnios or anhydramnios	Oligohydramnios, but usually anhydramnios	Anhydramnios
Echogenicity of fetal kidneys	Normal	"echogenic"	"echogenic"	"echogenic"
Renal cortical cysts	Absent	Absent	Can be present	Present
Renal dysplasia	Absent	Absent	Can be present	Present
Fetal urinary biochemistry	Favorable	Favorable within three consecutive evaluations	Not favorable after three consecutive evaluations	Unfavourable, poor bladder re-filling after vesicocentesis
Fetal intervention	Not indicated	Indicated to prevent pulmonary hypoplasia and severe renal impairment (VAS or cystoscopy)	May be indicated to prevent pulmonary hypoplasia but not postnatal renal impairment (VAS with amnio-infusion); further studies are necessary	Not indicated/ amnio-infusion only

Table 3. Staging system proposed by Fontanella et al.[24]

LUTO Stage	Definition
Severe LUTO	Bladder volume $\geq 5.4 \text{ cm}^3$ and/or oligo- anhydramnios before 20 weeks
Moderate LUTO	Bladder volume $< 5.4 \text{ cm}^3$ and/or Normal AF at 20 weeks
Mild LUTO	Normal AF at 26 weeks

Figure 1 : Second trimester fetal ultrasound images of (a) a distended bladder and dilated posterior urethra, known as the “key-hole sign) and (b) distended bladder and bilateral hydronephrosis

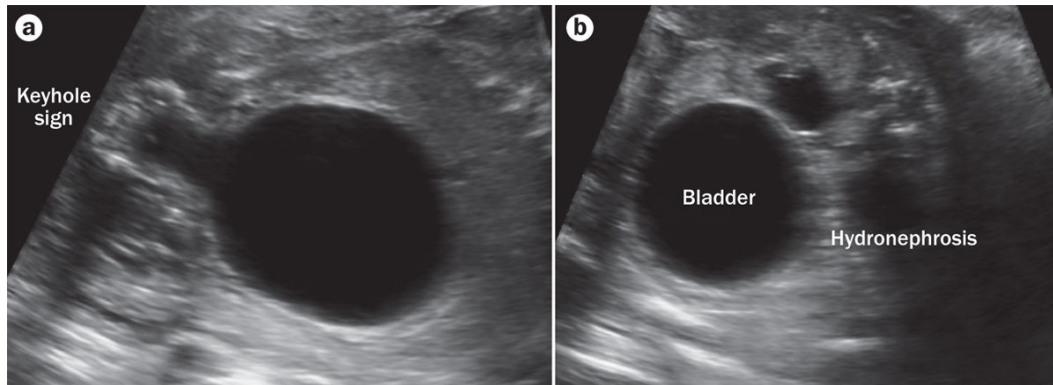


Figure 2. Fetal cystoscopy. (a) A schematic diagram of ultrasound guided percutaneous fetal cystoscopy. (b) a visualisation of the ‘bladder neck’ in fetus with congenital bladder neck obstruction. LF = laser fibre. With permission of Dr Rodrigo Ruano. Currently, a fetoscope with a 15 degree angulation is being used as an antegrade cystoscope, making it difficult to navigate the male urethra; a 60 degree angulation has been shown to allow better visualisation of the posterior urethra[33]

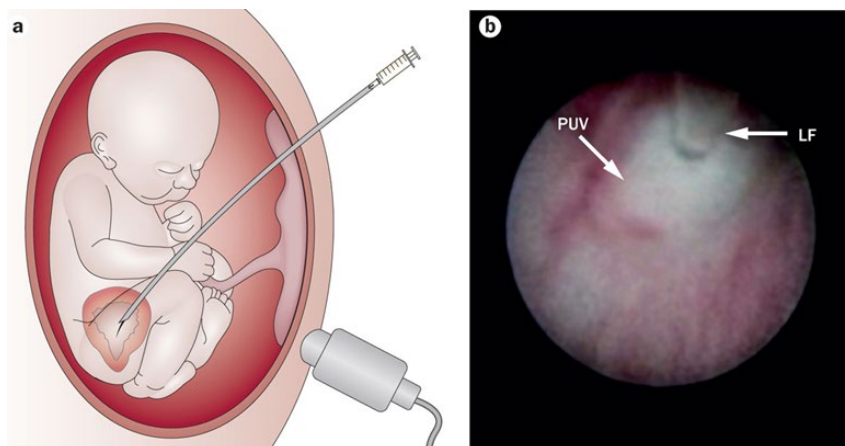


Figure 3: Ultrasound guided, percutaneous vesicoamniotic shunting (VAS) in a fetus. (a) is a schematic diagram and b) ultrasound post-VAS insertion[38].

